

Clinical image

Chagas Disease: An Important Cause of Megaesophagus in Latin America



La enfermedad de Chagas: una causa importante del megaesófago en América Latina

Edson Marchiori^{a,*}, Bruno Hochhegger^b, Gláucia Zanetti^a

^a Department of Radiology, Federal University of Rio de Janeiro, Rio de Janeiro, Brazil

^b Irmandade Santa Casa de Misericórdia de Porto Alegre, Rio Grande do Sul, Brazil

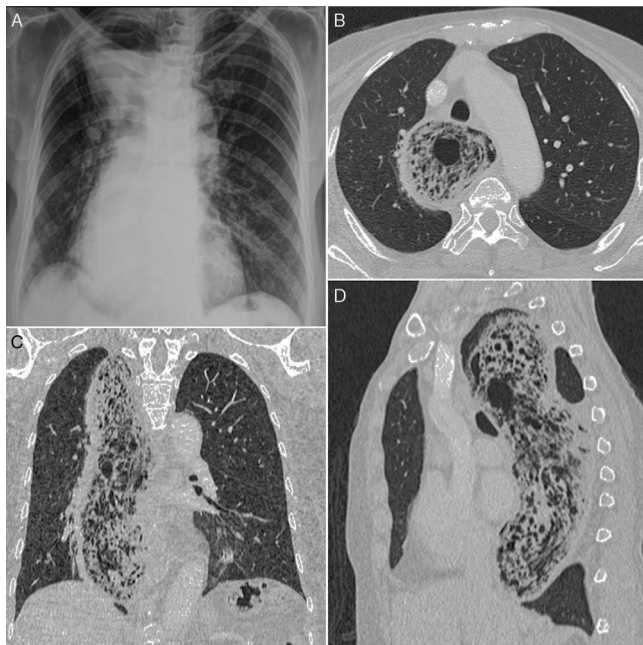


Fig. 1. A chest radiograph (A) shows mediastinal widening with an air-fluid level, compatible with megaesophagus. Axial (B), coronal (C), and sagittal (D) reformatted CT images reveal marked esophageal dilatation with residue and multiple air bubbles.

We report the case of a 75-year-old Brazilian woman who presented with weight loss, dyspnea, cough, and recurring pneumonia. She had a 15-year history of dysphagia. A chest radiograph

showed mediastinal widening with an air-fluid level, compatible with megaesophagus (Fig. 1A). Computed tomography of the thorax revealed marked esophageal dilatation, with intraluminal content interpreted as food stasis (Fig. 1B–D). A diagnosis of Chagas disease (CD) was made based on positive serological test results.

CD (American trypanosomiasis) is caused by *Trypanosoma cruzi*, a flagellated protozoan that is transmitted to humans by triatomine insects. CD is common in Latin America. It has been reported from all countries in the Americas except Canada. The chronic form of CD develops some decades after initial infection, causing irreversible damage to the heart, esophagus, and colon, with megaesophagus and megacolon.^{1,2} The esophageal manifestations of CD are very similar to those of idiopathic achalasia. The dilated esophagus is usually apparent radiographically as a shadow projecting to the right of the mediastinum. An air-fluid level may be observed in the dilated esophagus. The final diagnosis of CD in the chronic phase is based on serological tests. Surgery is currently the best form of treatment.^{1,2}

References

- Herbella FA, Aquino JL, Stefani-Nakano S, Artifon EL, Sakai P, Crema E, et al. Treatment of achalasia: lessons learned with Chagas' disease. *Dis Esophagus*. 2008;21:461–7.
- Rassi A Jr, Rassi A, Marin-Neto JA. Chagas disease. *Lancet*. 2010;375:1388–402.

* Corresponding author.

E-mail address: edmarchiori@gmail.com (E. Marchiori).