

de respuesta tras anticoagulación y la presencia de un defecto de perfusión masivo unilateral en la gammagrafía pulmonar deben hacer replantear el diagnóstico.

Las 2 pruebas no invasivas que pueden diferenciar entre trombo y masa son la RM con gadolinio y la PET-TC: en la RM, el tumor se contrasta con la inyección de gadolinio mientras que el trombo no³. A su vez, recientemente se ha comprobado que el aumento de captación de un defecto de repleción en la PET-TC con 18-fluoro-2-desoxi-D-glucosa sugiere malignidad⁴.

El diagnóstico de certeza es anatomopatológico, normalmente mediante autopsia, biopsia, o directamente en el acto quirúrgico. El diagnóstico mediante EBUS-TBNA, si bien excepcional, se ha descrito previamente con buenos resultados, proponiéndose como una técnica factible para llevar a cabo el diagnóstico diferencial entre trombo y tumor⁵. Su principal riesgo es el sangrado, especialmente en pacientes con hipertensión pulmonar, además incrementado por el aumento del tamaño de las arterias bronquiales que puede ir asociado a la obstrucción proximal de las arterias pulmonares⁶. Sin embargo, la probabilidad de sangrado se minimiza al utilizar el Doppler color sobre las imágenes ecográficas en tiempo real, puesto que así se puede evitar puncionar las áreas de flujos sanguíneos altos^{7,8}. Hasta la fecha, no se han comunicado complicaciones serias en el uso del EBUS-TBNA en este contexto⁹. Por ello, el EBUS-TBNA se está posicionando como una nueva técnica segura y mínimamente invasiva para el diagnóstico de tumores mediastínicos, incluyendo los tumores de la arteria pulmonar. El tratamiento de elección es la resección quirúrgica completa. En casos de tumor irreseccable, el pronóstico es infausto.

Bibliografía

- Murguía-Pérez M, Carrera-Gonzalez E, Cruz-Gordillo AG, Carrillo-Muñoz A, Onofre-Borja M. Leiomiomasarcoma primario pulmonar. Informe de un caso y revisión de la literatura. *Rev Esp Patol.* 2010;43:168-72.
- Pereira J, Oliver JM, Durán P, Mesa JM, Sobrino JA. Sarcoma primario de arteria pulmonar: diagnóstico mediante ecocardiograma transtorácico y transesofágico. *Rev Esp Cardiol.* 2000;53:142-4.
- Smith WS, Lesar MS, Travis WD, Lubbers P, Sen RP, Ginsberg AM, et al. RM and CT findings in pulmonary artery sarcoma. *J Comput Assist Tomogr.* 1989;13:906-9.
- Scheffel H, Stolzmann P, Plass A, Weber A, Prêtre R, Marinček B, et al. Primary intimal pulmonary artery sarcoma: A diagnostic challenge. *J Thorac Cardiovasc Surg.* 2008;135:949-50.
- Park JS, Chung J-H, Jheon S, Choi D-J, Yoon HI, Lee JH, et al. EBUS-TBNA in the differential diagnosis of pulmonary artery sarcoma and thromboembolism. *Eur Respir J.* 2011;38:1480-2.
- Montani D, Jaïs X, Sitbon O, Darteville P, Simonneau G, Humbert M. EBUS-TBNA in the differential diagnosis of pulmonary artery sarcoma and thromboembolism. *Eur Respir J.* 2012;39:1549-50.
- Shingyoji M, Ikebe D, Itakura M, Nakajima T, Itami M, Kimura H, et al. Pulmonary artery sarcoma diagnosed by endobronchial ultrasound-guided transbronchial needle aspiration. *Ann Thorac Surg.* 2013;96:e33-5.
- Modi K, Dhillon S, Kumar A, Ylagan L, Harris K. Leiomyosarcoma of the pulmonary artery diagnosed by endobronchial ultrasound-guided transbronchial needle aspiration. *Endosc Ultrasound.* 2014;3:249-51.
- Harris K, Modi K, Kumar A, Dhillon SS. Endobronchial ultrasound-guided transbronchial needle aspiration of pulmonary artery tumors: A systematic review (with video). *Endosc Ultrasound.* 2015;4:191-7.

Laura Romero Francés* y Juan Antonio Royo Prats

Servicio de Neumología, Hospital Universitario General de Castellón, Castellón de la Plana, España

* Autor para correspondencia.

Correo electrónico: lromerofrances@live.com (L. Romero Francés).

<http://dx.doi.org/10.1016/j.arbres.2017.01.019>
0300-2896/

© 2017 SEPAR. Publicado por Elsevier España, S.L.U. Todos los derechos reservados.

Enteric Adenocarcinoma Arising From a Bronchogenic Cyst



Adenocarcinoma de tipo entérico originado a partir de un quiste broncogénico

To the Editor,

Bronchogenic cysts are uncommon congenital lesions usually located in the mediastinum or lung and resulting from abnormal budding of foregut in the embryonic stage.^{1,2} Malignant transformation is very rare and only few well-documented cases have been reported.³⁻⁸ In these cases, histological findings were bronchioalveolar carcinoma, adenocarcinoma, squamous cell carcinoma and large cell carcinoma. To the best of our knowledge, this is the first case of enteric adenocarcinoma arising from an intrapulmonary bronchogenic cyst.

A 76-year-old woman with a medical history of hypertension, hypercholesterolemia, hypoacusis, glaucoma, rheumatic polymyalgia and bronchial asthma was referred to our centre for surgical resection of a bronchogenic cyst diagnosed 12 years previously in another hospital. The patient, a farmer, did not have any allergies or toxic habits. She was completely asymptomatic, and physical examination only revealed an absence of breath sounds in the posterior right lower hemithorax. All laboratory tests were normal. The computed tomography (CT) showed a 10.6 cm mass in the right lower lobe with calcified walls, which was compatible with bronchogenic cyst (Fig. 1A). The bronchoscopy showed an irregular white endobronchial mass at the entrance of

the right lower bronchus, which also affected and partially occluded the middle lobe bronchus. The histology of the endobronchial lesion was mucinous adenocarcinoma of the lung. Based on these findings, a PET-CT was performed, which showed an amebic mass with a mild increased uptake in the peripheral area and in mediastinal lymph nodes (Fig. 1B). The patient underwent functional pulmonary testing and was considered eligible for surgery. She underwent right lower lobectomy with lymph node dissection through muscle-sparing thoracotomy. The postoperative period was uneventful and the patient was discharged 6 days after surgery.

Definitive histology of the specimen was infiltrating colloid adenocarcinoma with immunophenotype of enteric adenocarcinoma arising from a benign cystic mucoid lesion compatible with bronchogenic cyst. Immunohistochemical staining was positive for cytokeratin 20 and CDX 2, and negative for cytokeratin 7 and TTF1. Mediastinal lymph nodes were not affected.

The final diagnosis was enteric adenocarcinoma arising from a bronchogenic cyst. No additional lesions were found on colonoscopy and further abdominal exams. Because no signs of disease dissemination were found, no additional therapy was applied. The patient is alive without recurrence of disease 6 months after the surgery.

Bronchogenic cysts are congenital lesions thought to originate from the primitive ventral foregut,² and are the result of abnormal budding that "pinches off" from the tracheal tree in the stage when bronchial buds develop into the primitive of respiratory tree.^{9,10} Bronchogenic cysts are relatively rare, with a prevalence of 1/68,000-1/42,000.¹¹ Almost 90% have been reported in the mediastinum, especially in the posterior superior portion.¹²

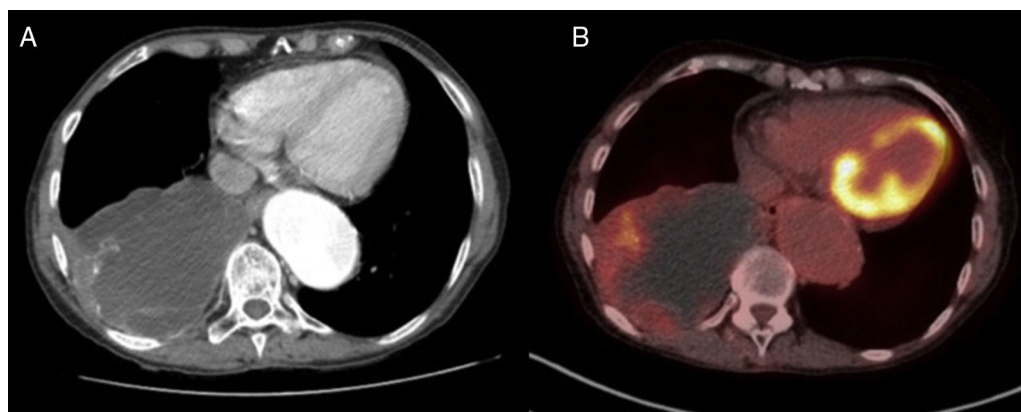


Fig. 1. Computed tomography (CT) showing a 10.6 cm mass in the right lower lobe with calcified walls, compatible with a bronchogenic cyst (A). PET-CT showing an ametabolic mass with mild increased uptake in the peripheral area (B).

Although extremely rare, malignant transformation of a bronchogenic cyst is well known and has been reported in several cases.^{3–8} In a systematic review¹³ published in 2010, the authors included 683 adult patients with a diagnosis of bronchogenic cyst; in 5 patients (0.7% of all those studied), bronchogenic cysts were associated with malignancies: 1 squamous cell, 1 adenocarcinoma, 2 bronchioalveolar carcinomas and 1 large-cell anaplastic carcinoma. It was not stated whether the indication for surgical resection was due to the detection of malignant transformation or whether malignant cells were an incidental finding, but in all cases the carcinoma was found in the cyst wall. To the best of our knowledge, this is the first case of bronchogenic cysts associated with an enteric adenocarcinoma and, in this case, malignant degeneration was the reason for surgical resection. Although there is scant evidence on carcinogenesis in a bronchogenic cyst, some studies suggests that unstable epithelial cells in the cyst wall could have malignant potential and lead to the malignant degeneration.

Surgical excision of bronchogenic cysts has historically been performed for 3 main reasons: (1) to confirm diagnosis; (2) to prevent development of symptoms and/or complications and to pre-empt the possibility of surgery on complex inflammatory lesions; and (3) to avoid any potential for malignant degeneration. However, in the reported case, no surgical treatment was requested until the malignant transformation was discovered 12 years later. Nowadays, the evidence for conservative management of asymptomatic bronchogenic cyst is very limited, and we must take into consideration that approximately 45% of patients who are asymptomatic at the moment of diagnosis will eventually develop symptoms or complications,¹³ and there is a risk of secondary tumours arising from a bronchogenic cyst.

In conclusion, we report the first case of a patient with an enteric adenocarcinoma arising from a longstanding bronchogenic cyst. We consider that surgical excision of bronchogenic cysts should be recommended even in asymptomatic patients, the aim being to preclude malignant degeneration, prevent complications or the development of symptoms, and to confirm diagnosis. Conservative management should be offered only if close long-term follow-up can be guaranteed.

References

1. St-Georges R, Deslauriers J, Duranceau A, Vaillancourt R, Deschamps C, Beauchamp G, et al. Clinical spectrum of bronchogenic cysts of the mediastinum and lung in the adult. *Ann Thorac Surg.* 1991;52:6–13.

2. Moersch HJ, Clagett OT. Pulmonary cysts. *J Thorac Surg.* 1947;16:179–99.
3. De Perrot M, Pache J-C, Spiliopoulos A. Carcinoma arising in congenital lung cysts. *Thorac Cardiovasc Surg.* 2001;49:184–5.
4. Cuypers P, De Leyn P, Capelle L, Verougstraete L, Demedts M, Deneffe G. Bronchogenic cysts: a review of 20 cases. *Eur J Cardiothorac Surg.* 1996;10:393–6.
5. Endo C, Imai T, Nakagawa H, Ebina A, Kaimori M. Bronchioalveolar carcinoma arising in a bronchogenic cyst. *Ann Thorac Surg.* 2000;69:933–5.
6. Suen H-C, Mathisen DJ, Grillo HC, LeBlanc J, McCloud T, Moncure AC, et al. Surgical management and radiological characteristics of bronchogenic cysts. *Ann Thorac Surg.* 1993;55:476–81.
7. Iwasaki T, Kawahara K, Nagano T, Nakagawa K. Pulmonary mucinous cyst adenocarcinoma: an extremely rare tumor presenting as a cystic lesion of the lung. *Gen Thorac Cardiovasc Surg.* 2007;55:143–6.
8. Ishibashi H, Moriya T, Matsuda Y, Sado T, Hoshikawa Y, Chida M, et al. Pulmonary mucinous cyst adenocarcinoma: report of a case and review of the literature. *Ann Thorac Surg.* 2003;76:1738–40.
9. Heithoff KB, Sane SM, Williams HJ, Jarvis CJ, Carter J, Kane P, et al. Bronchopulmonary foregut malformations. A unifying etiological concept. *Am J Roentgenol.* 1976;126:46–55.
10. Sumiyoshi K, Shimizu S, Enjoji M, Iwashita A, Kawakami K. Bronchogenic cyst in the abdomen. *Virchows Arch A Pathol Anat Histopathol.* 1985;408:93–8.
11. Limaïem F, Ayadi-Kaddour A, Djilani H, Kilani T, El Mezni F. Pulmonary and mediastinal bronchogenic cysts: a clinicopathologic study of 33 cases. *Lung.* 2008;186:55–61.
12. Sato M, Irisawa A, Bhutani MS, Schnadig V, Takagi T, Shibukawa G, et al. Gastric bronchogenic cyst diagnosed by endosonographically guided fine needle aspiration biopsy. *J Clin Ultrasound.* 2008;36:237–9.
13. Kirmani B, Kirmani B, Sogliani F. Should asymptomatic bronchogenic cysts in adults be treated conservatively or with surgery? *Interact Cardiovasc Thorac Surg.* 2010;11:649–59.

M^a Teresa Gómez-Hernández*, Nuria Novoa, José Luis Aranda, Marcelo F. Jiménez-López

Departamento de Cirugía Torácica, Hospital Universitario de Salamanca, Spain

* Corresponding author.

E-mail address: mteresa.gomez.hernandez@gmail.com

(M.T. Gómez-Hernández).

<http://dx.doi.org/10.1016/j.arbres.2017.02.004>

0300-2896/

© 2017 SEPAR. Published by Elsevier España, S.L.U. All rights reserved.