

Bibliografía

1. Ko SC, Chen KY, Hsueh PR, Luh KT, Yang PC. Fungal empyema thoracis: An emerging clinical entity. *Chest*. 2000;117:1672–8.
2. Lin KH, Liu YM, Lin PC, Ho CM, Chou CH, Wang JH, et al. Report of a 63-case series of *Candida* empyema thoracis: 9-year experience of two medical centers in central Taiwan. *J Microbiol Immunol Infect*. 2014;47:36–41.
3. Matsuda T, Koreeda Y, Mataka H, Taira T, Noma S, Higashimoto I. A Case of *Aspergillus* empyema successfully treated with combination therapy of voriconazole and micafungin: Excellent penetration of voriconazole and micafungin into pleural fluid. *Inter Med*. 2010;49:1163–9.
4. Walsh TJ, Anaissie EJ, Denning DW, Herbrecht R, Kontoyannis DP, Marr KA, et al. Treatment of aspergillosis: clinical practice guidelines of the Infectious Diseases Society of America. *Clin Infect Dis*. 2008;46:327–60.
5. Zaragoza R, Aguado JM, Ferrer R, Rodríguez AH, Maseda E, Llinares P, et al. EPICO 3.0. Antifungal prophylaxis in solid organ transplant recipients. *Rev Iberoam Micol*. 2016;33:187–95.

^a Servicio de Neumología, Hospital Clínico Universitario de Valladolid, Valladolid, España

^b Servicio de Microbiología, Hospital Clínico Universitario de Valladolid, Valladolid, España

^c CIBERES (Centro de Investigación en Red Enfermedades Respiratorias), Valladolid, España

* Autor para correspondencia.

Correo electrónico: blancadevegasanchez@gmail.com (B. de Vega Sánchez).

<http://dx.doi.org/10.1016/j.arbres.2017.03.025>
0300-2896/

© 2017 SEPAR. Publicado por Elsevier España, S.L.U. Todos los derechos reservados.

Blanca de Vega Sánchez^{a,*}, Irene López Ramos^b,
Raúl Ortiz de Lejarazu^b y Carlos Disdier Vicente^{a,c}

Askin's Tumor. A Rare Diagnosis in an Elderly Patient



El tumor de Askin. Un diagnóstico raro en un paciente de edad avanzada

Dear Editor:

Primitive neuroectodermal tumors (PNETs) and Ewing sarcoma are small round-cell tumors of soft tissues and bones with immunohistochemical and molecular similarities, reason why they have been categorized in the group of Ewing family tumors. PNETs can arise from primitive nerve cells of the central nervous system or outside the central nervous system, called peripheral PNETs.¹ Peripheral PNETs within the thoracopulmonary region were originally reported by Askin *et al.* in 1979,² and since then they have been defined as Askin's tumors.

We report the case of a 76-year-old Caucasian man, smoker, admitted to the emergency department with a clinical history of progressively worsening dyspnea, cough and bilateral pleuritic chest pain, asthenia and anorexia, with 6-months evolution. On physical examination, observations were normal, except increased respiratory rate. On inspection and palpation, a hard and painful mass on the right anterolateral hemithorax was detected. Laboratory investigations were normal except for a high lactate dehydrogenase (LDH 944 U/L). Chest X-ray revealed bilateral pulmonary opacities and left enlargement of the superior mediastinum. Chest computed tomography (CT) showed three pulmonary masses, one with 6.1 cm in the right inferior lobe and two in the left superior lobe (with 5.8 and 2.9 cm). The patient also had a pre-vascular solid mass with 9 cm in the superior mediastinum (Fig. 1A) and a 7.9 cm diameter lytic mass involving the anterior portion of the 7th right rib (Fig. 1B). Eco-guided transthoracic core needle biopsies of the rib lesion were performed and the

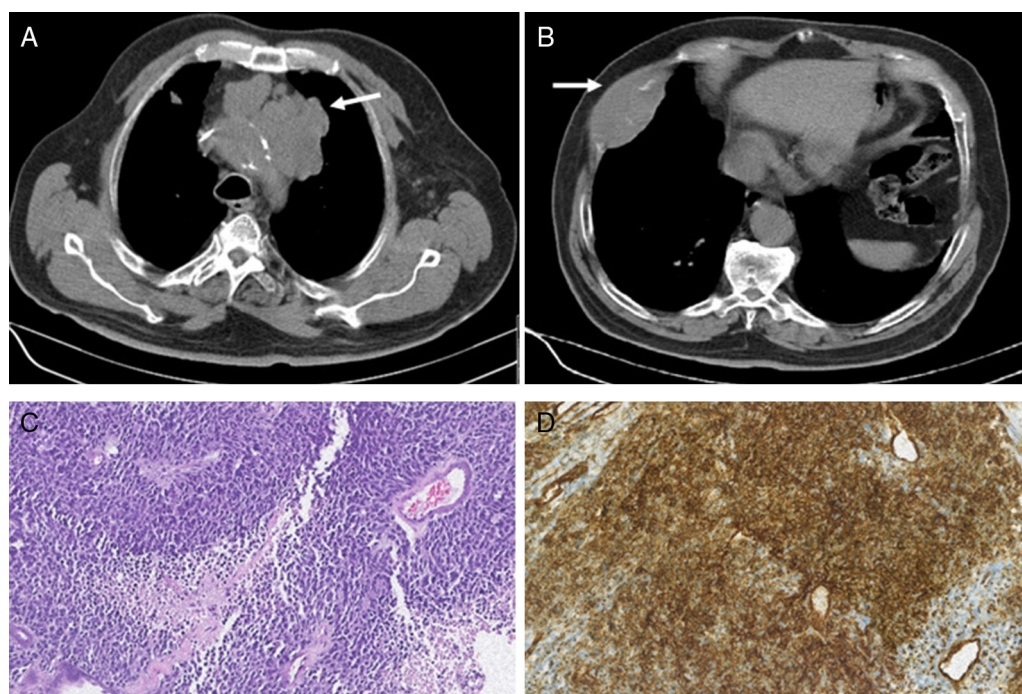


Fig. 1. (A) Chest CT showing a pre-vascular solid mass with 9 cm in the superior mediastinum (white arrow). (B) Chest CT showing a lesion in the anterior portion of the 7th right rib with 7.9 cm and bone destruction (white arrow). (C) Photomicrograph illustrating small-sized round cells with scanty cytoplasm. Stain: hematoxylin and eosin (HE); magnification: 20× (D) Immunohistochemistry photomicrograph showing tumor cells positive for CD99; magnification: 20×.

histopathological examination revealed a small-round cell tumor (Fig. 1C). The immunohistochemistry study was positive to CD99 (Fig. 1D), synaptophysin and vimentine, favoring the diagnosis of Askin's tumor.

The patient had a hospital-acquired respiratory infection with associated respiratory failure and died, without starting any anti-neoplastic therapy.

Askin's tumors are rare tumors that develops in the soft tissue of the thoracic wall and mainly occurs in children, adolescents and young Caucasian adults. Reported cases in patients over 60 years are extremely rare.¹

Our patient presented some clinical signs and symptoms commonly seen in Askin's tumors, as dyspnea, cough, chest pain, chest wall mass and anorexia. Fever and superficial lymph nodes are other clinical findings reported.^{2–4} Typical radiographic findings include a large chest mass that can be associated with pleural effusion. Rib destruction is frequent. Pulmonary parenchymal involvement, hilar and mediastinal adenopathies are other associated findings.^{2,5}

If Askin's tumor is suspected, diagnostic confirmation is obtained by histological and immunohistochemical analysis, as was performed in our case. Histological features include small round malignant cells that contain scant cytoplasm. Like the other Ewing's family tumors, Askin's tumor may express neural markers as CD99, neuron-specific enolase, vimentin and Leu7 (CD57). Tumor cells may also be positive for synaptophysin. Diagnostic confirmation can be alternatively made by detection of the typical cytogenetic mutation, a reciprocal translocation between chromosomes 11 and 22 (t[11;22](q24;q12)).⁵

The ideal treatment of Askin's tumor should be multimodal, and included a combination of neoadjuvant chemotherapy, radical surgical resection and adjuvant chemotherapy and radiotherapy,^{3,4} however, metastases are frequently seen at the time of diagnosis, making impossible the optimal treatment. Local recurrences after treatment are also frequently seen, reason why Askin's tumor is generally associated with poor prognosis and short survival.

Adverse prognostic factors reported include metastatic disease at diagnosis, larger tumor volume, presence of pleural effusion and

poor response to neoadjuvant chemotherapy.^{4,6} Some studies showed older age to be associated with poorer outcome but other studies showed no association between age and survival.⁶ Our patient presented several adverse prognostic factors, as metastatic disease and large tumor volume, and we believe that his advanced age had an important contribution to the rapidly fatal evolution after the diagnosis. Early clinical suspicion is crucial, and Askin's tumor must be kept in mind in the differential diagnosis of small round cell malignant tumors of the thorax, even in elderly.

Bibliografía

- Gedik GK, Sari O, Altinok T, Tavli L, Kaya B, Kara PO. Askin's Tumor in an adult: case report and findings on 18F-FDG PET/CT. *Case Rep Med.* 2009;2009:517329.
- Askin FB, Rosai J, Sibley RK, Dehner LP, McAlister WH. Malignant small cell tumor of the thoracopulmonary region in childhood: a distinctive clinicopathologic entity of uncertain histogenesis. *Cancer.* 1979;43:2438–51.
- Zhang KE, Lu R, Zhang P, Shen S, Li X. Askin's tumor: 11 cases and a review of the literature. *Oncol Lett.* 2016;11:253–6.
- Laskar S, Nair C, Mallik S, Bahl G, Pai S, Shet T, et al. Prognostic factors and outcome in Askin-Rosai tumor: a review of 104 patients. *Int J Radiat Oncol Biol Phys.* 2011;79:202–7.
- Murphey MD, Senchak LT, Mambalam PK, Logie CI, Klassen-Fischer MK, Kransdorf MJ. From the radiologic pathology archives, Ewing sarcoma family of tumors: radiologic-pathologic correlation. *Radiographics.* 2013;33:803–31.
- Scurr M, Judson I. How to treat the Ewing's family of sarcomas in adult patients. *Oncologist.* 2006;11:65–72.

Liliana Ribeiro^{a,*}, Dulce Apolinário^a, Joana Cunha^b,
Fernando Guimarães^b

^a Department of Pulmonology, Centro Hospitalar de Trás-os-Montes e Alto Douro, Vila Real, Portugal

^b Department of Internal Medicine, Centro Hospitalar de Trás-os-Montes e Alto Douro, Vila Real, Portugal

* Corresponding author.

E-mail address: liliana.sc.ribeiro@hotmail.com (L. Ribeiro).

<http://dx.doi.org/10.1016/j.arbres.2017.03.024>
0300-2896/

© 2017 SEPAR. Published by Elsevier España, S.L.U. All rights reserved.

Kaposi Sarcoma and Lung Transplant: Two Case Reports



Sarcoma de Kaposi y trasplante pulmonar: dos casos clínicos

Dear Editor,

Solid organ transplant recipients have an increased risk of developing malignancies, particularly lung transplant recipients, being one of the leading causes of morbidity and mortality.^{1,2} Certain viral infections are related with the development of tumours, both in immunocompetent and immunosuppressed patients.^{1,4} In the latter, the permanent state of immunosuppression, makes them more susceptible to new infections or reactivations^{1,3} such as by human herpesvirus 8 (HHV-8), which is associated with Kaposi Sarcoma (KS) and can manifest in very different ways,^{3,4} as it will be described.

The first case refers to a 63 years old male patient, former smoker, submitted to bilateral pulmonary transplant (BPT) when he was 61 years old. Eleven months after transplant, on a routine visit, two small purpuric skin lesions in the patient's chest were identified. He was referred to the Dermatology outpatient department and clinical

vigilance was decided. Five months later, due to progression of the skin lesions, (Fig. 1a), he was submitted to cutaneous biopsy whose pathology revealed morphological features and HHV-8 positive cells, compatible with KS, and its digestive tract involvement was excluded. Meanwhile, he showed functional decline and the diagnosis of bronchiolitis obliterans was made, leading to changes in his immunosuppression from mycophenolate mofetil 1250 mg bid to everolimus 0.5 mg bid. Afterwards, he presented clinical worsening with dyspnoea, bilateral pulmonary infiltrates and respiratory failure without response to non-invasive ventilation, all portrayed as a possible pulmonary involvement by KS, associated with transplant rejection (Fig. 1b). The patient died two days after these symptoms began, without having started specific therapy for KS.

The second case describes a 35 years old male patient with bronchiectasis of unknown aetiology, submitted to BPT at the age of 30. Regarding post-transplant complications, the authors emphasise acute rejection with progression to bronchiolitis obliterans with functional stability without respiratory failure. He begun immunosuppression with everolimus 0.5 mg bid and tacrolimus 4.5 mg bid. Fifty months after transplant, he was hospitalized for both prostatitis and acute cholecystitis. During that period the patient presented