

burns with no history of contact with plants can confound the diagnosis.

Apart from its therapeutic applications, *Ruta* is used widely in some countries of the Iberian peninsula and Latin America to protect against "evil spirits".^{7,8} The recommendation to apply products containing this plant all over the body, typically followed by exposure to the sun, perhaps even on the beach, gives rise to widespread lesions that only spare the areas covered by the bathing suit. Severe episodes of extensive phytophotodermatitis require a multidisciplinary approach with supportive measures in burns units.

We have presented a case of bullous phytophotodermatitis due to the use of *Ruta* in an unusual esoteric remedy against an evil-eye curse. A diagnosis of phytophotodermatitis must be suspected in patients with bullous lesions only affecting sun-exposed skin. On resolution, the lesions tend to produce well-defined residual pigmentation. It is also important to consider this diagnosis in children, in whom contact with the plant may be accidental and pass unnoticed.

Conflicts of Interest

The authors declare that they have no conflicts of interest.

References

1. Gawkrödger DJ, Savin JA. Phytophotodermatitis due to common rue (*Ruta graveolens*). *Contact Dermatitis*. 1983;9:224.
2. Morais P, Mota P, Cunha AP, Peralta L, Azevedo F. Phytophotodermatitis due to homemade ointment for *Pediculosis capitis*. *Contact Dermatitis*. 2008;59:373–4.
3. Arias-Santiago SA, Fernández-Pugnaire MA, Almazán-Fernández FM, Serrano-Falcón C, Serrano-Ortega S. Phytophotodermatitis due to *Ruta graveolens* prescribed for fibromyalgia. *Rheumatology (Oxford)*. 2009;48:1401.
4. Ortiz-Frutos J, Sánchez B, García B, Iglesias L, Sánchez-Mata D. Photocontact dermatitis from rue (*Ruta Montana* L). *Contact Dermatitis*. 1995;33:284.
5. Mill J, Wallis B, Cuttle L, Mott J, Oakley A, Kimble R. Phytophotodermatitis: Case reports of children presenting with blistering after preparing lime juice. *Burns*. 2008;34:731–3.
6. Furniss D, Adams T. Herb of grace: An unusual cause of phytophotodermatitis mimicking burn injury. *J Burn Care Res*. 2007;28:767–9.
7. Wessner D, Hofmann H, Ring J. Phytophotodermatitis due to *Ruta graveolens* applied as protection against evil spells. *Contact Dermatitis*. 1999;41:232.
8. Zayas-Pinedo, Gabilondo-Zubizarreta FJ, Torrero-López V. Foto-toxicidad tras exposición a *ruta graveolens*. *Cir Plast Iberolati-noam*. 2014;40:455–8.

S. Córdoba,* M. González, C. Martínez-Morán, J.M. Borbujo

Servicio de Dermatología, Hospital Universitario de Fuenlabrada, Fuenlabrada, Madrid, Spain

* Corresponding author.

E-mail address: susana.cordoba@salud.madrid.org

(S. Córdoba).

1578-2190/

© 2016 Elsevier España, S.L.U. and AEDV. All rights reserved.

Coma Blisters After an Overdose of Central Nervous System Depressants[☆]



Ampollas del coma tras sobredosis de fármacos depresores del sistema nervioso central

To the Editor:

The term *coma blisters* refers to a condition that occurs in patients who lose consciousness. It was first described in 1812 by Larrey¹ in soldiers with carbon monoxide poisoning. Since then, it has been mainly associated with overdose of drugs and nervous system depressants, such as barbiturates, tricyclic antidepressants, opiates and alcohol; neurological disorders, such as meningoen-cephalitis, cerebrovascular disease, and cranioencephalic trauma; and metabolic disorders, such as hyperkalemia, hypoglycemia, and diabetic ketoacidosis.^{2–4} Coma blisters, however, have also been described in patients without an altered state of consciousness, in particular in cases of long immobilization or Wegener granulomatosis.^{5–7}

We present the case of a 24-year-old woman with a history of a personality disorder and occasional consumption of cocaine and amphetamines who was found unconscious in her home. She had

taken multiple pills from her regular medication supply (topiramate, duloxetine, quetiapine, and clorazepate).

On arrival at the emergency department, she had a low level of consciousness (score 6 on the Glasgow Coma Scale), pale skin, and reactive mydriatic pupils. Partial improvement (Glasgow Coma Scale 10) was observed following physical stimulation, and the patient was treated with oxygen, fluid therapy, gastric lavage, and activated charcoal.

There was no evidence of acute intracranial lesions on the computed tomography scan. The laboratory workup showed a serum creatine kinase level of 5590 U/L and normal kidney function. The urine drug screening test showed high levels of benzodiazepines.

During her first 24 hours in hospital, the patient developed asymptomatic skin lesions located mainly on bony prominences. The physical examination showed tense clear fluid-filled blisters on well-delimited erythematous plaques (Fig. 1A,B). The lesions had an artifactual morphology and were characteristically located on pressure points (metacarpophalangeal joints on the right hand, right hip, and left knee).

The histopathologic examination showed a subepidermal blister with foci of reepithelialization (Fig. 2) and focal epithelial necrosis of eccrine coils, with periglandular infiltration of neutrophils (Fig. 3A). Additional findings included dermal, perivascular, and periadnexal infiltrates, which were predominantly neutrophilic, together with foci of fibrinoid necrosis in the walls of the small dermal capillaries and neutrophilic infiltration of the walls (Fig. 3B).

Administration of topical antibiotics led to resolution of the lesions within 3 weeks, and there were no signs of scarring or recurrence.

The clinical presentation and histopathologic findings were consistent with a diagnosis of coma blisters.

[☆] Please cite this article as: Vázquez-Osorio I, Gonzalvo-Rodríguez P, Rodríguez-Díaz E. Ampollas del coma tras sobredosis de fármacos depresores del sistema nervioso central. *Actas Dermosifiliogr*. 2017;108:81–83.

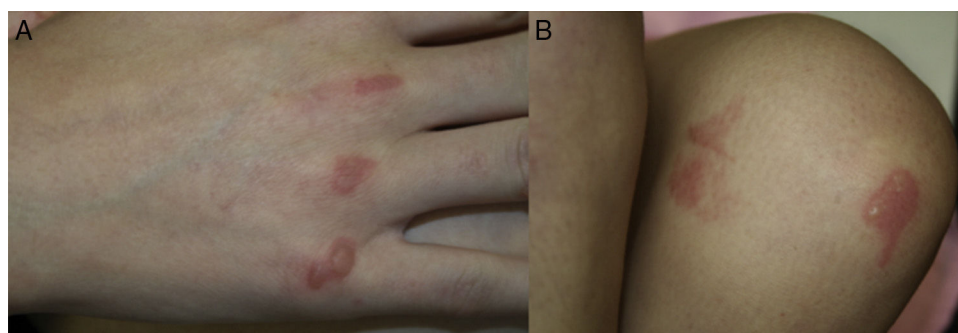


Figure 1 A, Tense clear fluid-filled blisters on well-delimited erythematous plaques on the metacarpophalangeal joints. B, Similar lesions on the left knee with an artifactual morphology.

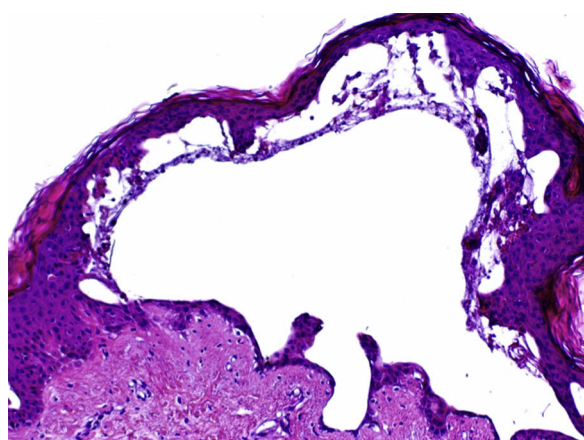


Figure 2 Subepidermal blister without inflammatory cells and with foci of reepithelialization (hematoxylin-eosin, original magnification $\times 4$).

Clinically, coma blisters are characterized by tense clear or hemorrhagic blisters that develop on erythematous-violaceous macules or plaques of varying size. The lesions typically appear within 24 hours of the intake of drugs and within 48 to 72 hours of the loss of consciousness. They primarily develop on pressure points, such as fingers and toes, elbows, knees, ankles, and heels. They are self-limiting and heal within days or weeks, without causing scarring or atrophy. The only treatment indicated thus is topical treatment to prevent secondary infections.^{2,8}

Multiple factors have been implicated in the etiology and pathogenesis of coma blisters, including local pressure or friction, generalized hypoxia and tissue ischemia, direct toxicity due to drugs excreted in sweat, immune mechanisms, and vasomotor changes in comatose states.⁹

Although a diagnosis can be established on clinical grounds only, a histopathologic study can be of great use. The main histopathologic findings are subepidermal or intraepidermal blisters and eccrine gland necrosis, mainly affecting the secretory portion. The secretory coils and ducts of the eccrine glands show a granular eosinophilic cytoplasm, ghost nuclei, and irregular membranes. However, the absence of necrosis in these glands does not necessarily rule out a diagnosis of coma blisters. Other possible findings are neutrophil exocytosis, necrosis of dermal or subcutaneous tissue or epidermal appendages, predominantly neutrophilic perivascular infiltrates, focal fibrinoid necrosis of the walls of small capillaries and arterioles, and thrombi in the lumen of dermal vascular structures.¹⁰

The vascular damage observed in drug-induced coma blisters is probably a consequence rather than a cause of the blisters. Further-

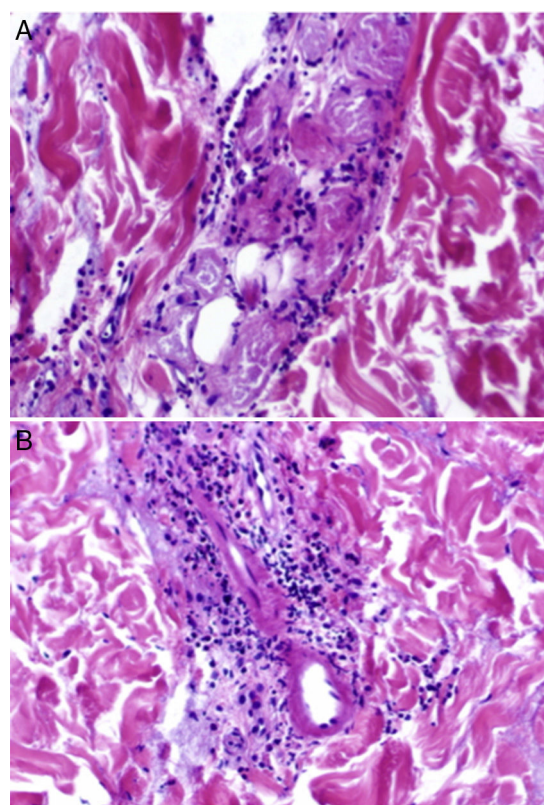


Figure 3 A, Focal epithelial necrosis in the eccrine coils with neutrophilic periglandular infiltration (hematoxylin-eosin, original magnification $\times 20$). B, Predominantly neutrophilic perivascular and periadnexal infiltrates and foci of fibrinoid necrosis in the walls of dermal capillaries, with neutrophilic infiltration of the walls (hematoxylin-eosin, original magnification $\times 20$).

more, the absence of an epidermal infiltrate and the presence of thrombi in the dermal vessels are mainly observed in coma blisters not induced by drugs.¹⁰

Direct immunofluorescence studies performed in certain cases of coma blisters have shown patched intercellular staining for immunoglobulin (Ig) G, IgA, and C3, together with IgG, IgM, and C3 deposits in dermal vessel walls and epidermal keratinocytes. These findings, however, are nonspecific and are not considered to result from an immune-mediated response.^{4,10}

In conclusion, coma blisters are a benign, self-limiting condition that should be suspected in patients who develop pressure blisters

several hours after an altered state of consciousness. Although the diagnosis is mainly clinical, correlation of clinical and pathologic findings is necessary to rule out other blistering dermatoses.

Conflicts of Interest

The authors declare that they have no conflicts of interest.

References

1. Larrey JD. "The French campaign", seventh part of "Memoires de chirurgie militaire et campagnes." (last). *Arch Hist Filoz Med.* 1999;62:233–43.
2. Bosco L, Schena D, Colato C, Biban P, Girolomoni G. Coma blisters in children: Case report and review of the literature. *J Child Neurol.* 2013;28:1677–80.
3. Mehregan DR, Daoud M, Rogers RS J3rd. Coma blisters in a patient with diabetic ketoacidosis. *J Am Acad Dermatol.* 1992;27:269–70.
4. Branco MM, Capitani EM, Cintra ML, Hyslop S, Carvalho AC, Bucarechi F. Coma blisters after poisoning caused by central nervous system depressants: Case report including histopathological findings. *An Bras Dermatol.* 2012;87:615–7.
5. Ferreli C, Sulica VI, Aste N, Atzori L, Pinna M, Biggio P. Drug-induced sweat gland necrosis in a non-comatose patient: A case presentation. *J Eur Acad Dermatol Venereol.* 2003;17:443–5.
6. Piede J, Wallace E. Coma bullae: Associations beyond medications. *Mayo Clin Proc.* 2011;86:e5.
7. Heinisch S, Loosemore M, Cusack CA, Allen HB. Coma blisters sans coma. *Cutis.* 2012;90:137–9.
8. Rocha J, Pereira T, Ventura F, Pardal F, Brito C. Coma blisters. *Case Rep Dermatol.* 2009;1:66–70.
9. Chacon AH, Farooq U, Choudhary S, Yin N, Nolan B, Shiman M, et al. Coma blisters in two postoperative patients. *Am J Dermatopathol.* 2013;35:381–4.
10. Sánchez-Yus E, Requena L, Simón P, Hospital M. Histopathology of cutaneous changes in drug-induced coma. *Am J Dermatopathol.* 1993;15:208–16.

I. Vázquez-Osorio,^{a,*} P. Gonzalvo-Rodríguez,^b
E. Rodríguez-Díaz^a

^a *Servicio de Dermatología, Hospital Universitario de Cabueñes, Gijón, Asturias, Spain*

^b *Servicio de Anatomía Patológica, Hospital Universitario de Cabueñes, Gijón, Asturias, Spain*

* Corresponding author.

E-mail address: rogivaos@gmail.com (I. Vázquez-Osorio).

1578-2190/

© 2016 Elsevier España, S.L.U. and AEDV. All rights reserved.