




ACTAS Derma-Sifiliográficas

Full English text available at
www.actasdermo.org



IMAGES IN DERMATOLOGY

A Scar or a Tumor?☆

¿Cicatriz o tumor?

A. Pérez-Plaza,* G. Solano-López, E. Vargas



Servicio de Dermatología, Hospital Universitario de La Princesa, Madrid, Spain

The patient, a 79-year-old woman, consulted for a linear pruritic lesion measuring 50 × 5 mm that had arisen some months earlier in her left cervical region. The patient denied any history of trauma. Dermoscopy revealed ovoid blue-gray nests, maple leaf-like areas, and ulceration. Biopsy was compatible with superficial basal cell carcinoma (BCC) and, given the clinical presentation, the final diagnosis was linear BCC. The first case of this morphological variant of BCC was published in 1985. From a clinical point

of view, it appears as a predominantly linear lesion, with greater length than width. Several hypotheses have been proposed to explain this clinical appearance of BCC: possible interactions of the stroma with Langer lines, a Koebner phenomenon after recurrent trauma, or limitation of the lesion by underlying dermal fibrosis. From a diagnostic point of view, the scar-like appearance of the lesion means that dermoscopy can help to orient the diagnosis (Figure 1).

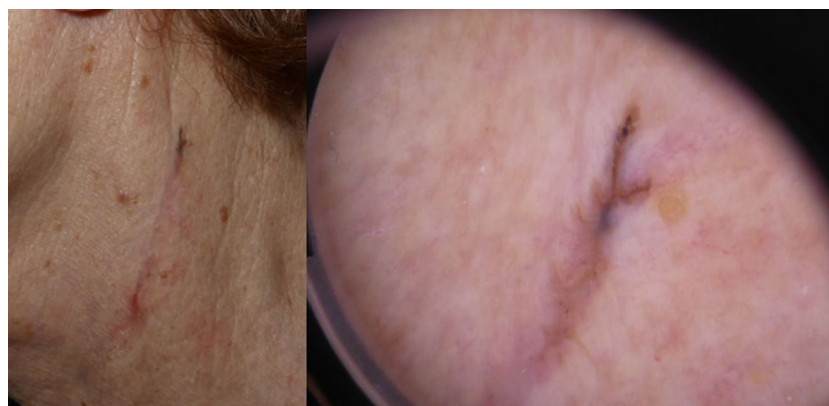


Figure 1

☆ Please cite this article as: Pérez-Plaza A, Solano-López G, Vargas E. ¿Cicatriz o tumor?. Actas Dermosifiliogr. 2017;108:158.

* Corresponding author.

E-mail address: aperezplaza@gmail.com (A. Pérez-Plaza).