




# ACTAS Derma-Sifiliográficas

Full English text available at  
[www.actasdermo.org](http://www.actasdermo.org)



## ORIGINAL ARTICLE

# Treatment of nail psoriasis with Pulse Dye Laser plus calcipotriol betametasona gel vs. Nd:YAG plus calcipotriol betamethasone gel: An inpatient left-to-right controlled study



L.C. Arango-Duque<sup>a,\*</sup>, M. Roncero-Riesco<sup>b</sup>, T. Usero Bárcena<sup>c</sup>,  
I. Palacios Álvarez<sup>d</sup>, E. Fernández López<sup>b</sup>

<sup>a</sup> Servicio de Dermatología, Complejo Asistencial Universitario de Palencia, Spain

<sup>b</sup> Servicio de Dermatología, Hospital clínico universitario de Salamanca, Salamanca, Spain

<sup>c</sup> Servicio de Dermatología, Hospital de Cabueñes, Gijón, Spain

<sup>d</sup> Servicio de Dermatología, Hospital San Pedro, Logroño, Spain

Received 6 April 2016; accepted 16 September 2016

### KEYWORDS

Nail psoriasis;  
Laser treatment;  
Nd:YAG;  
Pulse Dye Laser

### Abstract

**Background:** Treatment of nail psoriasis remains a challenging and often disappointing situation.

**Objective:** To compare the efficacy, adverse reactions and tolerability of treatment of nail psoriasis with PDL vs. Nd:YAG, in association with betametasona calcipotriol gel.

**Methods:** An open, prospective inpatient left-to-right study was designed. The right hand of each patient received treatment with PDL and the left hand with Nd:YAG. Betamethasone calcipotriol gel was applied once a day during the first week after each laser session. A total of four sessions were administered.

**Results:** The clinical efficacy was evaluated according to the NAPSI score.

All patients showed improvement in nail bed and nail matrix psoriasis. The global NAPSI mean declined in 15.46 ( $p < 0.000$ ). There was neither statistical difference between the reduction in nail bed and matrix NAPSI nor in the treatment with PDL vs. Nd:YAG. The administration of Nd:YAG was more painful. No serious adverse effects were documented.

**Limitations:** No random assignment and the small number of patients.

**Conclusions:** PDL and Nd:YAG have proven to be an effective treatment for nail psoriasis with no serious adverse effect. No statistically significant difference was found between the two treatments.

© 2016 Published by Elsevier España, S.L.U. on behalf of AEDV.

\* Corresponding author.

E-mail address: [lauraarango9@hotmail.com](mailto:lauraarango9@hotmail.com) (L.C. Arango-Duque).

**PALABRAS CLAVE**

Psoriasis ungueal;  
Láser, Nd:YAG;  
Láser de colorante  
pulsado

## Tratamiento de psoriasis ungueal con Pulse dye laser frente a Nd: YAG, en asociación con gel de betametasona: un estudio con control intrapaciente izquierda-derecha

**Resumen**

**Antecedentes:** El tratamiento de la psoriasis ungueal es una situación de difícil manejo y a menudo decepcionante para el dermatólogo.

**Objetivo:** Comparar la eficacia, las reacciones adversas y la tolerabilidad del tratamiento de la psoriasis ungueal con PDL vs. Nd: YAG en asociación con gel de betametasona calcipotriol.

**Métodos:** Estudio prospectivo abierto con control intrapaciente izquierda-derecha. La mano derecha de cada paciente recibió tratamiento con PDL y la mano izquierda con Nd: YAG. Se aplicó gel de betametasona calcipotriol una vez al día durante la primera semana después de cada sesión de láser en las 2 manos. Se administraron un total de 4 sesiones.

**Resultados:** La eficacia clínica se evaluó de acuerdo con la escala NAPSI. Todos los pacientes mostraron una mejoría en las lesiones del lecho y de la matriz ungueal. La media global del NAPSI disminuyó en 15,46 ( $p < 0,000$ ). No hubo diferencia significativa entre la mejoría de las lesiones del lecho y la matriz ni en el tratamiento con el PDL vs. Nd: YAG. La administración de Nd: YAG fue más dolorosa. No se documentaron efectos adversos graves.

**Limitaciones:** Falta de asignación aleatoria y muestra pequeña.

**Conclusiones:** PDL y Nd: YAG han demostrado ser tratamientos eficaces para la psoriasis ungueal sin documentarse efectos adversos graves. No se encontró diferencia estadística significativa entre los 2 tratamientos.

© 2016 Publicado por Elsevier España, S.L.U. en nombre de AEDV.

**Introduction**

Even though cutaneous signs and symptoms are the most common clinical manifestations of psoriasis, the nails can be involved in up to 78% of patients, reaching 95% if psoriatic arthritis is present.<sup>1</sup> The longer the psoriatic lesions exist, the higher the frequency of nail changes will be. Furthermore, in a study involving 1728 patients with nail psoriasis 93.3% indicated that nail changes were cosmetically disturbing, 58.9%, reported restriction in their daily activities, and 51.8% referred pain.<sup>1</sup>

The clinical presentation has a wide spectrum of changes depending on the location of the pathology. Pitting, leukonychia, red spots in the lunula, nail plate crumbling, Beau lines, and trachyonychia are signs of nail matrix involvement. On the other hand, onycholysis, oil drop discoloration (salmon patch), subungual hyperkeratosis, and splinter hemorrhage indicate nail bed involvement.<sup>2,3</sup> This differentiation is convenient because nail matrix psoriasis is expected to be more resistant to different therapeutic approaches.

Traditional therapies have focused on the inhibition of epidermal proliferation, inflammation, or both. However, it has recently been pointed out that the earliest changes noted in a new psoriatic lesion arise in the superficial dermal microvasculature<sup>4</sup> and that these are necessary for maintaining clinical lesions. Because the psoriatic blood vessels play such an important role, acting on the abnormal psoriatic vasculature may be beneficial in psoriasis.

**Material and methods**

We conducted a prospective intra-patient left-to-right controlled study. Patients with bilateral fingernail psoriasis were enrolled. The patients could have undergone prior topical

or systemic treatment or be naive. Exclusion criteria were onychomycosis, concomitant treatment with drugs affecting the nail, use of permanent manicures, subungual hematoma, subungual nevus and history of trauma.

Signed consent forms were obtained from each patient before entering the study.

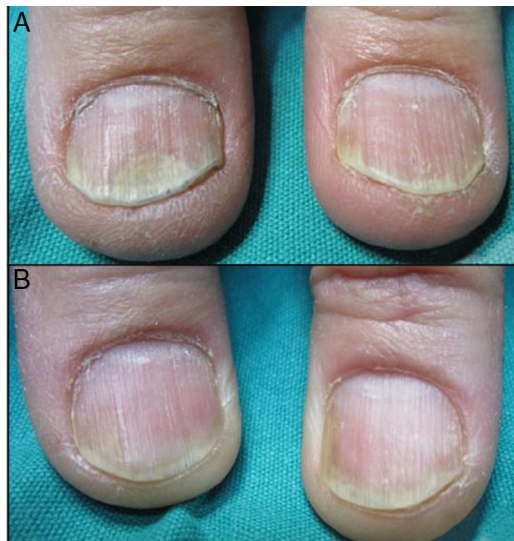The initial evaluation included a complete medical history, physical examination, Nail Psoriasis Severity Index (NAPSI) score, and digital photographs. During every visit the NAPSI score and the digital photographs were updated and the patients were asked to identify their nail improvement and evaluate pain in both hands on a visual analog scale from 0 to 10 (patient global assessment: 0: no change; no pain, 10: total clearance, extremely painful). At the end of the sessions, the patient's satisfaction was evaluated with a visual analog scale, (0: not satisfy at all, not effective 10: very satisfy, very effective).

The right hand of each patient received treatment with Pulse Dye Laser (PDL) with a pulse duration of 0.4 ms, an energy of 6 J/cm<sup>2</sup> and a beam diameter of 7 mm, Whereas the left hand was treated with Nd:YAG with a beam diameter of 5 mm, pulse duration of 35 ms and an energy of 40 J/cm<sup>2</sup>. All the nail plates, including the lunula, were treated with contiguous layers of spots with a 30% overlapping. The patient was instructed to apply betamethasone calcipotriol gel every 24 h for a week in both sides.

A premedication involving paracetamol was given one hour before the session if requested by the patient. Treatment sessions were repeated every month for a total of four sessions.

**Results**

Thirteen patients (seven women, six men) were enrolled in the study. Two patients left the study at session 2 and 3

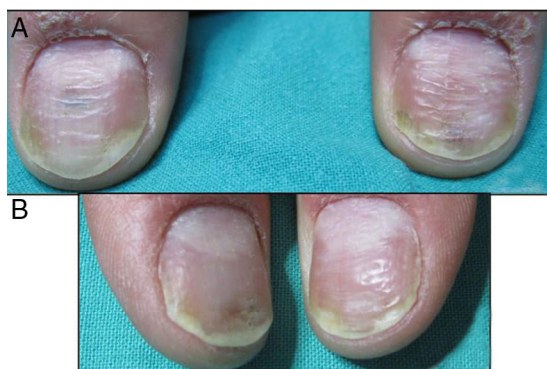

**Figure 1** (A) Bilateral Distal onycholysis before treatment. The right thumbnail was treated with PDL while the left thumbnail with Nd:YAG. (B) After four sessions of PDL (right thumbnail) and four sessions of Nd:YAG (left thumbnail).

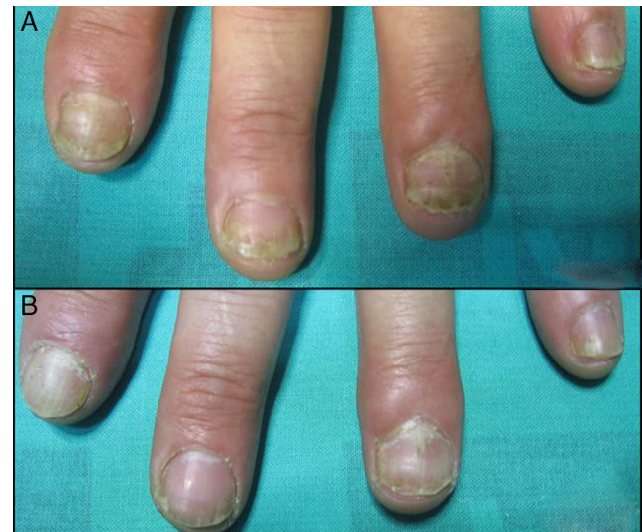respectively, none of them due to adverse reactions. The mean age was  $48 \pm 15$  years and the majority had occupations that required regular use of the hands. Twenty three per cent of the patients (3 patients) had exclusive nail involvement, 31% (4 patients) associated psoriatic arthritis and 38% have not received previous treatment. None of those that have been treated before with topical (corticosteroids, calcipotriol, retinoids, or a combination of these) or systemic therapy (acitretin, methotrexate) have showed previous improvement of their nail involvement.

Clinical efficacy was evaluated statistically according to global NAPSI score, nail bed NAPSI score (onycholysis, nail bed hyperkeratosis, oil drop discoloration, splinter, hemorrhage) and nail matrix NAPSI score (pitting, leukonychia, red spots in lunula, nail plate crumbling).

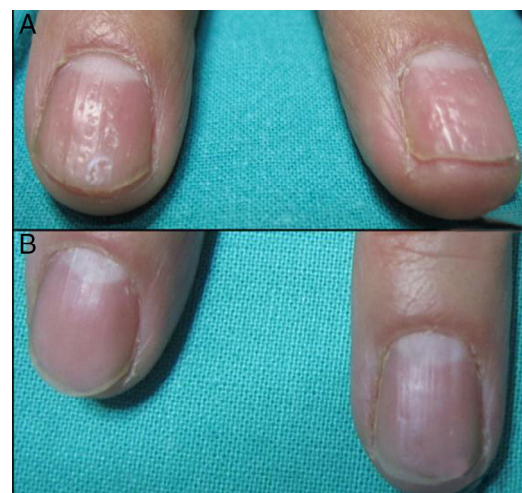All patients experience improvement in the global, matrix and nail bed NAPSI score (Figs. 1–4). The pre-treatment global NAPSI mean was  $34.85 \pm 13.898$  and the post-treatment was  $19.38 \pm 12.48$  with a diminution of the



**Figure 2** (A) Matrix and bed nail psoriasis before treatment. (B) After four sessions of PDL (right thumbnail) and four sessions of Nd:YAG (left thumbnail).



**Figure 3** (A) Distal onycholysis, subungueal hyperkeratosis and distal oil drop of nail plate psoriasis of the left hand before the treatment. (B) After four sessions of Nd:YAG.



**Figure 4** (A) Nail matrix psoriasis of the right hand before treatment. (B) After four sessions of PDL.

global mean of  $15.46$  ( $p < 0.000$ ) (Table 1). Unlike other studies, we did not find a significant difference between the drop in the matrix and the nail bed NAPSI score mean.

The left hand treated with Nd:YAG diminished in  $8.54$  points versus the right hand with PDL  $6.93$  with no statistical significant difference. The visual analog scale ranging from 0 to 10 to evaluated the pain demonstrated that the treatment with Nd:YAG was more painful than the PDL with a mean of  $5.4 \pm 3.3$  compared to  $2.9 \pm 1.8$ . The 84% of the patients showed an improvement in the symptomatology. Compared to other therapies, the visual analog scale, which evaluated patient's satisfaction with laser treatment showed a high preference for the former with a mean of  $8.4 \pm 1.2$  for the laser treatment compared to  $1.5 \pm 0.5$  of other therapeutics approaches Only transient petechiae were documented. No other adverse effects were observed.

**Table 1** Comparison of the NAPSI score before and after the treatment of nail psoriasis with PDL (right hand) and Nd:YAG (left hand).

NAPSI	Pretreatment (mean, SD)	Posttreatment (mean, SD)	Difference in mean	p Value
Global	34.85 ± 13.89	19.38 ± 12.48	15.46	<0.001
PDL	16.77 ± 8.54	9.85 ± 6.29	6.93	<0.001
Nd:YAG	18.08 ± 5.70	9.54 ± 6.41	8.54	<0.001
Matrix	21.46 ± 13.43	11.77 ± 11.01	9.68	<0.001
Nail bed	13.38 ± 9.42	7.69 ± 6.56	5.69	<0.001

## Discussion

Laser therapy has proved to be a safe and effective therapy for nail plate psoriasis. Our study suggests that its use, alone or in combination with other therapeutic modalities, can help to improve this resistant form of psoriasis.

Many studies have already shown the efficacy of PDL in the treatment of plaque type psoriasis, which exhibits the characteristics of angiogenesis and increased vascularity. Besides destruction of blood vessels, PDL can reduce the number of helper T cells in the dermis, eliminate the extravasation of inflammatory mediators into the interstitium and normalize epidermal proliferation, which improves the clinical signs of psoriasis vulgaris.<sup>2,4</sup>

In 2009, Fernandez-Guarino et al. studied the efficacy of PDL in nail psoriasis treatment, revealing excellent results, with 33% improvement after 12 weeks of treatment and 58% improvement after 24 weeks of treatment.<sup>2</sup>

In some studies the clinical improvement was more prominent in the nail bed lesions, particularly onycholysis and subungual hyperkeratosis.<sup>5</sup> In our study, however this difference was not statistically significant. This could possibly be justified because this improvement will appear later as the nail plate grows, so a follow up over several months is necessary to perceive these changes.

To our knowledge there are not studies that have either evaluated the efficacy of Nd:YAG for the treatment of nail psoriasis or compared its efficacy to PDL.

One could see how treatment of deeper vessels in psoriatic lesions could improve the results of laser therapy. This could be achieved by using Nd:YAG which has the ability to penetrate deeper into the dermis. We find a slight difference that privileges Nd:YAG but the results were not statistically significant. Besides, the treatment with Nd:YAG was more painful, therefore its use does not appear to be justified if the PDL is available.

Due to the fact that the optimum parameters for PDL and Nd:YAG for treatment of psoriasis and nail psoriasis, have not been clarified, parameters in our study were, to some extent, compatible with the parameters of previous studies.<sup>2,4-6</sup>

It is known that the combination of laser and topical treatment can enhance the positive results of the therapy.<sup>4</sup> Therefore, we used a coadjuvant treatment with betamethasone calcipotriol gel to improve the outcome. Patients who were neither naïve or have not responded to previous or concurrent topical or systemic therapy were enrolled. We found improvement in both groups, even in those who were refractory to systemic therapy. These results suggest the benefits of this therapy alone, especially for

those patients who have an exclusive nail involvement or as a coadjuvant treatment to other therapeutic modalities for those with more widespread disease.

Patient's satisfaction was higher than that demonstrated with other therapeutical modalities. The resolution of the symptomatology was documented in the majority of the participants. No differences in this matter were observed when the two types of laser were compared. No serious adverse effects were noticed. A long follow up is necessary in order to decide whether further sessions of laser are needed to maintain the response for a long period of time.

The main limitation of this study is the low sample size, not previously calculated.

In conclusion, laser therapy has showed to be effective and safe for nail plate psoriasis with high patient's satisfaction. It could be used alone or combined with different therapeutic modalities, being especially beneficial with topical treatments. Nd:YAG did not seem to add any benefit to the use of PDL. Even though clinical trials are needed to establish a protocol, the present study can guide clinicians to introduce this therapy for all kinds of nail psoriasis.

## Ethical responsibilities

**Protection of people and animals.** The authors state that the procedures conformed to the ethical standards of human experimentation committee responsible and according to the World Medical Association and the Declaration of Helsinki.

**Confidentiality of data.** The authors declare that this article does not appear patient data.

**Right to privacy and informed consent.** The authors have obtained the informed consent of patients and/or subjects referred to in Article consent. This document is held by the corresponding author.

## Conflict of interest

Mónica Roncero has received funding for attendance to the AEDV Conference in 2014 following the completion of the study.

## References

- De Jong EM, Seegers BA, Gulink MK, Boezeman JB, van de Kerkhof PC. Psoriasis of the nails associated with disability in

- a large number of patients: results of a recent interview with 1728 patients. *Dermatology*. 1996;193:300–3.
2. Treewittayapoom C, Singvahanont P, Chanprapaph K, Haneke E. The effect of different pulse durations in the treatment of nail psoriasis with 595-nm pulsed dye laser: a randomized, double-blind, inpatient left-to-right study. *J Am Acad Dermatol*. 2012;66:807–12.
  3. Jiaravuthisan MM, Sasseville D, Vender RB, Murphy F, Muhn CY. Psoriasis of the nail: anatomy, pathology, clinical presentation, and a review of the literature on therapy. *J Am Acad Dermatol*. 2007;57:1–27.
  4. de Leeuw J, Tank B, Bjerring PJ, Koetsveld S, Neumann M. Concomitant treatment of psoriasis of the hands and feet with pulsed dye laser and topical calcipotriol, salicylic acid, or both: a prospective open study in 41 patients. *J Am Acad Dermatol*. 2006;54:266–71.
  5. Oram Y, Karıncaog Lu Y, Koyuncu E, Kaharamanz F. Pulsed dye laser in the treatment of nail psoriasis. *Dermatol Surg*. 2010;36:377–81.
  6. Huang Y-C, Chou C-L, Chiang Y-Y. Efficacy of pulsed dye laser plus topical tazarotene versus topical tazarotene alone in psoriatic nail disease: a single-blind, inpatient left-to-right controlled study. *Lasers Surg Med*. 2013;45:102–7.