

Response to Professor Wiwanitkit's Comment on "Zika Virus Disease: Should We Be Worried?"



Respuesta al comentario del profesor Wiwanitkit sobre "Enfermedad por el virus de Zika ¿debe preocuparnos?"

Dear Editor,

The view expressed in this letter is that the answer to question posed by the editorial is "Yes, we should worry, but about what?" Dr Wiwanitkit's main concern is rapid and accurate diagnosis. First, because many asymptomatic cases may go undetected, leading to further spread of the disease, and second because the long-term complications may be a problem.

The answer to the editorial question was implicitly yes. Three main concerns were established¹: (1) Zika disease control (including case detection) in countries with local transmission; (2) detection of cases in Spain; and (3) vector monitoring and control in Spain. I do not think that undiagnosed asymptomatic cases are a main concern in our environment. If we are able to diagnose symptomatic

cases, we can determine the extent of the disease, based on our knowledge about the proportion of subclinical cases. Suboptimal diagnosis is part of the more general health infrastructure problem affecting countries with a higher prevalence of Zika. Finally, it is true that we do not know whether long-term complications can affect patients with subclinical infection. As many aspects of the pathogenesis remain unclear and an association with neurological sequelae has been demonstrated, epidemiological studies that address these problems are clearly needed.² This does not, however, change our three main concerns.

References

1. Alonso JP. Enfermedad por el virus de Zika ¿debe preocuparnos? *Actas Dermosifiliogr.* 2016;107:625–6.
2. Plourde AR, Bloch EM. A literature review of Zika virus. *Emerg Infect Dis.* 2016;22:1185–92.

J.P. Alonso

Departamento de Sanidad, Dirección General de Salud Pública, Zaragoza, Spain

E-mail address: jpalonso@aragon.es

1578-2190/

© 2016 Elsevier España, S.L.U. and AEDV. All rights reserved.

Comment on "Distant Cutaneous Metastases of Prostate Cancer: A Report of 2 Cases"☆



Comentario a «Metástasis cutáneas a distancia de cáncer de próstata: 2 casos»

To the Editor:

We read with interest the article entitled "Distant cutaneous metastases of prostate cancer: a report of 2 cases"¹ in which an exhaustive immunohistochemical study left no doubt about the diagnosis. These cases remind us of usefulness of avian erythroblastosis virus E26 oncogene homolog (ERG) in the cutaneous diagnosis of prostate cancer metastasis.

ERG is a member of the erythroblast transformation-specific family of transcription factors. It is expressed in normal and neoplastic endothelial cells of blood and lymph vessels and is a highly specific marker of vascular endothelium. ERG is very useful in the diagnosis of angiosarcomas, hemangioendotheliomas, and Kaposi's sarcoma.

However, it is also positive in the following cell types: 1) neoplastic epithelial cells of 50% of primary and metastatic prostate carcinomas (Figure 1), but not in normal prostate tissue; 2) immature myeloid cells in bone marrow; 3) chronic myeloid leukemia cells; and 4) Ewing sarcoma cells.² The fact that it is positive in prostate carcinoma but negative in almost all other carcinomas makes ERG a very valuable in immunohistochemical panels used to investigate cutaneous metastases of unknown origin.³

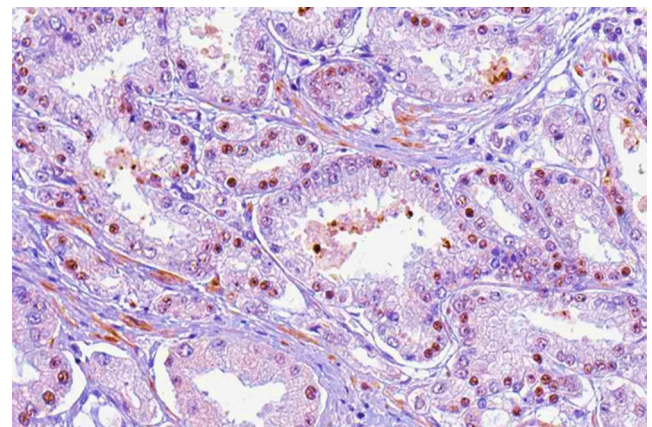


Figure 1 Subcutaneous nodule in right paravertebral back (ERG × 200, nuclear staining).

☆ Please cite this article as: Santos-Juanes J, Fernández-Vega I, Vivanco B. Comentario a «Metástasis cutáneas a distancia de cáncer de próstata: 2 casos». *Actas Dermosifiliogr.* 2017;108:174–175.