




ACTAS Derma-Sifiliográficas

Full English text available at
www.actasdermo.org



IMAGES IN DERMATOLOGY

Long-standing Erythematous Plaque in a Perianal Skin Fold[☆]



Placa eritematosa en pliegue perianal de años de evolución

I. Pérez-López,^{*} G. Blasco-Morente, A. Martínez-López, S. Arias-Santiago

Unidad de Gestión Clínica de Dermatología Médico-Quirúrgica y Venereología, Hospital Universitario Virgen de las Nieves, Granada, Spain

The patient was an 80-year old man. His relevant past history included long-standing rheumatoid arthritis treated with methotrexate. He consulted for a pruritic lesion that had arisen 2 years earlier in the intergluteal fold and that had deteriorated in the previous months. The lesion had been treated with intermittent courses of topical and oral corticosteroids, with no improvement. Physical examination revealed an infiltrated lichenified erythematous plaque that affected the whole of the intergluteal fold (Fig. 1). Skin biopsy was reported as leishmaniasis. With this diagnosis, and after excluding systemic involvement, treatment was started with intralesional meglumine antimonate (Glucantime), 2.5 mL, with dose reduction as lesion size decreased. After 8 weekly injections, the patient was asymptomatic. Polymerase chain reaction on a new biopsy was negative for *Leishmania*, guaranteeing resolution of the condition.

Leishmaniasis is a group of diseases caused by protozoa of the genus *Leishmania*. It is transmitted to humans by the bite of female mosquitoes of the genus *Phlebotomus*. Clinical

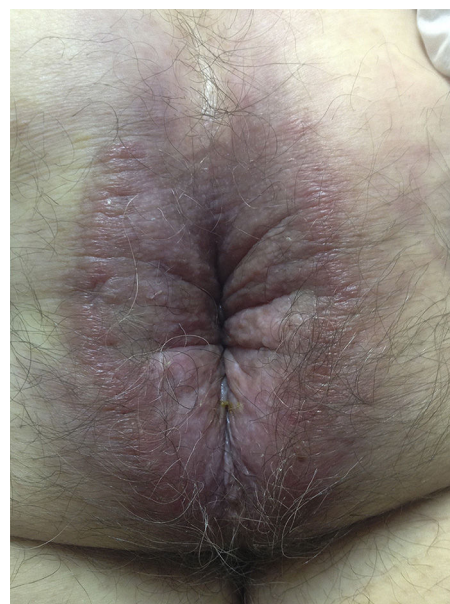


Figure 1

[☆] Please cite this article as: Pérez-López I, Blasco-Morente G, Martínez-López A, Arias-Santiago S. Placa eritematosa en pliegue perianal de años de evolución. Actas Dermosifiliogr. 2017;108:473.

^{*} Corresponding author.

E-mail address: ipl.elmadrono@hotmail.com (I. Pérez-López).

presentation is very variable, from cutaneous forms with a single lesion (*oriental sore*), to visceral systemic forms and kala-azar. The prognosis and treatment depend on the form of presentation.