

the studied cases, as in other histiocytic disorders such as juvenile xanthogranuloma.

The prognosis of CRDD is generally favorable^{2,4} and many cases resolve spontaneously.⁷ Numerous treatments—including topical and systemic corticosteroids, thalidomide, dapsone, retinoids, cryotherapy, and radiation therapy³—have been used, all with variable efficacy. In refractory cases, vincristine⁹ and imatinib¹⁰ have shown very good results. A recent case was treated with low-dose methotrexate, with good response.⁴ Surgical removal can be justified in localized cases.

We present a new case of facial CRDD; it is important to consider this entity in the differential diagnosis of facial lesions with a granulomatous appearance in order to avoid diagnostic delays, so that treatment can be started if necessary.

Conflicts of Interest

The authors declare that they have no conflicts of interest.

Acknowledgments

The authors would like to thank Dr. Santiago Montes and the team of Dr. M.A. Piris from Hospital Universitario Marqués de Valdecilla (Santander) for their collaboration on the diagnosis.

References

- Dalia S, Sagatys E, Sokol L, Kubal T. Rosai-Dorfman disease: Tumor biology, clinical features, pathology, and treatment. *Cancer Control*. 2014;21:322–7.
- Ma H, Zheng Y, Zhu G, Wu J, Lu C, Lai W. Rosai-Dorfman disease with massive cutaneous nodule on the shoulder and back. *Ann Dermatol*. 2015;27:71–5.
- Fang S, Chen AJ. Facial cutaneous Rosai-Dorfman disease: A case report and literature review. *Exp Ther Med*. 2015;9:1389–92.
- Sun NZ, Galvin J, Cooper KD. Cutaneous Rosai-Dorfman disease successfully treated with low-dose methotrexate. *JAMA Dermatol*. 2014;150:787–8.
- Emile JF, Ablu O, Fraitag S, Horne A, Haroche J, Donadieu J, et al., Histiocyte Society. Revised classification of histiocytoses and neoplasms of the macrophage-dendritic cell lineages. *Blood*. 2016;127:2672–81.
- De Pasquale R, Longo V, Pavone A, Scuderi L. Cutaneous Rosai-Dorfman disease. *G Ital Dermatol Venereol*. 2016;151:302–65.
- Kaskas NM, Kern M, Johnson A, Hughes MP, Hardee M, Day J, et al. A case of cutaneous Rosai-Dorfman disease with underlying calvarial involvement and absence of BRAFV600E mutation. *JAAD Case Rep*. 2015;1:408–11.
- Frater JL, Maddox JS, Obadiah JM, Hurley MY. Cutaneous Rosai-Dorfman disease: Comprehensive review of cases reported in the medical literature since 1990 and presentation of an illustrative case. *J Cutan Med Surg*. 2006;10:281–90.
- Liu P, Wang P, Du J, Zhang J. Successful treatment of refractory cutaneous Rosai-Dorfman disease with vincristine. *J Dermatol*. 2015;42:97–8.
- Nebe T, Hildenbrand R, Habenkorn U, Goerdts S, Schadendorf D. Imatinib as a treatment option for systemic non-Langerhans cell histiocytoses. *Arch Dermatol*. 2007;143:736–40.

M.Á. Flores-Terry,^{a,*} G. Romero-Aguilera,^a
L. González-López,^b M. García-Arpa^a

^a Servicio de Dermatología, Hospital General Universitario de Ciudad Real, Ciudad Real, Spain

^b Servicio de Dermatología y Servicio de Anatomía Patológica, Hospital General Universitario de Ciudad Real, Ciudad Real, Spain

*Corresponding author.

E-mail address: miguelterry85@hotmail.com

(M.Á. Flores-Terry).

1578-2190/

© 2016 Elsevier España, S.L.U. and AEDV. All rights reserved.

Proximal Subungual Onychomycosis Due to *Aspergillus niger*: A Simulator of Subungual Malignant Melanoma[☆]



Onicomycosis subungueal proximal por *Aspergillus niger*: un simulador de melanoma maligno subungueal

To the Editor:

The majority of onychomycoses are caused by dermatophytic fungi or yeasts; those due to nondermatophyte molds

account for approximately 10% worldwide, with different sources reporting between 1.45% and 17.6%.^{1,2} However, numerous nondermatophyte filamentous fungi are often isolated as commensals from pathologic nails, mainly from the toenails of persons of advanced age.³

A 64-year-old woman with diabetes mellitus consulted for a 2-month history of discoloration of the nail and nail bed of her left great toe. She denied trauma but did describe a previous episode of periungual inflammation.

Physical examination revealed onychoclasia and onychomadesis with black discoloration of the proximal nail bed and marked dystrophy of the nail plate (Fig. 1A). Hutchinson sign was negative and dermoscopy did not reveal a micro-Hutchinson sign.

The differential diagnosis included subungual melanoma and infection, and microbiology examination of the nail was therefore requested. Culture was positive for *Aspergillus niger* (Fig. 2), and the search for dermatophytes and bacterial culture was negative. Based on these findings, we made a diagnosis of proximal subungual onychomycosis due to *A. niger*. Treatment was started with 40% urea and bifonazole

[☆] Please cite this article as: Álvarez-Salafranca M, Hernández-Ostiz S, Salvo Gonzalo S, Ara Martín M. Onicomycosis subungueal proximal por *Aspergillus niger*: un simulador de melanoma maligno subungueal. *Actas Dermosifiliogr*. 2017;108:481–484.

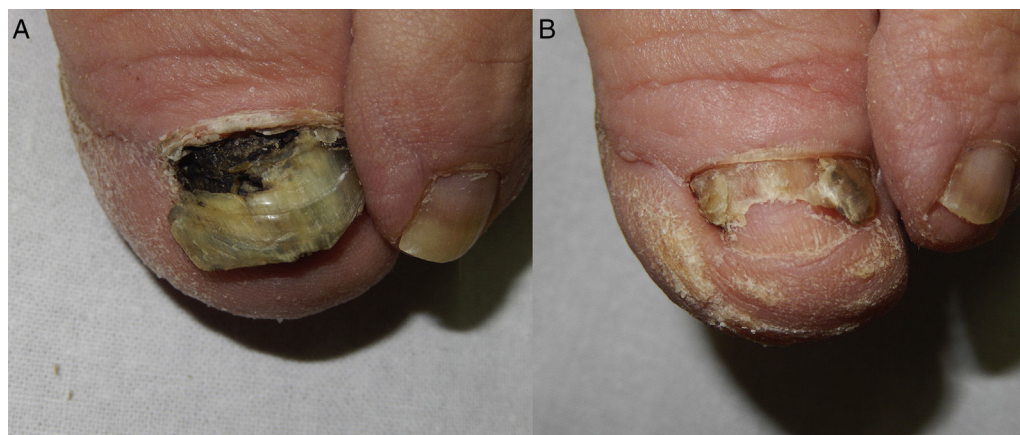

Figure 1 A, Onychoclasia and onychomadesis with dark pigment in the nail bed. B, Partial residual onychia with almost complete disappearance of the pigment.

cream under an occlusive dressing, leading to a progressive clinical improvement. At 5 months the pigmentation had practically disappeared, leaving a residual partial onychia (Fig. 1B); cultures were negative.

Onychomycosis due to nondermatophyte molds is difficult to diagnose, as these organisms are common contaminants of diseased nails.¹ In contrast to the dermatophytes, *Aspergillus* spp. is a nonkeratophilic fungus that usually causes secondary infection in nails damaged by trauma or previous disease.^{3,4} However, both *Aspergillus* and other molds are an emerging cause of onychomycosis, mainly affecting the toenails of diabetic patients.^{5,6} The apparent increase in the incidence of this type of infection could be due to aging of the population, better diagnostic techniques, or increased awareness of the pathogenic capacity of these organisms.^{4,5} Other nondermatophyte filamentous fungi associated with nail disease include *Scop-*

ulariopsis brevicaulis, *Acremonium* spp., and *Fusarium* spp.^{1,4}

The clinical presentation of onychomycosis due to molds can be very variable, and the diagnosis cannot be established on clinical criteria alone.³ In the literature, it has been indicated that *A. niger* can be associated with periungual inflammation, brown-to-black pigmentation, or even striate melanonychia.^{4,7-9}

Melanonychia of fungal origin with brown or black pigmentation of the nail unit is relatively rare and can mimic subungual melanoma (Table 1).⁷ It is more common in men, in older adults, and in the toenails. The majority of cases are due to dermatiaceous or melanin-producing fungi, with the most common being *Scytalidium dimidiatum* and *Alternaria* spp.⁷ *A. niger* is a nondermatiaceous fungus, whose dark color is due to aspergillin pigment, which can make the nail and proximal nail fold dark brown or black.⁷

The diagnostic criteria of onychomycosis due to nondermatophyte molds are not well-established. In general, 6 major criteria suggest the pathogenic nature of the nondermatophyte fungus (observation on direct examination, positive culture, repeated isolation, inoculum count, the exclusion of dermatophyte fungi, and histology), with 3 criteria being necessary to exclude simple colonization.¹ Our patient satisfied 2 criteria (positive culture and the exclusion of a dermatophyte), but histology and the inoculum count were not performed. The very characteristic melanonychia was suggestive of *A. niger* as the causative agent.

The differential diagnosis of fungal melanonychia should include subungual hematoma, racial pigmentation, drug-induced melanonychia, exogenous pigmentation, and melanocyte hyperplasia, including subungual melanoma.⁷

The treatment of onychomycosis due to molds is often unsatisfactory.^{2,3} The onychomycoses associated with global nail pigmentation are considered difficult to treat.⁷ *A. niger*, on the other hand, has shown a good response to topical ciclopirox, oral terbinafine, and oral itraconazole.^{1,2,4,7,10} Photodynamic therapy with methyl aminolevulinate and other photosensitizers has also been shown to be effective




Figure 2 Colonies of *Aspergillus niger* on Sabouraud medium.

Table 1 Clinical Presentation of Melanonychia of Fungal Origin.

Clinical Presentation	Causative Fungi	Comments
Longitudinal melanonychia	Dermatophytes: • <i>Trichophyton rubrum</i> varietas <i>nigricans</i>	Typically broader distally
Diffuse brown pigmentation	Molds: • <i>Scytalidium dimidiatum</i> • <i>Aspergillus niger</i> • <i>Alternaria alternata</i>	
Proximal subungual onychomycosis	Common clinical presentation of onychomycosis due to nondermatophyte molds	Frequent association with paronychia, able to induce nail pigmentation due to the activation of host melanocytes
Distal and lateral subungual onychomycosis	• <i>Alternaria alternata</i> • <i>Scytalidium</i> spp	<i>Alternaria</i> : occasionally distal onycholysis <i>Scytalidium</i> : frequent association with paronychia
Superficial black onychomycosis	• <i>Aspergillus niger</i>	Frequent association with periungual inflammation and dark pigmentation of the proximal nail fold in the case of <i>A. niger</i>
Total nail dystrophy	• <i>Scopulariopsis brevicaulis</i> • <i>Scopulariopsis brevicaulis</i>	Any of the clinical forms can lead to complete destruction of the nail

Sources: Kim et al.⁴ and Finch et al.⁷

in the treatment of some nondermatophyte molds, and can be considered in cases with a poor response to conventional treatments,¹¹ but the presence of pigment, as in our case, could affect efficacy.

In conclusion, we have presented a case of proximal subungual onychomycosis due to *A. niger*. Despite its low frequency, its characteristic clinical presentation means this infectious agent must be taken into account in the differential diagnosis of pigmented nail dystrophy. In these cases, the differential diagnosis should always include malignant melanoma, and biopsy should be considered in case of doubt.

Conflicts of Interest

The authors declare that they have no conflicts of interest.

References

- Gupta AK, Drummond-Main C, Cooper EA, Britnell W, Piraccini BM, Tosti A. Systematic review of nondermatophyte mold onychomycosis: Diagnosis, clinical types, epidemiology, and treatment. *J Am Acad Dermatol.* 2012;66:494–502.
- Tosti A, Piraccini BM, Lorenzi S. Onychomycosis caused by nondermatophytic molds: Clinical features and response to treatment of 59 cases. *J Am Acad Dermatol.* 2000;42:217–24.
- Del Palacio A, Pazos C, Cuétara S. Onicomicosis por hongos filamentosos no dermatofitos. *Enferm Infecc Microbiol Clin.* 2001;19:439–42.
- Kim DM, Suh MK, Ha GY, Sohng SH. Fingernail onychomycosis due to *Aspergillus niger*. *Ann Dermatol.* 2012;24:459–63.
- Nouripour-Sisakht S, Mirhendi H, Shidfar MR, Ahmadi B, Rezaei-Matehkolaei A, Geramishoar M, et al. *Aspergillus* species as emerging causative agents of onychomycosis. *J Mycol Med.* 2015;25:101–7.
- Wijesuriya TM, Kottahachchi J, Gunasekara TD, Bulughapitiya U, Ranasinghe KN, Neluka Fernando SS, et al. *Aspergillus* species: An emerging pathogen in onychomycosis among diabetics. *Indian J Endocrinol Metab.* 2015;19:811–6.
- Finch J, Arenas R, Baran R. Fungal melanonychia. *J Am Acad Dermatol.* 2012;66:830–41.
- Tosti A, Piraccini BM. Proximal subungual onychomycosis due to *Aspergillus niger*: Report of two cases. *Br J Dermatol.* 1998;139:156–7.
- García C, Arenas R, Vasquez del Mercado E. Subungual black onychomycosis and melanonychia striata caused by *Aspergillus niger*. *Skinmed.* 2015;13:154–215.
- De Doncker PR, Scher RK, Baran RL, Decroix J, Degreef HJ, Roseeuw DI, et al. Itraconazole therapy is effective for pedal onychomycosis caused by some nondermatophyte molds and in mixed infections with dermatophytes and molds: A multicenter study with 36 patients. *J Am Acad Dermatol.* 1997;36:173–7.
- Robres P, Aspiroz C, Rezusta A, Gilaberte Y. Utilidad de la terapia fotodinámica en el manejo de la onicomicosis. *Actas Dermosifiliogr.* 2015;106:795–805.

M. Álvarez-Salafranca,^{a,*} S. Hernández-Ostiz,^a
S. Salvo Gonzalo,^b M. Ara Martín^a

^a *Servicio de Dermatología, Hospital Clínico Universitario Lozano Blesa, Zaragoza, Spain*

^b *Servicio de Microbiología, Hospital Clínico Universitario Lozano Blesa, Zaragoza, Spain*

* Corresponding author.

E-mail address: marcialaspn@gmail.com

(M. Álvarez-Salafranca).

1578-2190/

© 2016 Elsevier España, S.L.U. and AEDV. All rights reserved.

Late Xanthomatous Pseudotumor Following Treatment for Breast Cancer[☆]



Seudotumor xantomatoso diferido tras tratamiento de cáncer de mama

To the Editor:

Radiation therapy is well known to cause both acute and chronic changes in irradiated skin. Isolated cases of immediate xanthomatous changes following radiotherapy or chemotherapy have been described in association with certain tumors and with inflammatory disorders such as herpes zoster infection and mosquito bites.

We present the case of an 83-year-old woman with a history of diabetes mellitus, dyslipidemia, chronic kidney failure, Parkinson disease, and left breast cancer treated with breast-conserving surgery with axillary lymph node dissection, radiotherapy, and chemotherapy in 2008. The patient was referred to our department for assessment of an asymptomatic yellowish plaque of 6 months' duration on the left breast. The physical examination showed a large yellow-brown plaque that was slightly hard to the touch and had a verrucous, papilliform surface surrounded by an erythematous halo. The plaque had well-delimited borders and a peculiar geometric shape. There was no evidence of inflammation or local infection (Fig. 1). No other relevant findings were observed in the examination.

A skin biopsy was performed to investigate the suspected diagnoses of tumor recurrence, xanthogranulomatous mastitis, and radiation-induced xanthomatous changes. The histopathologic findings showed a thinned epidermis with flattened rete ridges, an infiltrate consisting of numerous clusters of foamy histiocytes interspersed with inflammatory cells in the superficial dermis, and discrete inflammatory interstitial infiltrates in the deep dermis (Fig. 2). There were no signs suggestive of malignancy. The xanthoma-like cells were positive for CD68 and negative for cytokeratins in the immunohistochemical study. Results of a complete blood count, chest radiograph, and abdominal ultrasound were unremarkable.

A diagnosis of delayed xanthomatous pseudotumor secondary to chemotherapy and radiotherapy was established.

The general criteria for diagnosing radiation-induced tumors include histologic confirmation of a tumor in the irradiated area, a period of latency between exposure to radiation and development of the tumor, and exclusion of a tumor before radiotherapy.¹

Few cases of xanthomatous transformation have been reported in patients with tumors treated by radiotherapy and/or chemotherapy, and most have involved B-cell lymphomas (Table 1).¹⁻⁹

These inflammatory pseudotumors are an enigmatic entity and appear to be due to a localized inflammatory process mediated by inadequate production of cytokines. Several terms have been proposed to describe formations of xanthomatous cells that appear after radiotherapy and/or chemotherapy, including *postchemotherapy histiocyte-rich pseudotumor*, *xanthomatous pseudotumor*, and *benign histiocytic proliferation with xanthomatous changes*.^{2,5,7,9,10}

Despite the few cases published, it has been hypothesized that these xanthomatous cells may be histiocytes that survived the chemotherapy or radiotherapy or histiocytes from peripheral blood that engulf necrotic fat debris released by destroyed tumor cells and become xanthomatous cells.^{1,3-5,7,9} It is plausible that chemotactic substances released in response to the tumor necrosis trigger the recruitment of monocytes, which then differentiate into histiocytes. These, in turn, would be activated, increase in size, and trigger the release of more chemokines, leading to the recruitment of additional monocytes and a considerable accumulation of histiocytes in response to the tumor necrosis.⁷ This process does not appear to be

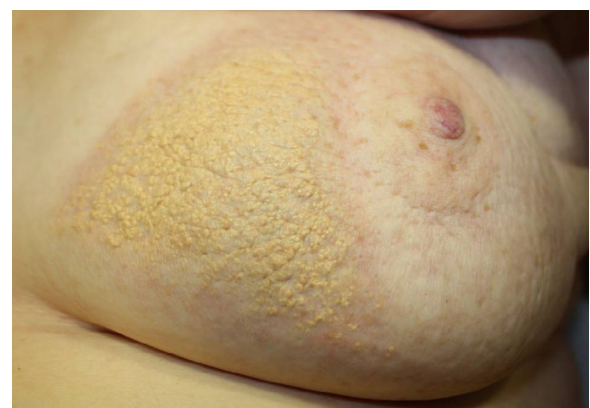

Figure 1 Yellowish plaque with a verrucous, papilliform surface surrounded by an erythematous halo on the left breast.

[☆] Please cite this article as: González-Sabín M, Mallo-García S, Rodríguez-Díaz E, Gonzalvo-Rodríguez P. Seudotumor xantomatoso diferido tras tratamiento de cáncer de mama. *Actas Dermosifiliogr.* 2017;108:484-486.