




ACTAS Derma-Sifiliográficas

Full English text available at
www.actasdermo.org



CASE FOR DIAGNOSIS

Horizontal melanonychia

Melanoniquia longitudinal

Case presentation

An 80-year-old man presented with a 2-month history of fingernail discoloration. He had been diagnosed as



having chronic myeloid leukemia and treated with imatinib 400 mg/day for 3 months. His medical history was not significant except for diabetes mellitus, hypertension and his medications included insulin aspart and ramipril. Examination of the fingernails revealed black-brown discoloration of the distal nail plates (Fig. 1). There was no hyperpigmentation of the toenails, oral mucosa, or skin, and the remainder of the physical examination was normal.

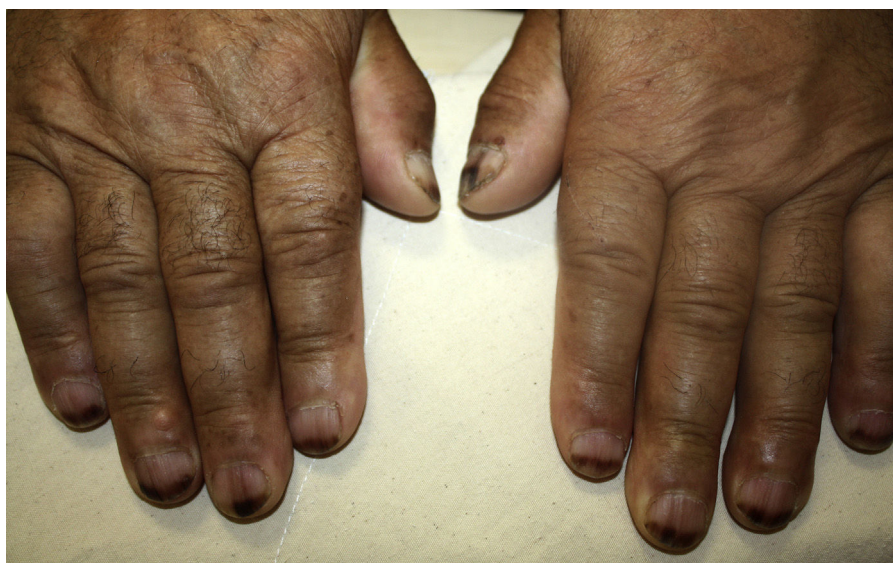

Figure 1 Horizontal melanonychia involving the distal portion of fingernails.

What is your diagnosis?

Diagnosis

Horizontal melanonychia induced by imatinib.

Clinical course and treatment

Considering the temporal relationship between imatinib therapy and onset of nail pigmentation, a diagnosis of imatinib-induced melanonychia was made. Modification in the imatinib treatment was not required. The patient is still on imatinib treatment with a favorable response and pigmented portion of the nails has gradually grown out with proximal normal-appearing nails.

Comment

Recent advances in cancer treatment led to the development of new drugs which target specific molecules and pathways in cancer pathogenesis. Among these targeted therapies, imatinib is a multikinase inhibitor used mainly in the treatment of chronic myeloid leukemia (CML) and gastrointestinal stromal tumors (GIST).¹ Imatinib exerts its effects through inhibition of tyrosine kinases such as C-kit, BCR-Abl and platelet-derived growth factor receptors (PDGFR).¹ Considering these target molecules are also expressed in the skin, imatinib may cause a wide spectrum of mucocutaneous adverse effects, including superficial edema, non-specific skin eruption and pruritus.¹

Moreover, imatinib is also associated with pigmentary changes.¹ Pigmentary changes due to imatinib are usually seen as localized or generalized depigmentation,¹ whereas hyperpigmentation of skin, mucosa or nails have rarely been reported.²⁻⁶ The mechanism underlying the depigmentation effect is the inhibition of C-kit, which is a key factor in melanocyte proliferation.¹ However, the mechanism leading to hyperpigmentation remains obscure. It has been suggested that a drug metabolite chelated to iron and melanin may contribute to development of hyperpigmentation.²

Nail hyperpigmentation, or melanonychia, may occur due to a wide variety of drugs including imatinib. Imatinib-induced melanonychia has been previously reported in four CML patients.³⁻⁶ Unlike our patient, two of the patients had also pigmentation of the oral mucosa,^{4,5} and the other two developed isolated nail pigmentation.^{3,6} Similar to our case, nail hyperpigmentation was managed without modification or interruption of imatinib treatment in all patients.

In conclusion, despite its potential to improve hyperpigmentation disorders, imatinib may lead to the development of melanonychia. Considering the increased use of this targeted chemotherapeutic agent, dermatologists are more likely to see this disorder. Imatinib should be kept in mind among the list of medications causing melanonychia and patients should be assured about the benign and temporary nature of the condition, which ends up with complete resolution.

Conflict of interest

None declared.

Financial support

None.

References

1. Reyes-Habito CM, Roh EK. Cutaneous reactions to chemotherapeutic drugs and targeted therapy for cancer: Part II. Targeted therapy. *J Am Acad Dermatol*. 2014;71, e1-217.e11.
2. Li CC, Malik SM, Blaese BF, Dehni WJ, Kabani SP, Boyle N, et al. Mucosal pigmentation caused by imatinib: report of three cases. *Head Neck Pathol*. 2012;6:290-5.
3. Prabhaskar K, Biswas G, Prasad N, Karant N, Sastry PS, Parikh PM. Imatinib-induced nail hyperpigmentation in chronic myeloid leukemia. *Indian J Dermatol Venereol Leprol*. 2006;72:63-4.
4. McPherson T, Sherman V, Turner R. Imatinib-associated hyperpigmentation, a side effect that should be recognized. *J Eur Acad Dermatol Venereol*. 2009;23:82-3.
5. Steele JC, Triantafyllou A, Rajlawat BP, Field EA. Oral mucosal hyperpigmentation and horizontal melanonychia caused by imatinib. *Clin Exp Dermatol*. 2012;37:432-3.
6. Das A, Podder I, Kumar D, Ghosh A, Shome K. Imatinib-induced melanonychia: an unusual presentation. *Indian J Dermatol*. 2015;60:412-3.

A. Salman^{a,*}, A. Eser^b, I. Kaygusuz Atagunduz^b, T. Ergun^a

^a *Marmara University School of Medicine, Department of Dermatology, Istanbul, Turkey*

^b *Marmara University School of Medicine, Department of Hematology, Istanbul, Turkey*

*Corresponding author.

E-mail addresses: asalmanitf@gmail.com, andac.salman@marmara.edu.tr (A. Salman).