




REVISTA DE GASTROENTEROLOGÍA DE MÉXICO

www.elsevier.es/rgmx



SCIENTIFIC LETTERS

***H. pylori*-associated gastric lymphoma: Complete remission in an HIV-positive patient treated with HAART and *H. pylori* eradication therapy[☆]**



Linfoma gástrico asociado a H. pylori: remisión completa con tratamiento de TARAA y erradicación de H. pylori en un paciente VIH-positivo

B-cell non-Hodgkin's lymphoma (NHL) is one of the most frequently observed neoplasias in patients with HIV infection. This association has been observed since the beginning of the HIV epidemic and is considered an AIDS-defining condition.¹

NHL presents in extranodal form more frequently in HIV-positive than in HIV-negative patients. The most commonly affected extranodal site is the gastrointestinal tract.² According to histologic subtype, diffuse large B-cell lymphoma (DLBCL) and Burkitt's lymphoma are the most common forms of NHL. It is estimated that the incidence of NHL in patients with HIV infection is 100 times greater than in the general population.³

On the other hand, gastric MALT lymphomas are often associated with *Helicobacter pylori* (*H. pylori*) infection. Gastric MALT lymphoma is etiopathologically related to chronic *H. pylori* infection. Complete remission after *H. pylori* eradication has been described in low-grade MALT lymphomas as well as in high-grade MALT lymphomas in both immune-competent and AIDS patients, without the use of anti-cancer chemotherapeutic agents.⁴ Only a few reports have described the complete remission of *H. pylori*-positive DLBCL in an HIV+ patient treated with HAART and *H. pylori* eradication, alone.⁵

We present herein an HIV+ patient with *H. pylori*-positive DLBCL.

A 47-year-old man presented with a 3-month history of heartburn, epigastric pain, and weight loss of 5 kg. The patient was afebrile with normal findings on physical examination. Laboratory tests reported the patient to be

HIV-positive with a viral load of 1,240,000 copies/mL, a total lymphocyte count of 2,137/mm³, and CD4 of 725/mm³.

Upper gastrointestinal endoscopy revealed an 8 cm ulcerated gastric tumor on the greater curvature. Multiple biopsies were taken for pathologic and immunohistochemical analysis. Analysis confirmed a hypercellular neoplastic lesion of lymphoid origin that almost entirely replaced the mucosa with apoptotic cells and isolated polymorphonuclear cells. Giemsa staining revealed bacilli morphologically compatible with *H. pylori* (fig. 1). Immunohistochemical results were CD3–, CD5–, CD10–, CD20+, CD45+, BCL6+, Kappa +, and Lambda– (fig. 2).

The diagnoses reached were diffuse large B-cell gastric lymphoma, HIV infection, and *H. pylori*-associated gastritis.

An abdominal CT scan showed a gastric mass without apparent adenomegaly or metastasis.

The patient was prescribed highly active antiretroviral therapy (HAART) (Efavirenz 600 mg/ Emtricitabine 200 mg/ Tenofovir 300 mg q.d.) and *H. pylori* eradication therapy (Omeprazole 20 mg/ Clarithromycin 500 mg Amoxicillin 1000 mg q.12 h 10 days). No antineoplastic chemotherapy was given.

At one-year follow up, the patient is asymptomatic with no evidence of tumor activity on endoscopy or biopsy, with an undetectable viral load, and a CD4 count of 543/mm³.

One year after the initiation of treatment with HAART and *H. pylori* eradication and no use of anticancer agents, the patient remains in complete remission. Ribiero et al. report a similar case in which a patient achieved complete remission without the use of antineoplastic agents (in MALT lymphoma)⁴ and Okame et al. reported a case of stage IE AIDS-related gastric DLBCL that responded to *H. pylori* eradication therapy and HAART.⁵

HIV patients with gastric NHL treated only with HAART and *H. pylori* eradication therapy have a relatively good prognosis. A French study described 8 patients with MALT lymphoma, 6 of which had gastric involvement. Of these, 5 had concurrent *H. pylori* infection. Through the use of HAART and *H. pylori* eradication, complete remission was achieved in 100% of the patients with *H. pylori*-associated gastric lymphoma.⁶ In another study, 11 out of 16 patients (68.8%) with pure (de novo) DLBCL achieved complete remission after *H. pylori* eradication therapy.⁷

There are complete remission rates of approximately 80% with antibiotic therapy. This is mainly due to the fact that lymphoma growth in the initial stages of lymphomagenesis is stimulated by contact between neoplastic B cells and intratumoral *H. pylori*-specific T cells. It then follows that

[☆] Please cite this article as: Verdusco-Rodríguez L, Ramírez-Pérez F, Clendenin RM, Cruz Lara LA. Linfoma gástrico asociado a *H. pylori*: remisión completa con tratamiento de TARAA y erradicación de *H. pylori* en un paciente VIH-positivo. Revista de Gastroenterología de México. 2017;82:92–94.

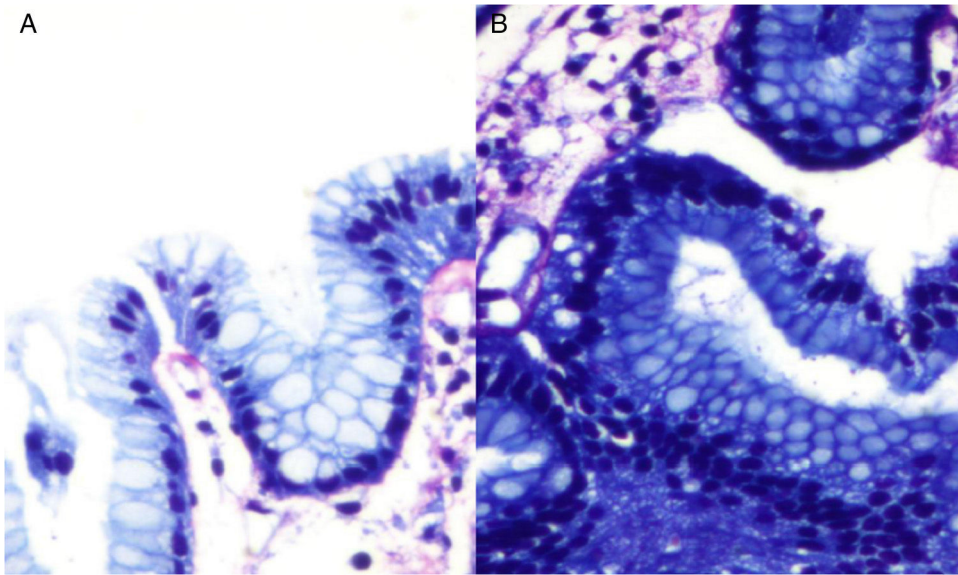


Figure 1 Giemsa stain. A and B) Bacilli morphologically compatible with *H. pylori*.

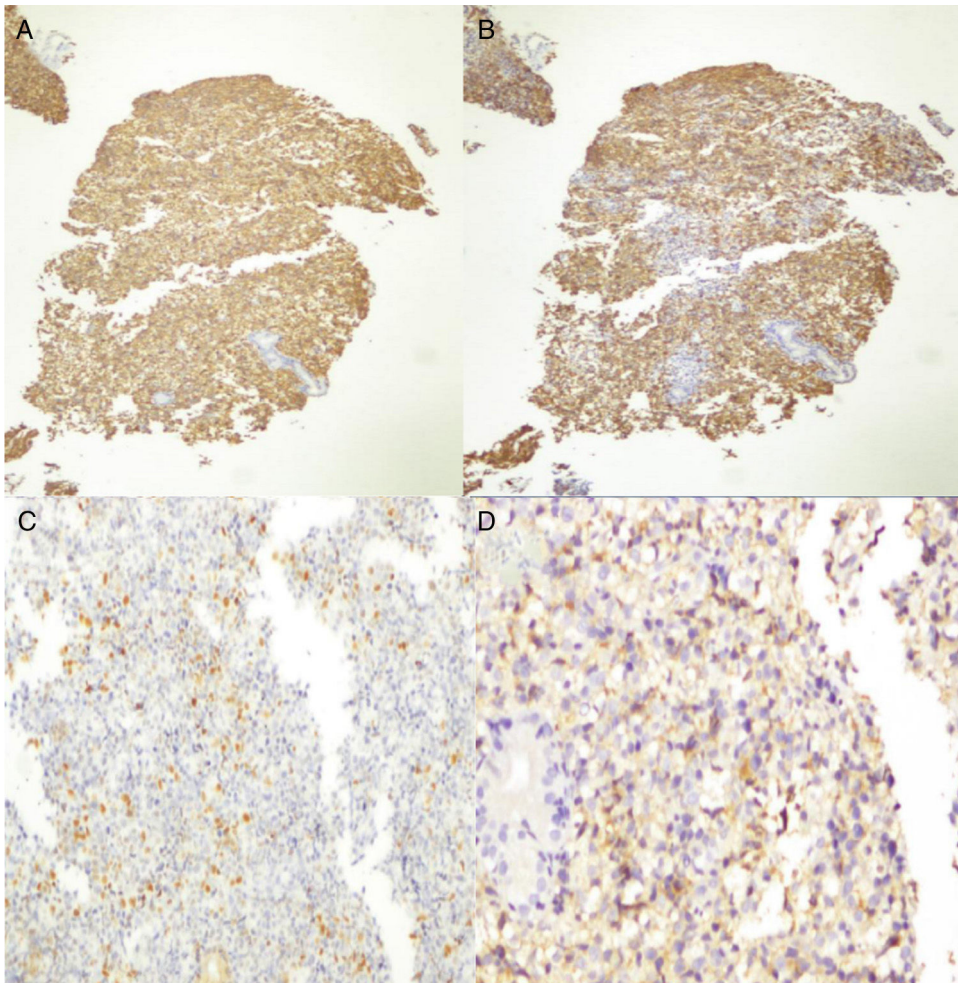


Figure 2 Immunohistochemical analysis. A) Positive immunoreaction to CD45 in neoplastic lymphocytes and in reactive B and T lymphocytes. B) Positive immunoreaction to CD20 in neoplastic lymphocytes. C) Focally positive Bcl-6 immunoreaction in neoplastic cells. D) Focally positive immunoreaction for Kappa in neoplastic cells.

H. pylori eradication treatment eliminates this stimulus.⁸ In addition, certain protein expression is related to good prognosis. CD-10 and BCL-6 are regarded as important markers in diagnosing germinal center B cell DLBCL and many studies have suggested that CD10 and BCL-6 expression in DLBCL predicts better overall survival rates.⁹

The treatment of DLBCL has evolved from routine gastrectomy to more conservative therapies such as radiotherapy in little more than a decade. The outcome of our case supports the suggestion in recent trials that excellent results can be obtained by treating limited-stage *H. pylori*-positive gastric DLBCL with antibiotics alone, reserving chemo-radiotherapy as an option for unresponsive patients and those with poor-prognosis.¹⁰

Financial disclosure

None.

Conflict of interest

The authors declare that they have no conflict of interests.

References

1. Herida M, Mary-Krause M, Kaphan R, et al. Incidence of non aids-defining cancers before and during the highly active antiretroviral therapy era in a cohort of human immunodeficiency virus infected patients. *J Clin Oncol*. 2003;21:3447–53.
2. Spina M, Carbone A, Vaccher E, et al. Outcome in patients with non-Hodgkin lymphoma and with or without human immunodeficiency virus infection. *Clin Infect Dis*. 2004;38:142–4.
3. Pizarro Á, García H, Riquelme A, et al. Linfomas asociados a infección por VIH en pacientes del Hospital Clínico San Borja Arriarán/Fundación Arriarán 2001-2008. *Rev Chilena Infectol*. 2013;30:23–30.
4. Ribeiro JM, Lucas M, Palhano MJ, et al. Remission of a high-grade gastric mucosa associated lymphoid tissue (MALT) lymphoma following *Helicobacter pylori* eradication and highly active

- antiretroviral therapy in a patient with AIDS. *Am J Med*. 2001;111:328–9.
5. Okame M, Takaya S, Sato H, et al. Complete regression of early-stage gastric diffuse large B-cell lymphoma in an HIV-1-infected patient following *Helicobacter pylori* eradication therapy. *Clin Infect Dis*. 2014;58:1490–2.
6. Boulanger E, Meignin V, Baia M, et al. Mucosa-associated lymphoid tissue lymphoma in patients with human immunodeficiency virus infection. *Br J Haematol*. 2008;140:464–74.
7. Kuo SH, Yeh KY, Wu MS, et al. *Helicobacter pylori* eradication therapy is effective in the treatment of early-stage *H. pylori*-positive gastric diffuse large B-cell lymphomas. *Blood*. 2012;119:4838–44.
8. Morgner A, Miehke S, Fischbach W, et al. Complete remission of primary high-grade B-cell gastric lymphoma after cure of *Helicobacter pylori* infection. *J Clin Oncol*. 2001;19:2041–8.
9. Zhang Z, Shen Y, Shen D, et al. Immunophenotype classification and therapeutic outcomes of Chinese primary gastrointestinal diffuse large B-cell lymphoma. *BMC Gastroenterol*. 2012;12:1–7.
10. Cuccurullo R, Govi S, Ferreri AJ. De-escalating therapy in gastric aggressive lymphoma. *World J Gastroenterol*. 2014;20:8993–7.

L. Verduzco-Rodríguez^a, F. Ramírez-Pérez^{b,*},
R.M. Clendenin^b, L.A. Cruz Lara^b

^a *Department of Oncology, Rio Blanco Regional Hospital, Ver., Mexico*

^b *Universidad Veracruzana, Faculty of Medicine, Campus Cd Mendoza, Ver., Mexico*

* Corresponding author at: Av. Miguel Hidalgo, Esq. Carrillo Puerto s/n, Colonia Centro, C.P. 94740, Camerino Z. Mendoza, Veracruz, Mexico.

E-mail address: fabio_k111@hotmail.com

(F. Ramírez-Pérez).

2255-534X/

© 2016 Asociación Mexicana de Gastroenterología. Published by Masson Doyma México S.A. This is an open access article under the CC BY-NC-ND license (<http://creativecommons.org/licenses/by-nc-nd/4.0/>).

Pyogenic granuloma of the jejunum; diagnosis and treatment with double-balloon enteroscopy: A case report[☆]



Granuloma piógeno de yeyuno. Diagnóstico y tratamiento con enteroscopia doble balón. Reporte de un caso

The causes of gastrointestinal bleeding of obscure origin (GIBOO) are frequently located in the small bowel,

and therefore both capsule endoscopy and double-balloon enteroscopy (DBE) can be used for identifying its etiology.

Pyogenic granuloma (PG) is an inflammatory vascular tumor that typically affects the oral cavity and skin. Digestive system involvement is a rare cause of GIBOO. We present herein a case of PG diagnosed and treated through DBE.

A 71-year-old woman had a past history of type 2 diabetes mellitus (metformin), chronic obstructive pulmonary disease (aerosol bronchodilators), congestive heart disease (hydrochlorothiazide), and coronary disease (isosorbide mononitrate). She sought medical attention for anemia of 8-month progression with no apparent bleeding. She received oral iron treatment with no response and required numerous hospitalizations for blood transfusions.

Upper gastrointestinal video endoscopy and video colonoscopy with intubation of the terminal ileum were normal. Serology for celiac disease was negative, the same as the gynecologic studies. Peripheral blood tests showed microcytic and hypochromic anemia.

[☆] Please cite this article as: De María J, Curvale C, Guidi M, Hwang H, Matanó R, Granuloma piógeno de yeyuno. Diagnóstico y tratamiento con enteroscopia doble balón. Reporte de un caso. *Revista de Gastroenterología de México*. 2017;82:94–96.