



CLINICAL IMAGE IN GASTROENTEROLOGY

Vanek's tumor: A rare gastric polyp[☆]

El tumor de Vanek: un pólipo gástrico poco común

E. Gravito-Soares*, M. Gravito-Soares, C. Sofia



Gastroenterology Department, Centro Hospitalar e Universitário de Coimbra, Coimbra, Portugal

Inflammatory fibroid polyp (IFP) or Vanek's tumor is extremely rare, representing less than 0.1% of all gastric polyps. Most are located in the antrum (70%) and may arise from the submucosa or mucosa. The majority of lesions are smaller than 15 mm. Large polyps can be

symptomatic or complicated by bleeding, anemia, or intermittent gastric outlet obstruction. Complete endoscopic or surgical resection is indicated for large or symptomatic polyps to make the definitive diagnosis and define treatment.

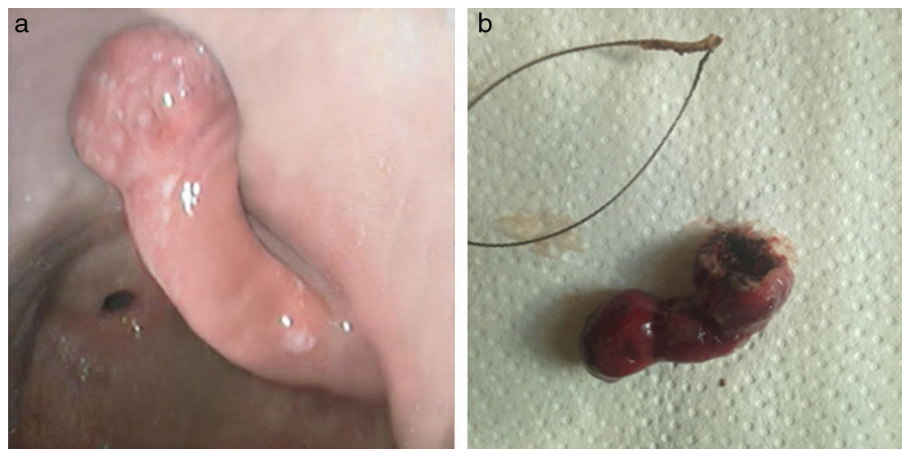


Figure 1 a-b) Inflammatory fibroid polyp: a) before (endoscopic aspect) and b) after (macroscopic specimen) polypectomy.

[☆] Please cite this article as: Gravito-Soares E, Gravito-Soares M, Sofia C. El tumor de Vanek: un pólipo gástrico poco común. *Revista de Gastroenterología de México*. 2017;82:87–88.

* Corresponding author. Praceta Professor Mota Pinto 3000-075, Coimbra, Portugal. Tel.: +39400483; fax: +239701517.

E-mail address: es18497@gmail.com (E. Gravito-Soares).

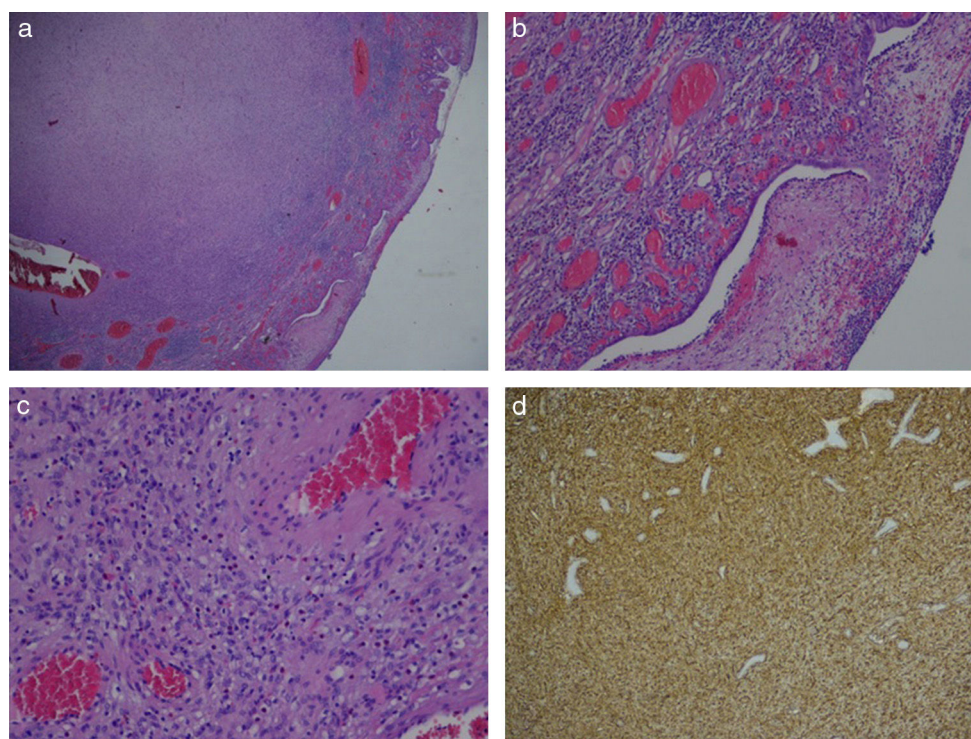


Figure 2 Histopathology analysis with inflammatory fibroid polyp diagnosis: a) amplification (x20), b) amplification showing granulated tissue with a proliferation of spindle cell elements (x100), c) amplification showing small, thick capillaries and a mixed inflammatory infiltrate with eosinophils (x200), and d) amplification with staining positive for CD34 (x40).

A 65-year-old woman was referred to our endoscopy unit with abdominal pain and iron deficiency anemia. The esophagogastroduodenoscopy showed a single large pedunculated polyp of about 40 mm in diameter, with erosions on its surface, located at the posterior portion of the antrum. A polypectomy with coagulation current and no previous submucosal injection was performed without complications (fig. 1). The histopathologic study revealed a lesion composed of spindle cells, a network of small capillaries, and a mixed inflammatory infiltrate with eosinophils in the submucosa. Immunohistochemical staining was diffuse and strongly positive for CD34 (fig. 2). The patient was asymptomatic with no anemia or polyp recurrence at the 6-month follow-up.

IFPs are usually considered benign lesions, but recent studies suggest the possibility of a neoplastic process. Therefore, endoscopic resection can be indicated in all patients, even those with uncomplicated polyps.

Ethical responsibilities

Protection of persons and animals. The authors declare that the procedures followed conformed to the ethical standards of the responsible committee on human experimentation and were in accordance with the World Medical Association and the Declaration of Helsinki.

Data confidentiality. The authors declare that no patient data appear in this article.

Right to privacy and informed consent. The authors declare that no patient data appear in this article.

Conflict of interest

The authors declare that there is no conflict of interest.