



Journal of Coloproctology

www.jcol.org.br



Original article

Ex vivo sentinel lymph node investigation in colorectal cancer

Antônio Hilário Alves Freitas^{a,b,*}, Alberto Julius Alves Wainstein^b, Tarcizo Afonso Nunes^c

^aBrazilian Society of Coloproctology, Rio de Janeiro, RJ, Brazil

^bTrymed Clinical Research, Belo Horizonte, MG, Brazil

^cUniversidade Federal de Minas Gerais (UFMG), Belo Horizonte, MG, Brazil

ARTICLE INFO

Article history:

Received 1 November 2012

Accepted 15 January 2013

Keywords:

Sentinel lymph node

Ex vivo

Colorectal cancer

Metastases

ABSTRACT

Introduction: In Brazil, about 26,000 cases of colorectal cancer are diagnosed per year. Patients considered at the early stage of disease (without lymph node) evolve with tumor relapse or recurrence in up to a quarter of cases, probably due to understaging. **Objective:** Research on ex vivo sentinel lymph node in patients with colorectal adenocarcinoma.

Materials and methods: We studied 37 patients who underwent curative surgical resection. The marker used to identify lymph nodes was patent blue dye injected into the peritumoral submucosa of the open surgical specimen immediately after its removal from the abdominal cavity.

Results: Ex vivo identification of sentinel lymph node with marker occurred in 13 (35.1%) patients. The sensitivity was 40% and 60% false negative. The detailed histological examination of sentinel lymph nodes with multilevel section and immunohistochemistry showed metastasis in one (4.3%) individual, considered ultra-staging.

Conclusion: The ex vivo identification of sentinel lymph node had questionable benefits, and worse results when include patients with rectal cancer. Restaging of one patient was possible after multilevel section and immunohistochemistry of the sentinel lymph node, but more research is needed to evaluate the role of micrometastases in patients with colorectal cancer.

© 2013 Elsevier Editora Ltda. Este é um artigo Open Access sob a licença de [CC BY-NC-ND](http://creativecommons.org/licenses/by-nc-nd/4.0/)

Pesquisa do linfonodo-sentinela ex vivo no câncer colorretal

RESUMO

Introdução: No Brasil, a cada ano são diagnosticados cerca de 26.000 casos de câncer colorretal. Pacientes com estadiamento considerado inicial, sem linfonodo metastático, evoluem com recorrência ou recidiva do tumor em até um quarto dos casos, por provável subestadiamento. **Objetivo:** pesquisar sobre linfonodo-sentinela ex vivo em pacientes com adenocarcinoma colorretal.

Objetivo: Foram estudados 37 pacientes, submetidos à cirurgia oncológica com ressecção caráter curativo. O marcador de linfonodos utilizado foi o corante azul patente, injetado na submucosa peritumoral da peça cirúrgica aberta imediatamente depois de sua retirada da cavidade abdominal.

Palavras-chave:

Linfonodo-sentinela

Ex vivo

Câncer colorretal

Metástases

* Corresponding author.

E-mail: hilariofreitas@ig.com.br (A. H. A. Freitas)

Pacientes e métodos: A identificação *ex vivo* de linfonodo-sentinela com o marcador ocorreu em 13 (35,1%) pacientes. A sensibilidade do método foi de 40% e o falso negativo de 60%. O exame histológico pormenorizado dos linfonodos-sentinela com multisseção e imunoistoquímica diagnosticou metástase em um (4,3%) indivíduo, sendo considerado ultra-estadiamento.

Resultados: A identificação de linfonodo-sentinela *ex vivo* apresenta benefícios questionáveis, e piores resultados quando são incluídos pacientes com câncer de reto. Foi possível reestadiamento de um paciente depois da realização de multisseção e imunoistoquímica de linfonodos-sentinela, mas mais trabalhos são necessários para estabelecer a importância das micrometástases em pacientes com câncer colorretal.

© 2013 Elsevier Editora Ltda. Este é um artigo Open Access sob a licença de [CC BY-NC-ND](https://creativecommons.org/licenses/by-nc-nd/4.0/)

Introduction

Colorectal cancer incidence worldwide is 1.2 million cases per year, according to the World Health Organization.¹

Sentinel lymph node is considered the first receiving lymphatic drainage from the tumor and thus more likely to contain metastases.²

The treatment of colorectal cancer is surgical, and study of lymph nodes in critically ill individuals has shown that adjuvant chemotherapy increases the disease-free survival of patients with lymph node metastasis.^{3,4}

However, the literature provides a challenge, because patients with colorectal cancer treated at the early stage, without lymph node histology routine; therefore, with no indication for adjuvant therapy, progress with local tumor recurrence or distant metastases in up to 25% of cases.⁵⁻⁷ This fact makes us think about a possible understaging and imposes the need to examine lymph nodes more closely by identifying the sentinel lymph nodes and, adding to the routine histology, a detailed study with multilevel sectioning and immunohistochemistry.

The identification of sentinel lymph node can be done intraoperatively (*in vivo*) or in surgical specimen (*ex vivo*) using dyes and/or radiopharmaceuticals with tropism for lymph nodes. This study, which is unprecedented in Brazil, has been researching on *ex vivo* sentinel lymph node using dye.

Patients and methods

This is a prospective, descriptive and analytical study of sentinel lymph node in patients undergoing colorectal cancer with proposed curative surgery.

It involved 37 patients with colorectal cancer, operated from November 2008 to April 2012 in two institutions: Hospital Alberto Cavalcanti, which belongs to the state public health of the Fundação Hospitalar do Estado de Minas Gerais (FHEMIG); Hospital da Polícia Militar do Estado de Minas Gerais, which serves the military police and their dependents, both located in the city of Belo Horizonte, MG, Brazil.

The study was approved by the Ethics Committee of the Hospitals and the Universidade Federal de Minas Gerais.

Inclusion criteria were patients with colon or rectum cancer; over 21 years of age, adherence to informed consent. Ex-

clusion criteria were evidence of distant metastasis, urgent surgery, or patient's refusal to participate.

Surgical procedure and identification of sentinel lymph node

The procedure was general anesthesia, antisepsis, laparotomy, and oncologic resection of the bowel segment and its mesentery containing the tumor. The surgical specimen was removed from the abdominal cavity. The searching process for sentinel lymph nodes was as follows: a) placing the specimen removed in a surgical table; b) immediate opening of the intestinal lumen to locate the tumor; c) injection of 1 mL of patent blue dye 1% (manufactured by Citopharma Ltda. - Belo Horizonte, MG, Brazil), in the peritumoral submucosa, the volume of dye was divided equally and applied to the four cardinal points around the lesion, using 1 mL syringe and needle 13 x 4.5 mm (Fig. 1); d) peritumoral massage for 5-10 minutes; e) identification by direct visualization of the first blue lymph nodes (Fig. 2), which are considered sentinel lymph nodes, and then marked with surgical thread.

All marked sentinel lymph nodes were removed from the mesentery and sent separately in numbered vials, along with the surgical specimen, to the pathology service.

Histological examination of all lymph node started with routine histology. Lymph nodes were embedded in paraffin blocks cut with a microtome, placed on slides, stained with hematoxylin-eosin and examined by light microscopy. In the absence of metastases by this method, only the sentinel lymph nodes were sent for multilevel section and immunohistochemistry examination.

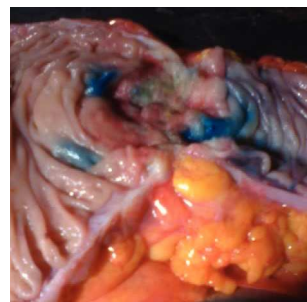


Fig. 1 – Open specimen, with peritumoral points of patent blue dye injection.

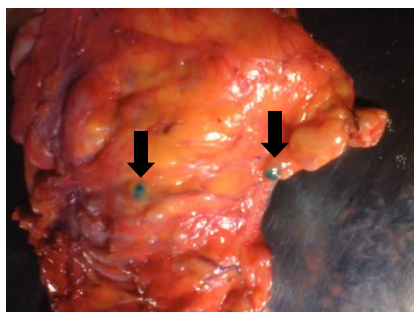


Fig. 2 – Intestinal mesentery with visual identification of sentinel lymph nodes using patent blue dye.

The technique called multilevel section consists of multiple cuts of lymph nodes included in paraffin block, staggered at intervals of 2-3 mm, which are then stained with hematoxylin-eosin and examined in more detail by light microscopy.

For immunohistochemistry, we used AE1/AE3 cytokeratins (Biogenex®). The process phases were as follows: cutting the lymph node to each scaled range of 50 microns; immunoperoxidase, streptavidin, biotin Supersensitive after antigen-induced heat with EDTA buffer, followed by staining control.

For staging, the pathological tumor-node-metastasis (TNM) criteria were followed.⁸

Tumors were located at the right colon, twelve (32%); transverse colon, one (3%); sigmoid colon, two (6%); and rectum, twenty-two (59%). The size ranged from 1-11 cm, with a mean of 3.5 cm (SD = 1.9).

Results

Identification of lymph node using dye

In the 37 study patients, 415 lymph nodes were isolated, mean 11 (SD = 5.7) per patient. The patent blue sentinel lymph node was identified in 13 (35.1%) individuals. We identified 29 sentinel lymph nodes *ex vivo* using dye, with a mean of 2.2 (SD = 1.7) per patient (Table 1).

Dye and histology

Among the 29 sentinel lymph nodes identified using dye, histological examination of routine hematoxylin-eosin diagnosed metastases in 2 (6.8%) and the other 27 (93.2%) had no signs of metastases. Of the 386 non-sentinel nodes, 31 (8%) had metastases, 355 (92%) were free of metastasis (Table 2).

Considering the validity study, in 13 patients with sentinel lymph nodes identified using dye, routine histological examination identified metastases in five (38.4%). Of this group of five patients, one (20%) had metastases exclusively located in sentinel lymph nodes, one (20%) had metastases in both sentinel and non-sentinel lymph nodes, and three (60%) had metastases in non-sentinel lymph nodes, the latter figure represents the false negative. In the other eight patients, despite the identification of sentinel lymph nodes, no metastases

were diagnosed by routine histology with hematoxylin-eosin (Table 3).

Staging of patients

The routine histological examination did not diagnose metastasis in 23 (62.1%) of 37 patients, so they were considered N0 stage. In the other fourteen (37.9%), metastases were diagnosed and classified in stage N+. Thus, staging (TNM) initial sample was: N0 = 23 patients (62.2%) and N+ = 14 patients (37.8%). In the group of 23 patients without metastases by routine histology (stages I or II), additional tests were done in the sentinel lymph node, with multilevel section and immunohistochemical, and metastasis was diagnosed in only one (4.3%), representing the ultra-staging. Therefore, the final staging (TNM) was stage N0 = 22 patients (59.5%) and N+ = 15 patients (40.5%).

Discussion

Technique for *ex vivo* identification of sentinel lymph node

The correct staging of the intestinal tumor is the major factor in patient survival, because when histology identifies lymph node metastasis, patients are referred for chemotherapy with known decreased recurrence and improved survival.^{3,4}

Techniques to identify sentinel lymph node in intestinal tumors has been described for over half a century.⁹ But, the first studies using the *ex vivo* technique in colorectal cancer were published only a little over ten years.¹⁰ In Brazil, there is still no publication, a fact that motivated our study.

Authors who defend the *ex vivo* method describe its main advantages as simple execution; low cost; does not increase the operative time; obeys the principle of the cancer 'no touch tumor'; and without risk of adverse effects such as anaphylaxis.¹¹⁻¹³

In this study, the success rate in identifying sentinel lymph nodes in colorectal cancer was 35.1%. The literature credits worse results by: flaws in the injection; advanced stage of the lesion; mucinous histological type; location in the rectum, and prior radiotherapy.¹⁴⁻¹⁶ In this study, two thirds of the patients were operated on for rectal tumors, and also received chemotherapy + radiotherapy preoperative.

Given the unfavorable results of the study, the investigation of sentinel lymph node in *ex vivo* using patent blue dye is presented as an option to be held in rectal tumors, even with questionable benefits, because it is technically unworkable in rectal tumors, or in a complementary manner in colon tumors, when there has been failure with another technique for identifying sentinel intraoperatively (*in vivo*).

Bookmarks

In our study subject of study for master's thesis at the Universidade Federal de Minas Gerais in 2007, we used patent blue dye and radiopharmaceutical for sentinel lymph node identification during surgery in patients with colon cancer. The results showed the superiority of radioisotope over the dye.¹⁷

Table 1 – Overall outcome of the study.

Patient	Size (cm)	Localization	Blue LNS	Total LN	Metastases in LNS (H-E)	Metastases in LNNS (H-E)	Stage TNM	MS	IQ
1	11	right	00	12	00/00	01/12	III	NR	NR
2	5.5	right	02	19	00/02	00/17	II	Positive	Positive
3	5.5	rectum	02	06	00/02	00/04	II	Negative	Negative
4	2	rectum	00	04	00/00	00/04	II	NR	NR
5	1.5	rectum	00	06	00/00	00/06	II	NR	NR
6	4	sigmoid	06	15	00/06	00/09	I	Negative	Negative
7	4	rectum	00	06	00/00	00/06	II	NR	NR
8	5	right	00	14	00/00	01/14	III	NR	NR
9	2.5	rectum	03	07	00/03	00/04	II	Negative	Negative
10	2.5	rectum	00	04	00/00	00/04	II	NR	NR
11	6	rectum	01	22	00/01	01/21	III	NR	NR
12	6	right	00	08	00/00	01/08	III	NR	NR
13	2	rectum	00	08	00/00	04/08	III	NR	NR
14	4	rectum	00	05	00/00	00/05	II	NR	NR
15	2	rectum	00	06	00/00	00/06	I	NR	NR
16	3.5	rectum	06	11	00/06	01/05	III	NR	NR
17	1.5	rectum	01	01	01/01	00/00	III	NR	NR
18	4	right	01	17	00/01	00/16	I	Negative	Negative
19	5.5	sigmoid	00	15	00/00	00/15	II	NR	NR
20	2.5	rectum	02	14	00/02	05/12	III	Negative	Negative
21	2.5	rectum	00	15	00/00	00/15	II	NR	NR
22	4	rectum	01	25	00/01	00/24	II	Negative	Negative
23	4	right	01	16	00/01	00/15	II	Negative	Negative
24	6.5	right	00	15	00/00	00/15	II	NR	NR
25	3.5	rectum	00	12	00/00	00/12	II	NR	NR
26	6	right	00	17	00/00	00/17	II	NR	NR
27	2	rectum	02	15	00/02	00/13	II	Negative	Negative
28	3	right	00	25	00/00	06/25	III	NR	NR
29	3	right	00	12	00/00	03/12	III	NR	NR
30	1	rectum	00	12	00/00	00/12	I	NR	NR
31	4	rectum	00	09	00/00	00/09	II	NR	NR
32	1.5	rectum	00	07	00/00	00/07	II	NR	NR
33	5	right	00	14	00/00	01/14	III	NR	NR
34	2.5	transverse	01	06	01/01	01/05	III	NR	NR
35	2.5	rectum	00	05	00/00	01/05	III	NR	NR
36	3.5	right	00	10	00/00	05/10	III	NR	NR
37	1	rectum	00	00	00/00	00/00	II	NR	NR
Total	–	–	29	415	02/29	31/386	–	–	–

LN, lymph node; SLN, sentinel lymph node; LNNS, non-sentinel lymph node; HE, hematoxylin-eosin (routine histology); MS, multilevel lymph nodes; IQ, immunohistochemistry of lymph nodes; NR, not performed; Blue, dye uptake.

Vital staining has been used by most authors, because the radiopharmaceuticals add high costs (600 dollars each exam) and logistics complex.

Number of nodes

The number of lymph nodes examined is of great importance for staging, and directly influences treatment and prognosis of patients operated on for colorectal cancer. Current literature states that to obtain reliable pathology, it should be examined at least 10–12 lymph nodes. Publications found five-year survival of approximately 73% when less than 10 lymph nodes were examined, 80% when 11–20 lymph nodes, and 87% with more than 20 lymph nodes examined.¹⁸ The American Joint Committee on Cancer (AJCC) recommends that at least 7–14 lymph nodes should be examined.⁸

In 37 cases studied, we found a mean of 11.2 nodes per patient, in accordance with the recommended stage it is sufficient to reliably.^{19,20}

It is worth noting that in surgical specimens who received radiotherapy, the work is much harder for researcher and pathologist in the search for lymph nodes,²¹ a fact clearly seen in this study, as in one of the patients no lymph node could be studied since there were no remaining lymphoid in surgical specimen.

Sensitivity and false negative

In the specific case of sentinel lymph node study for colorectal tumors, the adverse findings with high rates of false negative did not interfere with the results because the therapeutic radical lymphadenectomy is always maintained, regardless of the presence or absence of metastases in regional lymph nodes.

In this study, the rate of 60% false negative results was found. According to the review work, the average overall rate of false negative rate is 33%, ranging from zero to 63%.^{22–24}

According to the study of validity of this study, the sensitivity was 40%, while in the literature it ranges from 40 to 100%.^{25–27}

Table 2 – Involvement of lymph nodes in 37 surgical specimens of colorectal cancer by routine histopathology with hematoxylin-eosin.

Lymph nodes	Metastases (+)	Metastases (-)	Total
Sentinel	2 (13.0%)	27 (87.0%)	29 (100.0%)
Non sentinel	31 (12.5%)	355 (87.5%)	386 (100.0%)
Total	33	382	415

(+), positive metastasis; (-), negative metastasis.
P = 1.0 (Fisher test).

Table 3 – Histopathology of lymph nodes in patients with colorectal cancer in which sentinel lymph nodes were identified.

Lymph nodes	With metastases	Without metastases	Total
Sentinel	2	1	3
Non-sentinel	3	7	10
Total	5	8	13

CI, confidence interval.
Sensitivity = 40.0% (95% CI: 7.3%–83.0%); specificity = 87.5% (95% CI: 46.7%–99.3%); positive predictive value = 66.7% (95% CI: 12.5%–98.2%); negative predictive value = 70.0% (95% CI: 35.4%–91.9%); accuracy = 69.2% (95% CI: 38.9%–89.6%).

It is known that the more advanced the tumor, the higher will be the rate of false negative and less sensitivity. Therefore, another possible explanation for these results is that the vast majority of patients in this study was treated with probable late diagnoses, whereas 37.8% of patients were already in stage III (lymph nodes with metastases) after routine histology with hematoxylin-eosin.

Staging and micrometastases

Instead of a large number of lymph nodes examined under the microscope with few cuts, a detailed examination of the sentinel lymph nodes most likely to contain metastases could be performed. The commitment of the pathologist, who carried out multilevel section and/or immunohistochemical tests, increases the sensitivity of the method, promotes more adequate patient staging, and is more cost-effective.^{28,29}

Less than 0.5% of the target tissue is removed for routine histology, hence the need for rethinking the care and pathological test techniques in colorectal malignancies.^{30,31}

We believe that all professionals involved in the treatment of malignancies, especially pathologists, need to excel in their primary care, devoting more time to their analysis, so that patients are allocated in the correct staging. For it is known that more compliance with literature recommendations enables to obtain excellent results without increasing costs, just increasing dedication.

In this study, one (4.3%) patient had micrometastases exclusively in sentinel lymph node, after performing additional histological examination, using multilevel section and immunohistochemistry. According to authors, it may be a case where an individual would benefit from the investigation of

sentinel lymph node because the disease is diagnosed when the chances of providing a cure with adjuvant chemotherapy would be greater by attacking the tumor at its initial phase.³²

In an attempt to avoid understaging, special histopathological techniques with multilevel and immunohistochemistry of sentinel lymph nodes may be used. Studies show ultra-staging with a wide range of 4%–50%.^{23,26,33}

Therefore, we need more reliable work and with large samples to assess the actual role of micrometastases both in evolution and in survival, in addition to know if patients operated for colorectal cancer should or not receive adjuvant therapy in these special situations.^{34,35}

Conclusions

The *ex vivo* identification of sentinel lymph node using patent blue dye in patients with colorectal cancer had questionable benefits. Worse results are obtained when the work includes patients operated for rectal cancer, most notably in those who undergo radiotherapy.

Ultra-staging was possible by multilevel section and immunohistochemistry of the sentinel lymph nodes. More research is needed to evaluate the role of micrometastases and the practical applicability of the method.

Conflict of interest

The authors declare no conflict of interest.

REFERENCES

1. World Health Organization (WHO), 2008. Available at: <http://www.who.int/cancer>.
2. Morton DL, Wen DR, Wong JH, Economou JS, Cagle LA, Storm FK, et al. Technical details of intraoperative lymphatic mapping for early stage melanoma. *Arch Surg* 1992;127:392–9.
3. Gordon PH, Nivatvongs S. Principles and practice of surgery for the colon, rectum, and anus, 2.ed. St. Louis, Missouri: Quality Medical Publishing, Inc., 1999.
4. Wolmark N, Rockette H, Mamounas EP. The relative efficacy of 5-FU + leucovorin (LV-FU), 5-FU + levamisole (Lev-FU) and leucovorin, 5-FU + + levamisole (Lev-LV-FU) in Patients with Dukes B and C of the carcinoma colon: first report of NSABP C-04 [abstract 460]. *Proc Am Soc Clin Oncol* 1996;15:205.
5. Bilchick AJ, Nora DT. Lymphatic mapping of nodal micrometastasis in colon cancer: putting the cart before the horse? *Ann Surg Oncol* 2002;9:529–31.
6. Bertoglio S, Sandrucci S, Percivale P, Goss M, Gipponi M, Moresco L, et al. Prognostic value of sentinel lymph node biopsy in the pathologic staging of colorectal cancer Patients. *J Surg Oncol* 2004;85:166–70.
7. Saha S, Seghal R, Patel M, Doan K, Dan A, Bilchick A, et al. A multicenter trial of sentinel lymph node mapping in colorectal cancer: Prognostic Implications for nodal staging and recurrence. *Am J Surg* 2006;191:305–10.
8. Greene FL, Balch CM, Fleming ID (eds.). *AJCC Cancer Staging Handbook: TNM classification of Malignant Tumors*. New York: Springer-Verlag, 2009. p. 129.
9. Braithwaite LR. Flow of lymph from the ileocecal angle. *Br J Surg* 1923;11:7.

10. Wong JH, Steineman S, Calderia C, Bowles J, Namiki T. Ex vivo sentinel node mapping in carcinoma of the colon and rectum. *Ann Surg* 2001;233(4):515–21.
11. Bell SW, Mourra N, Fléjou JF, Parc R, Turet E. Ex vivo sentinel lymph node mapping in colorectal cancer. *Dis Colon Rectum* 2005;48(1):74–9.
12. Demirbas S, Ince M, Baloglu H, Celenk T. Should sentinel lymph node mapping for colorectal cancer be performed? *Turk J Gastroenterol* 2004;5(1):39–44.
13. Smith J, Hwang H, Wiseman KW, Filipenko D, Phang PT. Ex vivo sentinel lymph node mapping in colon cancer: Improving the accuracy of pathologic staging? *Am J Surg* 2006;191:665–8.
14. Sommariva O, Donisi PM, Gnolato B, Vianello R, Pansa VS, Zaninotto G. Factors Affecting false-negative rates on ex vivo sentinel lymph node mapping in colorectal cancer. *Eur J Surg Oncol* 2010;36(2):130–4.
15. van der Zaag ES, Buskens CJ, Kooij N, Akol H, Peters HM, Bouma WH, et al. Improving staging accuracy in colon and rectal cancer by sentinel lymph node mapping: a comparative study. *Eur J Surg Oncol* 2009;35(10):1065–70.
16. Ceranic MS, Kecmanovic DM, Pavlov MJ, Nale DP, Micev MT, Kovacevic PA, et al. Validation and feasibility of ex vivo sentinel lymph node “mapping” by methylene blue in colorectal cancer. *Hepatogastroenterology* 2010;57(102-103):1113–8.
17. Freitas AHA, Nunes TA, Wainstein AJA, Barroso AA, Ricardo Filho OP, Dias MA. Search sentinel lymph node in patients with colon cancer. *Rev Bras Coloproct* 2008;28(2):170–7.
18. Wong JH, Johnson DS, Namike P, Tauchi NP. Validation of ex vivo lymphatic mapping in Hematoxylin-eosin node-negative carcinoma of the colon and rectum. *Ann Surg Oncol* 2004;11:772–7.
19. Benson AB, Schrag D, Somerfield MR, Cohen AM, Figueredo AT, Flynn PJ, et al. American Society of Clinical Oncology recommendations on adjuvant chemotherapy for stage II colon cancer. *J Clin Oncol* 2004;22:3408–19.
20. Rossi BM, Bepu P Jr, Ferreira FO, Santos EMM, Aguiar Jr S, Nakagawa WT, et al. Number of dissected lymph nodes in colorectal cancer Patients Submitted to radical surgery: the quality of oncology treatment. *Applied Cancer Research* 2006;26:27–33.
21. Quadros CA, Lopes A, Araujo I. Suggestion of optimal patient characteristics for sentinel lymph node mapping in colorectal adenocarcinoma. *Arq Gastroentol* 2010;47(4):344–7.
22. Dess Guetz G, Uzzan B, Nicolas P, Cucherat M, Mestier P, Morere JF, et al. Is sentinel lymph node mapping in colorectal cancer a future Prognostic factor? A meta-analysis. *World J Surg* 2007;31:1304–12.
23. Tiffet O, Kaczmarek D, Chambonierre MR, Guillan T, Baccot S, Prevot N, et al. Dubois Combining radioisotopic and blue-dye technique does not Improve the false-negative rate in sentinel lymph node mapping for colorectal cancer. *Dis Colon Rectum* 2007;50:962–70.
24. Joosten JJA, Strobbe JLA, Wauters CAP, Pruszczynski M, Wobbes T, Ruers TJM. Intraoperative lymphatic mapping and the sentinel node concept in colorectal carcinoma. *Br J Surg* 1999;86:482–6.
25. Doekhie FS, Peeters KCMJ, Kuppen PJK, Mesker WE, Tanke HJ, Morreau H, et al. The feasibility and reliability of sentinel node mapping in colorectal cancer. *Eur J Oncol Soc* 2005;31:854–62.
26. Tuech JJ, Pessaux P, Regenet N, Bergamaschi R, Colson A. Sentinel lymph node mapping in colon cancer. *Surg Endosc* 2004;18:1721–9.
27. Kitagawa Y, Watanabe M, Hasegawa H, Yamamoto S, Fujii H, Yamamoto K, et al. Sentinel node mapping for colorectal cancer with radioactive tracer. *Dis Colon Rectum* 2002;45:1476–80.
28. Wainstein AJA, Barroso AA, Belfort AF. Significance of sentinel lymph node in cancer of the digestive tract. *Topics in gastroenterology* 14. Publisher Medsi, Rio de Janeiro, RJ, 2004.
29. Steenbergen LN, van Lijnschoten G, Rutten HJ, Lemmens VE, Coebergh JW. Improving lymph node detection in colon cancer in community hospitals and their pathology department in southern Netherlands. *Eur J Surg Oncol*, 2010;36:135–40.
30. Paraf F, Sabourin JC. Optimal lymph node number and occult lymph node metastases in colorectal cancer: the pathologists view. *Gastroenterol Clin Biol* 2000;24:423–59.
31. Tschmelitsch J, Klimstra DS, Cohen AM. Lymph node micrometastases not predict relapse in stage II colon cancer. *Ann Surg Oncol*, 2000;7:601–8.
32. Cohen AM, Tremitterra S, Candeh F. Adjuvant therapy for colorectal cancer. *Curr Prob Cancer* 1998;22:5–65.
33. Codignola C, Zorzi F, Zaniboni A, Mutti S, Rizzi A, Padolecchia E, et al. Is there any role for sentinel node mapping in colorectal cancer staging? Personal experience and review of the literature. *Jpn J Clin Oncol* 2005;35:645–50.
34. Bembenek AE, Schneider U, Gretschel S, Fisher J. Detection of lymph node micrometastases and isolated tumor cells in sentinel and nonsentinel lymph nodes of colon cancer patients. *World J Surg* 2005;29:1172–5.
35. Bendavid Y, Latulippe M, Younan RJ, Leclerc YE, Dube S, Heyen F, et al. Phase I study on sentinel lymph node mapping in colon cancer: a preliminary report. *J Surg Oncol* 2002;79:81–4.