



Journal of Coloproctology

www.jcol.org.br



Original Article

Vermiform appendix: positions and length – a study of 377 cases and literature review



Sandro Cilindro de Souza^{a,b,*}, Sérgio Ricardo Matos Rodrigues da Costa^{c,d},
Iana Gonçalves Silva de Souza^b

^a Instituto Médico-Legal de Feira de Santana, Secretaria de Segurança Pública do Estado da Bahia, Salvador, BA, Brazil

^b Department of Anatomy, Faculdades Adventistas da Bahia, Capoeiruçu, BA, Brazil

^c Instituto Médico-Legal Nina Rodrigues, Secretaria de Segurança Pública do Estado da Bahia, Salvador, BA, Brazil

^d Center for Health Sciences, Universidade Federal da Bahia, Salvador, BA, Brazil

ARTICLE INFO

Article history:

Received 21 June 2015

Accepted 15 August 2015

Available online 25 September 2015

Keywords:

Vermiform appendix

Cecum

Anatomical variation

Appendicitis

ABSTRACT

Objective: Evaluation of the frequency of the relative positions and length of vermiform appendix in a group of corpses examined by the authors.

Method: Dissection of 377 adult cadavers autopsied.

Results and conclusions: Retrocecal: 43.5%; subcecal: 24.4% post-ileal: 14.3%, pelvic: 9.3%; paracecal: 5.8%; and pre-ileal appendices: 2.4%, other positions: 0.27%, mean length: 11.4 cm.

© 2015 Sociedade Brasileira de Coloproctologia. Published by Elsevier Editora Ltda. All rights reserved.

Apêndice vermiforme: posições e comprimento – estudo de 377 casos e revisão de literatura

RESUMO

Objetivo: Avaliação da frequência das posições relativas e do comprimento do apêndice vermiforme em um grupo de cadáveres examinados pelos autores.

Método: Dissecção de 377 cadáveres adultos necropsiados.

Resultados e conclusões: Apêndices retrocecais: 43,5%, subcecais: 24,4%, pós-ileais: 14,3%, pélvico: 9,3%, paracecais: 5,8%, pré-ileais 2,4%, outras posições: 0,27%. Comprimento médio: 11,4 cm.

© 2015 Sociedade Brasileira de Coloproctologia. Publicado por Elsevier Editora Ltda. Todos os direitos reservados.

Palavras-chave:

Apêndice vermiforme

Ceco

Variação anatômica

Appendicite

* Corresponding author.

E-mail: sandrocilin@gmail.com (S.C. de Souza).

<http://dx.doi.org/10.1016/j.jcol.2015.08.003>

2237-9363/© 2015 Sociedade Brasileira de Coloproctologia. Published by Elsevier Editora Ltda. All rights reserved.

Introduction

Vermiform appendix (from the Latin appendix: “dangling” + “vermis” + “form”, i.e.: “dangling worm-shaped thing”) is a diverticulum of the cecum and marks the beginning of the colon in the confluence of taenias. The appendix is posterior-medially attached to the cecum, about 2 cm below the ileocecal junction.^{1–6}

The position of the appendix is extremely variable – more than any other organ – and if it is too long, the appendix may extend to any part of the abdomen.^{1,3,7,8} Thus, as stated by Maingot,⁹ the appendix is the only organ in the body that has no fixed anatomy. Although nowadays this traditional principle is being questioned, it has its value, by emphasizing the fact that often the appendix is one of the most mobile viscera, although its lack of normal position is not in himself so extraordinary.¹⁰ Taking into account that often the appendix is a mobile structure, the medical importance of its relative position has been questioned by some authors.¹⁰ In general, however, some authors describe a significant relationship between its location and acute appendicitis.^{11,12} Signs and symptoms may show varying degree of discrepancy with the expected symptomatology, depending on the position of the appendix. For example, a pelvic appendicitis can reach the wall of the ureter and bladder, resulting in urinary symptoms. On the other hand, a retrocecal appendicitis can promote inflammation of the psoas major muscle and cause low back pain, lameness and pain with hip extension. A peri-ileal appendicitis, in turn, can trigger a diarrheal picture indistinguishable of that stemmed from gastroenteritis. Occasionally, the picture is so atypical that one can make a mistake with respect to a myriad of non-surgical intra-abdominal disorders^{11,13} and taking into account the great anatomical variability of the appendix, in the face of an episode of acute abdominal pain the doctor must regard appendicitis at least as a second suspicion.¹¹ In a retrocecal position, the blood vessels may be compressed and folded by the cecum. Thus, when an inflammation of the appendix occurs in this position, its blood supply may be compromised.⁸ Finally, a strong association has been established between hidden locations of the appendix (post-ileal, pelvic, retroperitoneal) and the development of an advanced appendicitis, resulting in longer hospital stays and in high incidence of gangrene and perforation.^{2,14,15} The knowledge of all these nuances can facilitate the establishment of a diagnosis, allowing an early treatment and minimizing the rate of complications from appendicitis. Therefore, the study of appendix positions has proven useful, even in our days.¹²

The aim of this study is to determine the position and length of the vermiform appendix in a group of corpses examined by the authors.

Materials and methods

This study was conducted from July 5, 2007 to February 6, 2014 in the Forensic Medicine Institutes of the cities of Salvador (Nina Rodrigues) and Feira de Santana (Bahia).

In this study, all adult cadavers examined directly by the authors during the usual necropsy evaluations were included.

The study excluded corpses with one or more of the following conditions: aged under 18 years, pregnancy (at necropsy), scars or sutures of laparotomy, intra-abdominal infection (localized or diffuse), partial or complete intestinal obstruction, gaseous distension of bowel loops, and decomposing corpses.

The abdomen was opened by a xifopubic midline incision. The vermiform appendix was located by simple exposure of the lower ileocecal recess or, in difficult cases, we followed the teniae to their junction at the apex of the cecum and base of the appendix.^{1,8,12} The appendix positions were defined as follows:^{1,8,12,16}

- Retrocecal/retrocolic: the appendix courses upwardly behind the cecum, and may reach the initial portion of the ascending colon;
- Pelvic: the appendix is directed downward, over the psoas major, with its tip surpassing the upper edge of the lower pelvis.
- Post-ileal: the distal portion of the appendix is in a position posterior-superior to the terminal ileum and directed to the spleen;
- Subcecal: the appendix is located under the cecum, resting on the right iliac fossa and separated from the iliac muscle by a local peritoneal lining;
- Pre-ileal: the distal portion of the appendix is located in a position anterior-superior to the terminal ileum and directed to the spleen;
- Paracecal position: the appendix is situated laterally to the cecum and ascending colon;
- Other (ectopic) positions: the appendix does not fit in any of the positions above described.

Results

377 appendices were studied. Of the whole group of corpses, 87.8% (N = 288) were male and 12.2% (N = 46), female. The age ranged from 18 to 89 years (mean = 33.6 years).

The corpses' weight ranged from 46.5 to 90.5 kg (mean = 69.5 kg). Their height ranged from 1.67 to 1.82 m (mean = 1.71 m). In descending order, the positions found for the appendix were as follows (Fig. 1): retrocecal: 43.5% (164), subcecal: 24.4% (92), post-ileal: 14.3% (54), pelvic: 9.3% (35) paracecal: 5.8% (22), pre-ileal: 2.4% (9), and other positions: 0.27% (1).

Most retrocecal appendices (98.8% – 162) were resting freely on the retrocecal recess. In only two cases (1.2%), the mesoappendix was absent and the appendix was completely adhered to the posterior wall of the cecum or ascending colon.

The appendix length ranged from 1.0 to 20.0 cm (mean = 11.4 cm).

Discussion

In the international literature, there is a wealth of studies on the position of the normal, inflamed or post-mortem appendix.^{16–18} For over a century the many contributions of

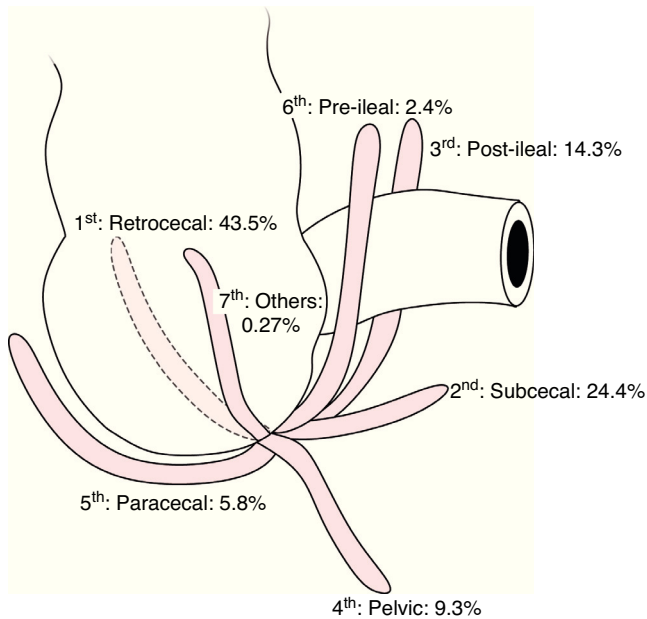


Fig. 1 – Positions of the vermiform appendix.

several authors have recorded hundreds of references under their appropriate subdivisions. No useful purpose has been achieved by repeating this huge amount of data.¹⁹ Therefore, the references reviewed in the current study were purposely limited, and are summarized in [Table 1](#).

The largest series documented in the literature studied were 4680,¹⁹ 10,000¹ and 40,000¹³ appendices. In the study by Wakeley (10,000 cases),¹ the appendix was in retrocecal (65.28%), pelvic (31.01%), subcecal (2.26%), pre-ileal (1%) and post-ileal (0.4%) position. Subsequent anatomical and surgical studies in the literature (11 series until 1993) and data obtained by our group ([Table 1](#)) show considerable contradiction with respect to this classic study. Probably the authors have used different definitions and data collection methodology, or demographic variations occurred. Thus, comparisons between reports may be challenging or even impossible, thanks to lack of criteria uniformity. Given these disagreements, currently we are not sure yet about the defined percentages.^{5,17} However, in most reports the values of the most common positions (retrocecal and pelvic) provide reasonable approximations.¹²

In the most part, the records are based on autopsy findings. In these studies, the position most commonly found has been the retrocecal one, with an occurrence ranging from 18 to 65% of specimens.^{1,13-16,19,20} Consistent with these findings, in this study, we observed more often appendices in a retrocecal position (43.5%), and this finding was within the range reported by other researchers (18–65%). When previous reports were reviewed, it was found that the retrocecal position has been less frequent in African *versus* Caucasian populations.¹²

The position of the appendix is closely related to the development of the cecum. Although initially with its location under the liver, after the 10th week of intrauterine life the fetal intestine returns to the abdominal cavity, causing the cecum to gradually descend into the right iliac fossa, with a

counterclockwise twisting motion around its longitudinal axis. Simultaneously, the anterolateral wall of the cecum stretches and grows faster than the other parts, and this results in displacement of the appendix from its original position at the apex of the cecum, to an anteromedial position. During this process of cecal descent, the appendix can bend behind the cecum, and if at that time the development of peritoneal lining is occurring, the appendix will remain fixed in this retrocecal posture. On the other hand, if the appendix remain free and directed downward during the descent of the cecum, then the appendix will remain permanently as an organ with free mobility after its fixation to the colon.^{1,2,10,15,16} In adults, the appendix may be fixed in a retrocecal position by the fibrosis resulting from previous episodes of acute appendicitis.^{14,15} Therefore, in view of the extreme mobility of the appendix, and taking into account the fast and extensive changes in the surrounding parts, and also considering the position changes suffered by the appendix when following the cecal migration, it may be concluded that the appendix is subject to more or less intense accidental circumstances that will modify its final positioning and that are responsible for the various positions in which this organ is described.^{1,17} Gender, age, body posture changes, and varying degrees of cecal contraction have not been described as determinants of the position of the appendix.^{12,17}

In the current study, the 2nd and 3rd positions most common are the subcecal (24.4%) and post-ileal (14.3%) – an unexpected result, since in none of the reviewed studies such a high frequency was found ([Table 1](#)). These findings were attributed to the local characteristics of the study population, predominantly made up of mestizos of various ethnicities. In the subcecal position, the appendix is in a fully intraperitoneal condition. If inflamed, it can cause diffuse peritonitis. Thus, this position can be regarded as the most susceptible to complications.⁸ During embryonic development, further growth of the right wall of the cecum or a stronger torsion of the cecum and ascending colon can shift the base of appendix toward the ileo-cecal junction area, resulting in pre-ileal and, in extreme cases, post-ileal appendices.^{1,10,17}

In this series, the pelvic position was the fourth most frequent (9.3%). However, in most of the reviewed studies ([Table 1](#)) the pelvic position appears in the second place, and several authors describe this position as the most prevalent, especially in non-surgical cases and in older individuals.¹² The high frequency of pelvic appendices has been associated with the presence of the so-called genitomesenteric fold, which is a fold of peritoneum coursing vertically from the posterior face of the terminal ileum to the deep right inguinal ring or, in women, to the right ovary. The appendix, as it follows the cecum and turns up and to the left, must come into close proximity with this fold, and tends to be deflected downward, toward the pelvic cavity.^{1,5,17}

The mean size of the appendices described by the authors of this paper (11.4 cm) is within the range described in the international literature (8–12 cm). As to extremes of size, other researchers found a range of 0.3–33 cm.^{3-6,19,21} On average, the male vermiform appendix is 0.6–1 cm greater than that of women.¹⁹ In the studies reviewed by the authors ([Table 1](#)), no theory has been developed to explain the variation in appendix sizes.

Table 1 – Frequency of positions of the vermiform appendix by several authors.

Reference	n	Type	Length (mean)	Retrocecal	Subcecal	Pelvic	Pre-ileal	Post-ileal	Paracecal	Ectopic
Liertz, 1909 (abstract)	2.092		–	35%	9%	42.1%		13.9%	–	
Collins, 1932	4.680		8.21 cm	20.21%	1.24%	7.9%	Appendices with anterior location: 70.72%			–
Wakeley, 1933	10.000			65.28%	2.26%	31.01%	1.00%	0.4%	–	0.05%
Peterson, 1934	373	Post mortem		31%	–	42.2%		26.8%	–	
Shah, 1945	405			61.2%	3.7%	8.2%	Paracecal, paraileal and ectopic: 26.9%			
	186			30.1%	7%	34.9%	Paracecal, paraileal and ectopic: 28%			
Waas, 1959	266		–	35.3%	13%	24.1%	Paracecal, paraileal and ectopic: 28.6%			
Bailey, 1959 (abstract)	–	Post-surgical		74%	1.5%	21%	1%	5%	2%	–
Maisel, 1960	300	Post mortem		26.7%	5%	58%	1.3%	3.3%	–	
Collins, 1963	40.000	Post-surgical		25.95%			Appendices anterior to cecum: 74.05%			–
Solanke, 1970	125	Post mortem		38.4%	11.2%	31.2%	Paracecal, paraileal and ectopic: 19.2%			
Buschard, 1973	141 (Denmark)	Post-surgical and post mortem	9.91 cm	56.7%	2.1%	33.4%	7.8%		–	
Katzarski, 1979	93 (Czechoslovakia)	Post mortem	9.12 cm	44.1%	0	44.1%	11.8%		–	
	103		12 cm (♂) and 11.4 cm (♀)	20.3%	–	43.6%			–	
Williamson, 1981	481	Post-surgical	–	21.8%	–					
Ajmani, 1983	100	Post mortem	9.5 cm (♂) and 8.7 cm (♀)	58%	5%	23%	2%	10%	2%	–
Grunditz, 1983	247	Radiological	–	17%				–		
Ojeifo, 1989	548	Post-surgical and post mortem		45.07%	2.37%	25%	1.82%	14.78%	6.39%	4.74%

Agenesis of the appendix, double appendix and ectopic appendix have been reported at a frequency under 1%.^{12,15} The authors found only an ectopic appendix (0.27%) in a pre-cecal position.

The authors found no correlation between appendix length and position. This correlation has also not been established by other researchers.^{8,17,20}

Conclusions

In the present study, we obtained the following frequencies for appendix positions: retrocecal: 43.5%, subcecal: 24.4%, post-ileal: 14.3%, pelvic: 9.3%, paracecal: 5.8%, pre-ileal: 2.4%, other positions: 0.27%. The length ranged from 1.0 to 20 cm, with a mean of 11.4 cm.

Conflicts of interest

The authors declare no conflicts of interest.

REFERENCES

1. Wakeley CPG. The position of the vermiform appendix as ascertained by analysis of 10,000 cases. *J Anat.* 1933;67:277–83.
2. Zern JT. The apêndix: little, big trouble. *Del Med Jrl.* 1995;67:326–34.
3. Ellis H. *Clinical anatomy: a revision and applied anatomy for clinical students.* 9th ed. Oxford: Blackwell Science; 1997.
4. Volg AW, Mitchel AWM. *Gray's anatomy for students.* 2nd ed. Philadelphia: Elsevier; 2010.
5. Gray H. *Gray's anatomy.* 37th ed. London: Churchill Livingstone; 1989.
6. Monkhouse S. *Master medicine: clinical anatomy.* Kidlington: Elsevier; 2001.
7. Treves F. Lectures on the anatomy of the canal intestinal and peritoneum in man. *Brit Med J.* 1835;1:527–30.
8. Ajmani ML, Ajmani K. The position and arterial supply of vermiform appendix. *Anat Anz.* 1983;153:369–74.
9. Maingot R. *Postgraduate surgery, vol. 1.* D. Appleton Century Co.; 1938.
10. De Garis CF. Topography and development of the cecus and appendix. *Ann Surg.* 1941;113:540–8.
11. Courtney MT, et al. *Sabiston: tratado de cirurgia.* 17th ed. Rio de Janeiro: Elsevier; 2005.
12. Ojeifo JO, Ejiwunmi AB, Iklaki J. The position of the vermiform appendix in Nigerians with a review of the literature. *West Afr J Med.* 1989;8:198–204.
13. Collins DC. 71,000 human appendix specimens: a final report summarizing forty years' study. *Am J Proctol.* 1963;14:365–81.
14. Collins DC. Acute retrocecal appendicitis. *Arch Surg.* 1938;36:729–43.
15. Williamson WA, Bush RD, Williams LF. Retrocecal appendicitis. *Am J Surg.* 1981;141:507–9.
16. Maisel H. The position of the human vermiform appendix in fetal and adult age groups. *Anat Rec.* 1960;136:385–91.
17. Buschard K, Kjaeldgaard A. Investigation and analysis of the position, fixation, length and embryology of the vermiform appendix. *Acta Chir Scan.* 1973;139:293–8.
18. Karim OM, Boothroyd AE, Wyllie JH. McBurney's point – fact or fiction. *Ann R Coll Surg Engl.* 1990;72:304–8.
19. Collins DC. The length and positions of the vermiform appendix – a study of 4,680 specimens. *Ann Surg.* 1932;96:1044–8.
20. Grunditz T, Rydén CY, Janzon Lars. Does the retrocecal position influence the course of acute appendicitis. *Acta Chir Scand.* 1983;149:707–10.
21. Katzarski M, Gopal Rao UK, Brady K. Blood supply and position of the vermiform appendix in Zambians. *Med J Zambia.* 1979;13:32–4.