



Journal of Coloproctology

www.jcol.org.br



Original Article

Minimal abdominal incisions



João Carlos Magi^{a,b,*}, Bruna Fernandes dos Santos^{a,b}, Lucas Rodrigues Boarini^{a,b},
Pietro Dadalto de Oliveira^{a,b}, Galdino José Sitonio Formiga^{a,b}

^a Hospital Heliópolis, Serviço de Coloproctologia, São Paulo, SP, Brazil

^b Sociedade Brasileira de Coloproctologia (SBCP), Rio de Janeiro, RJ, Brazil

ARTICLE INFO

Article history:

Received 24 October 2016

Accepted 18 December 2016

Available online 3 February 2017

Keywords:

Minimal incision surgery

Minilaparotomy

Minimally invasive procedures

Transit reconstruction

ABSTRACT

Minimally invasive procedures aim to resolve the disease with minimal trauma to the body, resulting in a rapid return to activities and in reductions of infection, complications, costs and pain. Minimally incised laparotomy, sometimes referred to as minilaparotomy, is an example of such minimally invasive procedures. The aim of this study is to demonstrate the feasibility and utility of laparotomy with minimal incision based on the literature and exemplifying with a case. The case in question describes reconstruction of the intestinal transit with the use of this incision. Male, young, HIV-positive patient in a late postoperative of ileotiflectomy, terminal ileostomy and closing of the ascending colon by an acute perforating abdomen, due to ileocolonic tuberculosis. The barium enema showed a proximal stump of the right colon near the ileostomy. The access to the cavity was made through the orifice resulting from the release of the stoma, with a lateral-lateral ileo-colonic anastomosis with a 25 mm circular stapler and manual closure of the ileal stump. These surgeries require their own tactics, such as rigor in the lysis of adhesions, tissue traction, and hemostasis, in addition to requiring surgeon dexterity – but without the need for investments in technology; moreover, the learning curve is reported as being lower than that for videolaparoscopy. Laparotomy with minimal incision should be considered as a valid and viable option in the treatment of surgical conditions.

© 2017 Published by Elsevier Editora Ltda. on behalf of Sociedade Brasileira de Coloproctologia. This is an open access article under the CC BY-NC-ND license (<http://creativecommons.org/licenses/by-nc-nd/4.0/>).

Incisões abdominais mínimas

RESUMO

Procedimentos minimamente invasivos visam resolver a doença com o mínimo de trauma ao organismo, resultando em retorno rápido às atividades, reduções nas infecções, complicações, custos e na dor. A laparotomia com incisão mínima, algumas vezes referida como minilaparotomia, é um exemplo desses procedimentos minimamente invasivos. O objetivo deste trabalho é demonstrar a viabilidade e utilidade das laparotomias com incisão mínima com base na literatura e exemplificando com um caso. O caso descreve uma

Palavras-chave:

Cirurgia com incisão mínima

Minilaparotomia

Procedimentos minimamente invasivos

Reconstrução de trânsito

* Corresponding author.

E-mail: joao.magi@ig.com.br (J.C. Magi).

<http://dx.doi.org/10.1016/j.jcol.2016.12.005>

2237-9363/© 2017 Published by Elsevier Editora Ltda. on behalf of Sociedade Brasileira de Coloproctologia. This is an open access article under the CC BY-NC-ND license (<http://creativecommons.org/licenses/by-nc-nd/4.0/>).

reconstrução de trânsito intestinal com o uso desta incisão. Paciente masculino, jovem, HIV-positivo, pós-operatório tardio de ileotiflectomia, ileostomia terminal e fechamento do cólon ascendente por abdome agudo perfurativo devido a uma tuberculose íleo-colônica. Enema opaco mostrava coto proximal do cólon direito próximo da ileostomia. O acesso à cavidade foi feito através do orifício resultante da liberação do ostoma-realização de anastomose íleo-colônica látero-lateral com grampeador circular de 25 mm e fechamento manual do coto ileal. Estas cirurgias exigem táticas próprias, como rigor na lise de aderências, tração dos tecidos e hemostasia, além de demandar destreza do cirurgião; contudo, sem necessidade de investimentos em tecnologia e, além disso, a curva de aprendizado é relatada como menor que a da videolaparoscopia. A laparotomia com incisão mínima deve ser considerada como opção válida e viável no tratamento de afecções cirúrgicas.

© 2017 Publicado por Elsevier Editora Ltda. em nome de Sociedade Brasileira de Coloproctologia. Este é um artigo Open Access sob uma licença CC BY-NC-ND (<http://creativecommons.org/licenses/by-nc-nd/4.0/>).

Introduction

Minimally invasive procedures are performed to resolve the disease with minimal trauma to the body. The benefits are lower infection and complication rates, lower costs, less pain, a faster return to activities and, especially in laparotomies with minimal incisions, less scarring and, thus, a better esthetic result.^{1,2}

With a good indication and in experienced hands, laparotomies (from the Greek: *laparos* = abdomen, *tomos* = cut) with minimal incisions are beneficial for the patient. The minilaparotomy for tubal ligation, described in the last century, is an example of these procedures.³ In addition to improving surgical procedures, advances in technology have enabled the surgeon to make more accurate diagnoses, as well as to show greater confidence in the procedure to be performed, with an increasing use of laparotomies with minimal incisions.⁴ The aim of this study is to demonstrate the feasibility and utility of the laparotomy with minimal incision, based on the literature and on the case reported.

Case report

Male, 27-year-old, brown-colored patient. For the past four years, he has been diagnosed with HIV and ileocolonic tuberculosis after an exploratory laparotomy with ileotiflectomy, terminal ileostomy and ascending colon closure due to an acute perforating abdomen, with clinical instability and diffuse peritonitis. Also with a history of mild asthma, controlled since childhood. In the outpatient follow-up, the patient started a treatment for intestinal tuberculosis and regular antiretroviral therapy with the infectology team. A year ago, he underwent a laparotomy due to an obstructive acute abdomen due to adhesions. In June 2016, the patient was referred to the Service to perform a reconstruction of the intestinal transit, after compensation of his clinical diseases. On physical examination, we observed overweight, a globose abdomen, a median xiphobic scar with a 15-cm wide incisional hernia throughout the surgical incision, and an ileostomy in his right flank without prolapse or herniations. Additional examinations were performed: a rectal colonoscopy up to the right

colon with a blind bottom, with normal mucosa, and a barium enema that revealed a proximal stump of the right colon near the ileostomy (Fig. 1).

During the inventory, a lot of firm adhesions were found between the loops and with a hernia and the wall, making difficult the access. Adhesions of a sufficient segment of the ileum and colon were dislodged, in order to perform the anastomosis. Next, we performed a lateral-lateral ileo-colonic anastomosis with a 25-mm circular stapler and with a manual closure of the ileal stump (Fig. 2).

Despite the elimination of flatus on the first postoperative day and the presence of liquid stools on the second day, the patient presented a subocclusive condition, with abdominal distension and nausea, necessitating the passage of a nasogastric tube, fasting, and hydration for 48 h. Clinically, the patient recovered uneventfully after conservative treatment and was discharged on the seventh postoperative day (Fig. 3). The patient returned to his usual activities 30 days after surgery and was asymptomatic at outpatient follow-up.

Discussion

In comparison to the main surgical time, the incisions of access to the abdominal cavity can cause a bigger trauma. After the advent of the videolaparoscopic surgeries and the publication of studies related to the surgical trauma caused by the abdominal wall opening, it was demonstrated that the larger the incision, the greater the morbidity. Thus, conceptions such as “large incisions, great surgeons” are no longer universally accepted.¹ An example of the use of minimal incisions in laparotomies is the reconstruction of the intestinal transit, in which the orifice resulting from stoma release is used as an intra-abdominal access in those cases where the surgeon is able to reach the closed loop for the anastomosis. Another example is the removal of colon tumors, where the incision is large enough for the removal of the piece and for the introduction of a hand, for the inventory of the cavity.^{5,6} These surgeries require their own tactics and techniques, for example, how to fix the compresses and to make the inventory, and also some rigor in the lysis of the adhesions, traction of the tissues and hemostasis. Therefore, these procedures are

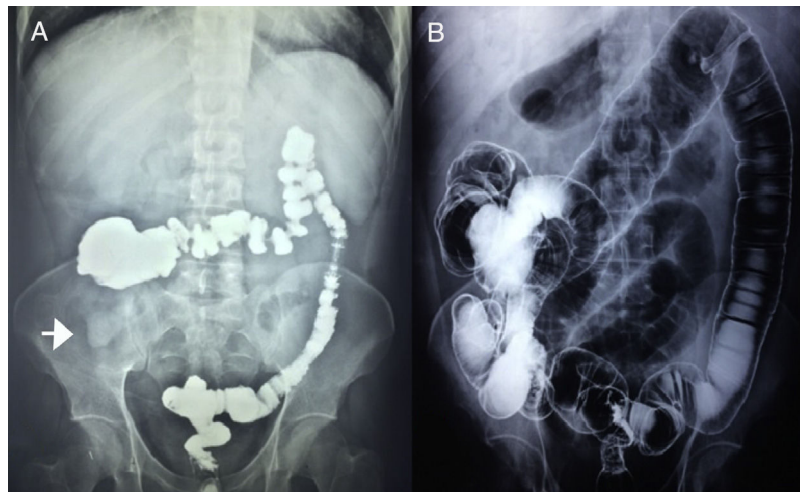


Fig. 1 – Barium enema before (A) and after (B) intestinal transit reconstruction (ITR). Arrow, ostomy.

not just a miniature of a traditional laparotomy, but indeed constitute another type of surgery.

Laparotomy with minimal incision is considered a minimally invasive procedure. This type of procedure only requires the dexterity of the surgeon, who uses traditional surgical instruments; thus, there is no need for more investments to aggregate technology with new equipment. There is indeed a learning curve; however, authors report that it is smaller than that for videolaparoscopy, since, besides the instrumental factor, one has a direct vision of the cavity and a tactile perception.^{2,3}

Compared with traditional laparotomies, minimally incisional surgeries cause less surgical trauma and entail lower hospital costs. Regarding videolaparoscopy, these surgeries

may be indicated in situations showing a large amount of firm intra-abdominal adhesions, since these are responsible for the main cause of conversion in laparoscopic surgery. They also do not differ in the final esthetic result, compared to the laparoscopic route, because they do not add new scars, in addition to the primary scar.^{7,8}

According to Souza et al., in the treatment of chagasic megacolon, better statistical results were obtained with “minilaparotomy” in terms of surgical time, the need for post-operative analgesia, the beginning of an oral diet, time of passage of flatus and length of hospital stay versus videolaparoscopic surgery.⁹

Thus, in addition to requiring less aggregate technology, having a lower cost and requiring less training, minimally

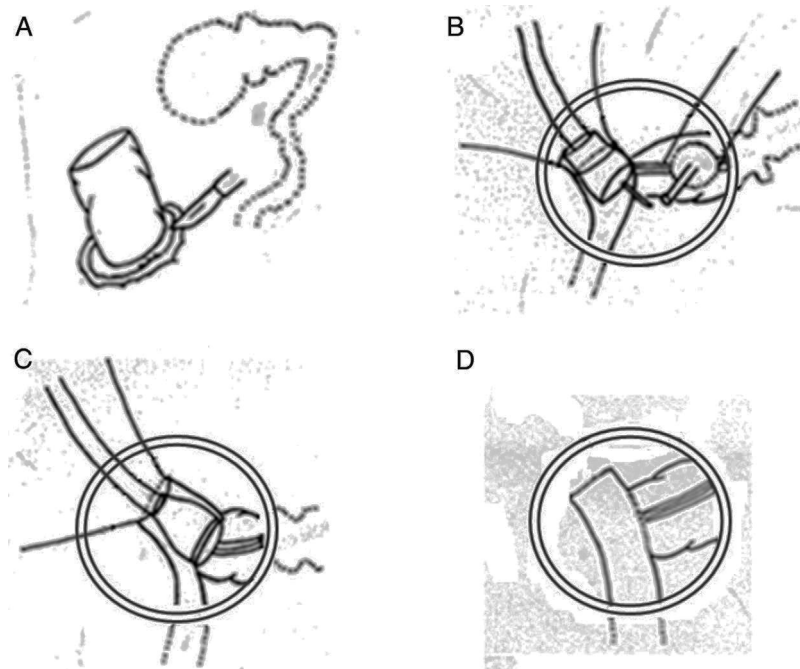


Fig. 2 – Graphic scheme. The sequence of the transit reconstruction technique used: A, stoma release; B, placement of stapler ogives; C, lateral-lateral ileo-colonic anastomosis; D, final appearance of the anastomosis.

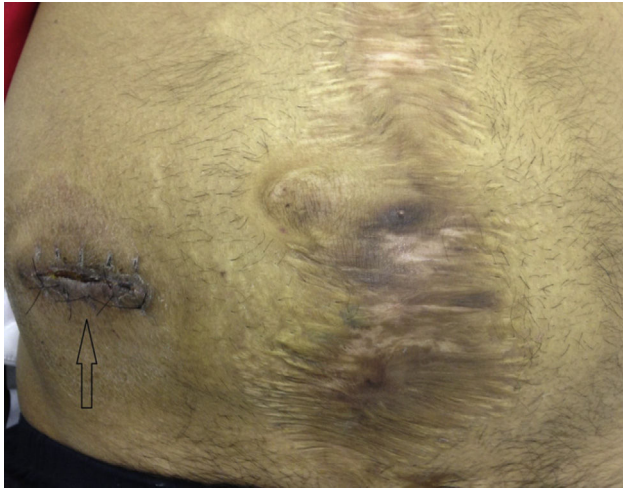

Fig. 3 – Final appearance of the abdomen. Arrow, ITR incision.

incised surgeries are a good choice in some situations, such as in the reconstruction of intestinal transit, as an alternative to videolaparotomy, which present a very varied incidence in the literature with regard to conversion rates in the presence of large numbers of firm intra-abdominal adhesions, as in the case described in this paper.⁸

Conclusion

Laparotomy techniques with minimal incisions should be considered as a valid and viable option in the treatment of surgical conditions.

Conflicts of interest

The authors declare no conflicts of interest.

REFERENCES

1. Ferraz ED, Lacombe D. Estado atual da cirurgia híbrida colo-retal. *Rev Bras Vídeo-cir.* 2003;1:29–37.
2. Carvalho ACM, Oliveira IAN, Dantas ANM, Silva CRB, Arize L, Guerra JC, et al. Estudo Comparativo entre a Laparotomia Longitudinal Mediana Infraumbilical e a Minilaparotomia Oblíqua na Fossa Ilíaca Esquerda, no Tratamento Cirúrgico do Megacólon Chagásico. *Rev Bras Coloproct.* 2002;22:290–5.
3. Pinedo A. Minilaparotomia de intervalo. *Ginecol Obstet Perú.* 1997;43:96–101.
4. Brown SR, Eu KW, Seow-Choen F. Consecutive series of laparoscopic assisted vs. minilaparotomy restorative proctocolectomies. *Dis Colon Rectum.* 2001;44:397–400.
5. Nakagoe T, Sawai T, Tsuji T, Ayabe H. Use of minilaparotomy in the treatment of colonic cancer. *Br J Surg.* 2001;88:831–6.
6. Ishida H, Nakada H, Yokoyama M, Hayashi Y, Ohsawa T, Inokuma S, et al. Minilaparotomy approach for colonic cancer: initial experience of 54 cases. *Surg Endosc.* 2005;19:316–20.
7. Richardson WS, Carter KM, Fuhrman GM, Bolton JS, Bowen JC. Minimally invasive abdominal surgery. *Ochsner J.* 2000;2:153–7.
8. Regadas FSP, Regadas SMM, Rodrigues LM, Santos e Silva FR, Regadas Filho FSP. Reconstituição do trânsito intestinal por videolaparoscopia após operação de Hartmann. Avaliação pré-operatória, técnica e resultados. *Rev Bras Coloproct.* 2003;24:281–6.
9. Souza JVS, Carmel APW, Martins G, Souza MMB, Silva MMFM. Colectomia laparoscópica versus minilaparotomia: estudo comparativo. *Rev Bras Coloproctol.* 1997;17:11–4.