



Journal of Coloproctology

www.jcol.org.br



Original Article

Postoperative outcomes and functional results after Deloyer's procedure – a retrospective cohort study



Noel Salgado-Nesme^{a,*}, Omar Vergara-Fernández^a, David Mitre-Reyes^a,
Hugo A. Luna-Torres^a, Juan Francisco Molina-López^a, Adolfo Navarro-Navarro^a,
Jorge Guevara-Chipolini^b

^a Instituto Nacional de Ciencias Médicas y Nutrición “Salvador Zubirán”, Departamento de Cirugía Colorrectal, Mexico City, Mexico

^b Universidad La Salle, Facultad Mexicana de Medicina, Mexico City, Mexico

ARTICLE INFO

Article history:

Received 9 November 2016

Accepted 15 February 2017

Available online 7 March 2017

Keywords:

Procedure

Extended left hemicolectomy

Isoperistaltic transposition

Low colorectal anastomosis

Hartmann's procedure

ABSTRACT

Introduction: The objective of our study was to describe surgical outcomes of Deloyers procedure in our referral center, and to compare the results of patients with and without protective ileostomy.

Methods: Patients undergoing a Deloyers procedure from 2013 to 2016 were prospectively included. General characteristics, intraoperative variables, postoperative course, and functional outcomes were analyzed. Patients were compared into two groups: group (1) patients undergoing Deloyers procedure without ileostomy, and group (2) Deloyers procedure with protective ileostomy.

Results: Sixteen patients undergoing isoperistaltic transposition of the right colon remnant were included, of which 9 (63%) were males with a median age of 47 (range 22–76) years. The main surgical indication was the restoration of bowel transit (62.5%). There was higher major morbidity rate in the Deloyers procedure with protective ileostomy group, but without statistical significance (20% vs. 9%, $p=0.92$). No leaks or deaths were reported. The length of hospital stay was 7 days. The mean number of bowel movements per day was 4 at 18 months of follow up. Only four (25%) patients used irregularly loperamide.

Conclusions: The Deloyers procedure has satisfactory results and is reproducible with low morbidity. The major and minor morbidity rates were similar between groups, suggesting that the costs and risks of a second procedure can be avoided by providing a safe primary anastomosis.

© 2017 Sociedade Brasileira de Coloproctologia. Published by Elsevier Editora Ltda. This is an open access article under the CC BY-NC-ND license (<http://creativecommons.org/licenses/by-nc-nd/4.0/>).

* Corresponding author.

E-mail: noelsalgadonesme@gmail.com (N. Salgado-Nesme).

<http://dx.doi.org/10.1016/j.jcol.2017.02.002>

2237-9363/© 2017 Sociedade Brasileira de Coloproctologia. Published by Elsevier Editora Ltda. This is an open access article under the CC BY-NC-ND license (<http://creativecommons.org/licenses/by-nc-nd/4.0/>).

Desfechos pós-operatórios e resultados funcionais após o procedimento de Deloyer – um estudo de coorte retrospectivo

R E S U M O

Palavras-chave:

Procedimento
Hemicolectomia extensa à esquerda
Transposição isoperistáltica
Anastomose colorretal baixa
Procedimento de Hartmann

Introdução: O objetivo de nosso estudo foi descrever os resultados cirúrgicos do procedimento de Deloyer em nosso centro de referência e comparar os resultados de pacientes com e sem ileostomia de proteção.

Métodos: Pacientes submetidos ao procedimento de Deloyer de 2013 a 2016 foram incluídos prospectivamente. Foram analisadas as características gerais, as variáveis intraoperatórias, o curso pós-operatório e os desfechos funcionais. Os pacientes foram comparados em dois grupos: Grupo 1) pacientes submetidos ao procedimento de Deloyer (PD) sem ileostomia, e grupo 2) procedimento de Deloyer com ileostomia de proteção (IP).

Resultados: Foram incluídos 16 pacientes submetidos à transposição isoperistáltica da porção remanescente do cólon direito, dos quais 9 (63%) eram do sexo masculino com idade média de 47 anos (variação de 22-76) anos. A principal indicação cirúrgica foi a restauração do trânsito intestinal (62,5%). Houve maior morbidade maior no grupo IP, mas sem significância estatística (20% vs. 9%, $p=0,92$). Nenhum vazamento ou óbito foi relatado. A duração da hospitalização foi de 7 dias. O número médio de evacuações por dia foi 4, aos 18 meses de seguimento. Apenas quatro (25%) pacientes utilizaram irregularmente a loperamida.

Conclusões: O procedimento de Deloyer tem resultados satisfatórios e é reprodutível com baixa morbidade. As taxas de morbidades maiores e menores foram semelhantes entre os grupos, sugerindo que os custos e riscos de um segundo procedimento podem ser evitados proporcionando-se uma anastomose primária segura.

© 2017 Sociedade Brasileira de Coloproctologia. Publicado por Elsevier Editora Ltda. Este é um artigo Open Access sob uma licença CC BY-NC-ND (<http://creativecommons.org/licenses/by-nc-nd/4.0/>).

Introduction

The vast majority of patients suffering from complicated diverticular disease in Latin America are subjected to a Hartmann's procedure (sigmoid colon removal with descending colon colostomy and rectal stump). Sometimes, reconstruction of bowel transit becomes a difficult procedure because a wide resection or own extension of the middle colic artery prevents a tension-free anastomosis.

Deloyers procedure, described by the author in 1964,¹ is the first reference of the art and has since been mentioned infrequently in the management of chronic or Hirschsprung constipation.^{2,3} Some articles highlighting the importance of this procedure as a safe alternative for the reconstruction of bowel transit after an extended left hemicolectomy have been published in the last decade.

The objective of our study was to analyze postoperative and functional outcomes in a series of patients undergoing a Deloyers procedure, and to compare the results of patients with and without protective ileostomy.

Patients and methods

Patients undergoing a Deloyers procedure were prospectively included from February 2013 to March 2016 in a referral center. Monitoring, demographic, and intraoperative variables were compared according to two groups: patients undergoing

Deloyers procedure (DP) without protective ileostomy vs. Deloyers procedure with protective ileostomy (PPI).

Operative mortality was defined as those that occurs within 30 days of the procedure. Postoperative morbidity was included in the Clavien-Dindo classification system.⁴ Complications were classified as minor (Clavien-Dindo Grade < III) or major (\geq Clavien-Dindo Grade III, IV and V). The presence of anastomotic leak was suspected by clinical systemic inflammatory response and confirmed with contrast-enhanced computed tomography.

A descriptive and comparative analysis was performed. For continuous variables, the mean, standard deviation, median, ranges, and the rate in percentage points of other variables obtained in each group were determined. Comparison between groups were estimated with the chi-square, Fisher's exact probability test or the Student's t-test for categorical and continuous variables, respectively. A p -value of 0.05 or less was considered statistically significant. All statistical analyses were carried out using IBM SPSS Statistics (version 23.0).

Surgical technique

All procedures were performed using an open approach. The procedure starts once the previous adhesions have been released. After the location of the left ureter, the first step is the dissection of the rectum. In all cases, rectal stump removal was performed for proper irrigation at both ends of the anastomosis. After the dismantling of the colostomy, mobilization of the right colon is made by releasing it of Toldt's fascia; as

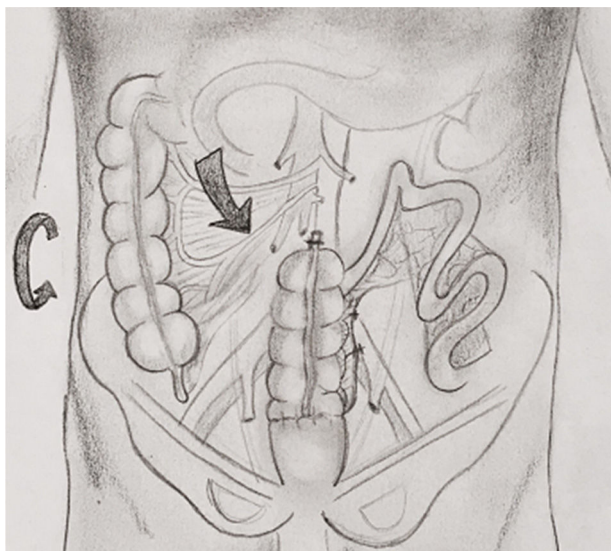


Fig. 1 – Anticlockwise rotation in Deloyers procedure.

well as the colonic flexure and the portion of transverse colon on the gastrocolic ligament; fully respecting the mesocolon. Once the colon has been released, the right branch of the middle colic artery is identified and sectioned at its root, as well as the right colic artery (in case of being present and by decision of the surgeon). The colon, is resected in the portion where a visible and palpable pulse of the ileocecal vessels is identified. The peritoneal fold is released at the level of the ileocecal valve with release of the terminal portion of the ileum and cecum. It proceeds to release the mesocolon from the lower edge of the duodenum to the base of the ileocecal vessels. If the cecal appendix is preserved, appendectomy is made using a cutting linear stapler. The origin of the superior mesenteric artery should be identified, and after the complete mobilization of mesocolon, it rotates counter clockwise ensuring that there is no twisting of ileocaecal vessels (Fig. 1). The anvil of the circular stapler is placed in the terminal portion of the ascending colon; stapler is introduced transanally and end-end anastomosis is made using a double-staple technique (Fig. 2). A hydropneumatic test is performed, and drain closed to the rear face of the anastomosis is placed. For patients with protective ileostomy, an ileal handle is externalized to 30 cm from the ileocecal valve on the right to the umbilicus. The ileostomy closure was scheduled at 8 weeks or at the end of adjuvant chemotherapy if necessary.

Results

During this study, sixteen patients underwent isoperistaltic transposition of the right colon remnant with colorectal anastomosis (CRA) or coloanal anastomosis (CAA). In total, 9 (56%) males were included. The median age was 47 years (range 22–76). Eleven patients were included in the DP group (68%). No differences were found between both groups in terms of age, sex, score of the American Society of Anesthesiologists (ASA), body mass index, and the number of comorbidities (Table 1).

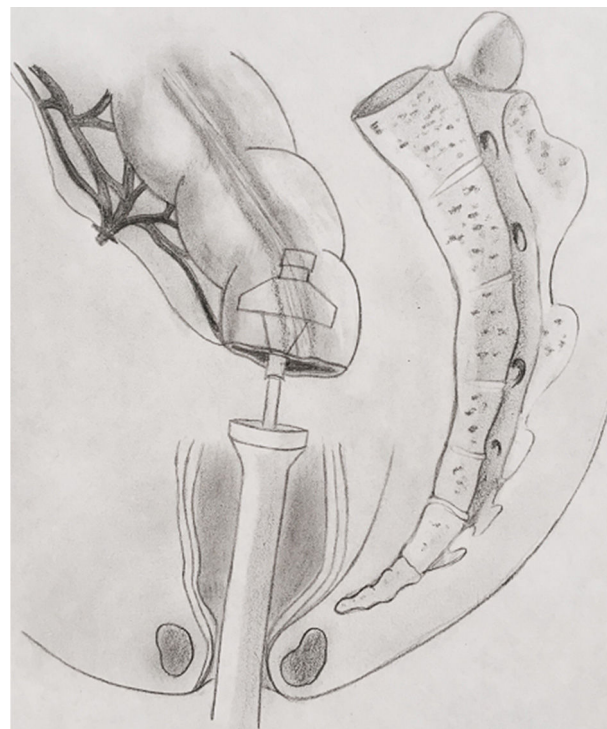

Fig. 2 – End to end colorectal anastomosis.

Comorbidity

Charlson index was slightly higher in the group without ileostomy (1.8 vs. 1.6; $p=0.04$). Two patients with Lupus Erythematosus were included in primary anastomosis group. Both patients had chronic steroid use (20 mg/day). During the surgical procedure, an adequate irrigation and free-tension

Table 1 – Preoperative data.

| Variable | Deloyers (n = 11) | PPI (n = 5) | p |
|------------------------------------|---------------------|---------------------|------|
| Gender | | | 0.36 |
| Male | 7 (63%) | 2 (40%) | |
| Age | 41.7 (± 16.6) | 59.8 (± 17.9) | 0.74 |
| ASA I-II | 7 (63%) | 3 (60%) | 0.38 |
| ASA II-IV | 4 (36%) | 2 (40%) | |
| BMI (kg/m ²) | 25.9 (± 8.3) | 26.7 (± 7.7) | 0.93 |
| Charlson index | 1.8 (± 2.2) | 1.6 (± 1.1) | 0.04 |
| Diverticular disease | 4 (36%) | 4 (80%) | 0.14 |
| Colon cancer location: | | | |
| Splenic flexure | 2 (18%) | 0 | |
| Left colon | 1 (9%) | | |
| Transverse colon | 1 (9%) | | |
| Appendicitis | | | |
| Incidental injury | 1 (9%) | 0 | 0.45 |
| GSW | 1 (9%) | 0 | 0.45 |
| Perforated intestinal tuberculosis | 0 | 1 (20%) | 0.54 |

PPI, Deloyers procedure + protective ileostomy; BMI, body mass index; GSW, gunshot wound.

Table 2 – Operative results.

| Variables | Deloyers (n = 11) | PPI (n = 5) | p |
|------------------------------|-------------------|-------------|------|
| Operative time (min) | 312 (±108) | 324 (±39) | 0.06 |
| Blood loss (ml) | 350 (±263) | 290 (±134) | 0.6 |
| Type of anastomosis | | | |
| CRA | 10 (90%) | 4 (80%) | 0.54 |
| CAA | 1 (10%) | 1 (20%) | |
| Right colic artery preserved | | | |
| Yes | 2 (18%) | 3 (60%) | 0.26 |
| No | 9 (82%) | 2 (40%) | |

PPI, deloyers procedure + protective ileostomy; CRA, colorectal anastomosis; CAA, coloanal anastomosis.

anastomosis was performed. Both patients had no severe postoperative complications.

Surgical indications

The main indication for the procedure was the restoration of bowel transit in 10 patients (62.5%). Hartmann's procedure was initially performed for complicated diverticular disease in 8 patients, for perforated intestinal tuberculosis in 1 patient, and for incidental colonic injury in 1 patient (Table 1). Four patients (25%) with cancer were included: 2 (12.5%) patients with locally extended tumor in the left colic flexure; 1 (6.2%) patient with transverse colon cancer; and 1 patient with a history of extended left colectomy for cancer, who required an iterative resection for recurrence of the tumor. One patient with complicated appendicitis and inflammatory phlegmon with involvement of sigmoid, and another patient with a history of trauma by firearm that required resection of multiple intestinal segments were included.

Intraoperative features

The types of anastomosis performed in both groups were CRA (n = 14) and CAA (n = 2). The ligation of the right colic artery was performed in 11 patients (68.7%) according to the surgeon's preference. The operative time between two groups was similar (312 vs 324 min), and intraoperative bleeding was slightly higher in the DP group (350 vs. 290 ml) (Table 2). Three (18.75%) patients were transfused during surgery with one red blood cells packed per patient. The suction drainage was removed on 12 day (6–30).

Postoperative follow-up

Postoperative outcomes

The length of hospital stay was 7 days (5–57). The postoperative mortality was null. Half of the patients had complications. Major morbidity (Clavien-Dindo ≥ 3) was more frequent in the ileostomy group (20% vs. 9%, $p=0.92$). There was one patient with a presacral fluid collection in each group. Both patients were treated with percutaneous drainage and antibiotics. Minor morbidity (Clavien-Dindo < 3) was similar in both groups (40% vs. 36%, $p=0.92$) and it was related to superficial surgical site infections (Table 3). No patient underwent a surgical reoperation.

Table 3 – Morbidity.

| Morbidity | Deloyers (n = 11) | PPI (n = 5) | p |
|-----------------------------|-------------------|-------------|------|
| Clavien-Dindo \leq II | 4 | 2 | |
| Surgical site infections | (36%) | (40%) | 0.92 |
| Clavien-Dindo \geq III | 1 | 1 | |
| Presacral fluid collections | (9%) | (20%) | |

PPI, Deloyers procedure + protective ileostomy.

Late morbidity

One patient (6.2%) with CAA and protective ileostomy developed stenosis. This was treated with Hegar dilators. No complications were found after ileostomy closure.

Morbidity at stoma closure

Ileostomy closure was performed in all patients (n = 5). The mean time period for ileostomy closure was 4 months (range, 1–6). A barium enema was before closure. Two patients had minor morbidity (1 surgical site infection, and 1 incisional hernia). And there were not major complications.

Functional result

The follow-up period was 18 months (4–38). The mean number of bowel movements per day was 4 (range, 2–10). One patient with CAA had fecal urgency. No incontinence was reported.

Four (25%) patients were taking 2 mg of loperamide per day, with a mean number of bowel movements of 4 per day.

Discussion

The representative works of this procedure by Deloyers and Manceau^{1,5} in 1964 and 2012 respectively, have shown that the Deloyers procedure provides a low morbidity and adequate long-term functional outcome.

Intestinal reconstruction generally represents a complex procedure, as a well-vascularized and free-tension anastomosis should be ensured. Such aspects are difficult to achieve when performing an extensive resection of the left colon. Keeping in mind the above, most surgeons prefer to perform an ileorectal anastomosis (IRA); however, the number and consistency of bowel movements is usually a problem.^{6,7} Deloyers procedure is the intestinal reconstruction by isoperistaltic colonic transposition of the right colon ramment for a CRA or CAA. Theoretically, the advantage of this procedure is the preservation of the ileocecal valve and therefore a slower emptying from the small intestine to the fragment of the remaining colon and rectum, which can result in a lower number of bowel movements, better consistency^{8,9} and greater absorption of water, sodium, and vitamin B12 compared to an ileorectal anastomosis.^{10–12} In our series of patients, there was no evidence of ileocolic changes as a result of rotation of ischemic vessels as mentioned in other reports.^{12,13} Despite its doubtful presence in up to 18% of cases^{14,15} and surgical history of our patients, the right colic artery was preserved in 5 patients. Appendectomy was invariably performed, since the new position of the appendix (right lumbar region or right hypochondriac region) could lead to a delay in the diagnosis

Table 4 – Comparison of anastomotic leak in Deloyers procedure.

| Variable | No. of patients | Anastomotic leak rate (%) |
|--|-----------------|---------------------------|
| <i>Sarli et al.</i> ¹² | | |
| DP | 26 | 0 |
| PPI | 0 | 0 |
| <i>Manceau et al.</i> ⁵ | | |
| DP | 17 | 0 |
| PPI | 31 | 0 |
| <i>Dumont et al.</i> ¹⁵ | | |
| DP | 20 | 0 |
| PPI | 9 | 11 |
| <i>Kontovounisios et al.</i> ¹⁶ | | |
| DP | 5 | 0 |
| PPI | 9 | 0 |
| <i>Salgado et al.</i> | | |
| DP | 11 | 0 |
| PPI | 5 | 0 |

DP, Deloyers procedure; PPI, Deloyers procedure + protective ileostomy.

of appendicitis in these patients. No secondary complications resulting from this procedure were found in our series.

There is currently no recommendation on the use of protective ileostomy during the Deloyers procedure. In our series, protective ileostomy was performed in 5 patients (32%), lower number than those usually reported in other series (up to 64%). The decision to perform a protective ileostomy in the minority of patients was based on the proper release and rotation of the proximal colon. In our opinion, this procedure works very similar to an ileotransverse anastomosis adequate due to adequate mobility of the proximal portion thereof and with a proper dilation of the sphincter complex.^{5,12,15,16}

In the increased morbidity, the formation of a presacral collection was reported in each of the DP vs. PPI groups. No leakage of the anastomosis site was found. It is similar to that recorded in previous studies with Deloyers where an incidence of 0–11%^{5,12,15,16} is mentioned (Table 4), which is clearly higher than that reported in series of ileorectal anastomosis mentioned ranging from 3 to 17%.^{8,15,17} It is noteworthy that in the DP group has a lower major morbidity rate, and the morbidity associated with stoma closure was of 40%. Although both patients had a minor complication, a patient with wound infection and one with a post-incisional hernia. The morbidity resulting from closure of derivative procedures is well known and has not negligible numbers of morbidity rate from 0 to 38% and mortality rate from 0 to 6.9%.¹⁸ No re-surgeries and mortality were reported in our complete series.

The most important limitations in our study are those inherent by its retrospective nature and those regarding the selection of patients. The decision to determine the need for protective ileostomy was a decision made by the responsible surgeon. The surgical judgment – which considers the patient's general condition, associated comorbidities and even the type of anastomosis used among other factors – influences the intraoperative decisions that may bias the formation of the groups analyzed. In our favor, demographics, Charlson

index, ASA classification, and surgical time >3 h in both groups showed no difference, which translates similarity of circumstances. It is noteworthy that the experience observed in our series using this technique began with the first patient in February 2013 without record of similar procedures performed at our institution previously.

Conclusion

The results of the Deloyers procedure are satisfactory and reproducible. The major and minor morbidity rates were similar between groups, suggesting that the morbidity and costs associated with the ileostomy closure can be avoided in patients who are candidates for this procedure.

Conflicts of interest

The authors declare no conflicts of interest.

REFERENCES

1. Deloyers L. Suspension of the right colon permits without exception preservation of the anal sphincter after extensive colectomy of the transverse and left colon (including rectum). *Technic – indications – immediate and late results.* *Lyon Chir.* 1964;60:404–13.
2. Fasth S, Hedlund H, Svaninger G, Oresland T, Hultén I. Functional results after subtotal colectomy and caecorectal anastomosis. *Acta Chir Scand.* 1983;149:623–7.
3. Sarli L, Costi R, Sarli D, Roncoroni L. Pilot study of subtotal colectomy with antiperistaltic cecoproctostomy for the treatment of chronic slow-transit constipation. *Dis Colon Rectum.* 2001;44:1514–20.
4. Dindo D, Demartines N, Clavien PA. Classification of surgical complications: a new proposal with evaluation in a cohort of 6336 patients and results of a survey. *Ann Surg.* 2004;240:205–13.
5. Manceau G, Karoui M, Breton S, Blanchet AS, Rousseau G, Savier E, et al. Right colon to rectal anastomosis (Deloyers procedure) as a salvage technique for low colorectal or coloanal anastomosis: postoperative and long term outcomes. *Dis Colon Rectum.* 2012;55:363–8.
6. You YN, Chua HK, Nelson H, Hassan I, Barnes SA, Harrington J. Segmental vs. extended colectomy: measurable differences in morbidity, function, and quality of life. *Dis Colon Rectum.* 2008;51:1036–43.
7. Mariani A, Moszkowicz D, Trésallet C, Koskas F, Chiche L, Lupinacci R, et al. Restoration of intestinal continuity after colectomy for non-occlusive ischemic colitis. *Tech Coloproctol.* 2014;18:623–7.
8. Christos K, Baloyiannis Y, Kinross J, Tan E, Rasheed S, Tekkis P. Modified right colon inversion technique as a salvage procedure for colorectal or coloanal anastomosis. *Colorectal Dis.* 2014;16:971–5.
9. Umar US, Kullar N, Dorudi S. Right colonic transposition technique: when the left colon is unavailable for achieving a pelvic anastomosis. *Dis Colon Rectum.* 2011;54:360–2.
10. Todd IP. Constipation: Results of surgical treatment. *Br J Surg.* 1985;72 Suppl.:S12–3.
11. Costalat G, Garrigues JM, Didelot JM, Yousfi A, Boccasanta P. Subtotal colectomy with ceco-rectal anastomosis (Deloyers) for severe idiopathic constipation: an alternative to total

- colectomy reducing risks of digestive sequelae. *Ann Chir.* 1997;51:248–55.
12. Sarli L, Costi R, Iusco D, Roncoroni L. Long-term results of subtotal colectomy with antiperistaltic cecoproctostomy. *Surg Today.* 2003;33:823–7.
 13. Douglas W, Dimitrova M, Nandakumar G. Colonic salvage with antiperistaltic cecorectal anastomosis. *Dis Colon Rectum.* 2015;58:270–4.
 14. Saunders BP, Phillips RK, Williams CB. Intraoperative measurement of colonic anatomy and attachments with relevance to colonoscopy. *Br J Surg.* 1995;82:1491–3.
 15. Dumont F, Da Re C, Goéré D, Honoré C, Elias D. Options and outcome for reconstruction after extended left hemicolectomy. *Colorectal Dis.* 2013;15:747–54.
 16. Kontovounisios C, Baloyiannis Y, Kinross J, Tan E, Rasheed S, Tekkis P. Modified right colon inversion technique as a salvage procedure for colorectal or coloanal anastomosis. *Colorectal Dis.* 2014;16:971–5.
 17. Tang ST, Yang Y, Wang GB, Tong QS, Mao YZ, Wang Y, et al. Laparoscopic extensive colectomy with transanal soave pull-through for intestinal neuronal dysplasia in 17 children. *World J Pediatr.* 2010;6:50–4.
 18. Chow A, Tilney HS, Paraskeva P, Jeyarajah S, Zacharakis E, Purkayastha S. The morbidity surrounding reversal of defunctioning ileostomies: a systematic review of 48 studies including 6,107 cases. *Int J Colorectal Dis.* 2009;24:711–23.