



# Journal of Coloproctology

[www.jcol.org.br](http://www.jcol.org.br)



## Case Report

# Giant appendiceal mucinous cystadenoma treated by laparoscopy: a case report and review of the literature



Felipe Ramos Nogueira<sup>a,\*</sup>, Francisco Wendel de Sousa Arruda<sup>a</sup>,  
Carla Camila Rocha Bezerra<sup>a</sup>, Benjamin Ramos de Andrade Neto<sup>a</sup>,  
Manoel Italo Pimentel Santos Lopes<sup>a</sup>, Edson de Macedo Sousa<sup>a</sup>,  
Alessandra Marques dos Santos<sup>b</sup>, Adryano Gonçalves Marques<sup>c</sup>,  
Lusmar Veras Rodrigues<sup>c,d,e,f,g</sup>

<sup>a</sup> Universidade Federal do Ceará (UFC), Hospital Universitário Walter Cantídio (HUWC), Fortaleza, CE, Brazil

<sup>b</sup> Universidade Federal do Ceará (UFC), Hospital Universitário Walter Cantídio (HUWC), Programa de Residência Médica em Patologia, Fortaleza, CE, Brazil

<sup>c</sup> Universidade Federal do Ceará (UFC), Hospital Universitário Walter Cantídio (HUWC), Programa de Residência Médica em Coloproctologia, Fortaleza, CE, Brazil

<sup>d</sup> Universidade Federal de São Paulo (UNIFESP), São Paulo, SP, Brazil

<sup>e</sup> Universidade Federal do Ceará (UFC), Departamento de Cirurgia, Fortaleza, CE, Brazil

<sup>f</sup> Universidade Federal do Ceará (UFC), Hospital Universitário Walter Cantídio (HUWC), Serviço de Coloproctologia, Fortaleza, CE, Brazil

<sup>g</sup> Universidade Federal do Ceará (UFC), Programa de Pós-Graduação em Cirurgia, Fortaleza, CE, Brazil

## ARTICLE INFO

### Article history:

Received 11 February 2017

Accepted 2 April 2017

Available online 5 May 2017

### Keywords:

Cystadenoma, mucinous

Appendiceal neoplasms

Mucocele

Pseudomyxoma peritonei

## ABSTRACT

Appendiceal mucinous cystadenoma is a rare entity, which causes appendicular mucocele. It is more frequent in women over 50 years old. In half of the cases it is asymptomatic. Tomography of the abdomen is the gold standard in its preoperative diagnosis. The treatment is surgical, with good prognosis, the complete resection evolves without appendicular rupture and extravasation. We report a case of a 64-year-old man with appendiceal mucinous cystadenoma. A laparoscopic right hemicolectomy was performed. This therapy that can be safely used to treat appendiceal mucocele, as long as it is cautious.

© 2017 Sociedade Brasileira de Coloproctologia. Published by Elsevier Editora Ltda. This is an open access article under the CC BY-NC-ND license (<http://creativecommons.org/licenses/by-nc-nd/4.0/>).

\* Corresponding author.

E-mail: [felipernogueira@gmail.com](mailto:felipernogueira@gmail.com) (F.R. Nogueira).

<http://dx.doi.org/10.1016/j.jcol.2017.04.002>

2237-9363/© 2017 Sociedade Brasileira de Coloproctologia. Published by Elsevier Editora Ltda. This is an open access article under the CC BY-NC-ND license (<http://creativecommons.org/licenses/by-nc-nd/4.0/>).

## Cistadenoma mucinoso apendicular gigante tratado por laparoscopia: relato de caso e revisão de literatura

### RESUMO

#### Palavras-chave:

Cistadenoma mucinoso  
Neoplasias apendiculares  
Mucocele  
Pseudomixoma peritoneal

O cistadenoma mucinoso apendicular é entidade rara que causa mucocele apendicular, sendo mais frequente em mulheres acima dos 50 anos. Em metade dos casos, o cistadenoma mucinoso apendicular é assintomático. A tomografia do abdome é o padrão-ouro para um diagnóstico pré-operatório. O tratamento é cirúrgico e tem bom prognóstico; a ressecção completa evolui sem ruptura apendicular e sem extravasamento. Relatamos um caso de paciente homem de 64 anos com cistadenoma mucinoso apendicular. Foi realizada hemicolectomia laparoscópica direita. Esse é um procedimento que pode ser usado com segurança no tratamento de mucocele apendicular, desde que seja executado com cautela.

© 2017 Sociedade Brasileira de Coloproctologia. Publicado por Elsevier Editora Ltda. Este é um artigo Open Access sob uma licença CC BY-NC-ND (<http://creativecommons.org/licenses/by-nc-nd/4.0/>).

### Introduction

Appendiceal mucinous cystadenoma is a rare disease, which causes appendiceal mucocele, an enlargement of the appendix by mucin.<sup>1</sup> In a large number of cases, it is asymptomatic, being diagnosed incidentally,<sup>2</sup> and may simulate acute appendicitis.<sup>1</sup> Complete surgical resection without rupture of the organ has excellent prognosis.<sup>2</sup> However, in case of rupture, it may evolve into pseudomyxoma peritonei, with poor prognosis.<sup>1,2</sup>

There is great deal of controversy among surgeons regarding the use of laparoscopy as a surgical approach for resection of mucocele, especially of possible neoplastic origin, due to the risk of perforation and mucin extravasation.<sup>1,3,4</sup> However, there are reports of successful use of laparoscopy in the resection of appendiceal mucocele, associated with the benefits inherent to the method.<sup>5,6</sup>

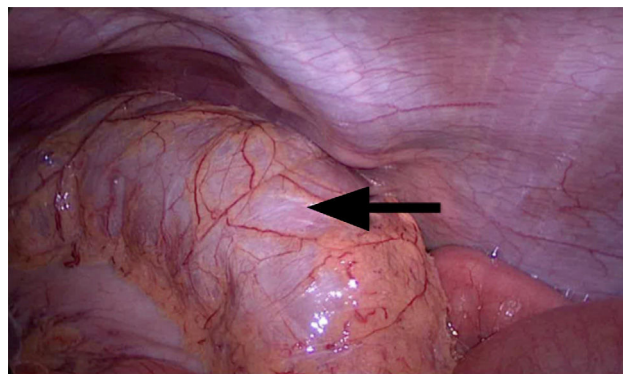
Thus, it is necessary that surgeons have knowledge of this method, for an appropriate performance, providing good evolution and preventing pseudomyxoma peritonei occurrence.

A symptomatic case is reported, manifested by abdominal pain, explosive diarrhea and hematochezia, unusual symptoms for the pathology in question. Subsequently, diagnostic, histopathological, therapeutic and prognostic aspects are discussed.

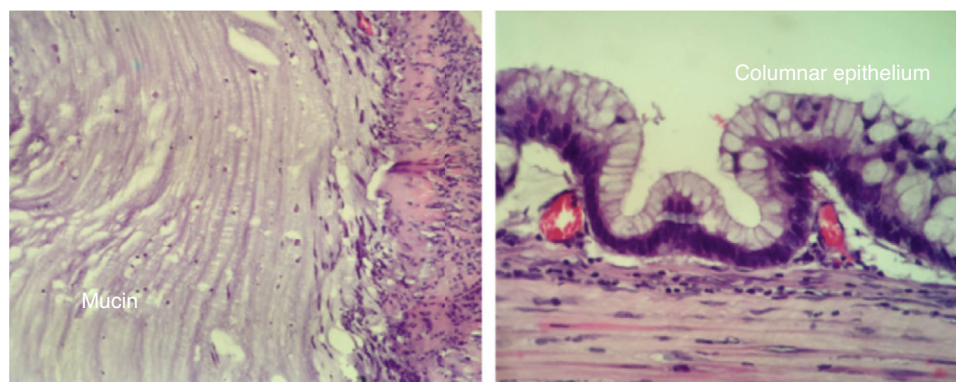
### Case report

A 64-year-old male, a farmer, with moderate nonspecific abdominal pain, explosive and watery diarrhea, and tenesmus for 4 months, associated with an episode of hematochezia throughout this period. There are no comorbidities, family history of colorectal cancer, allergies or use of medications. Physical examination showed good general condition, no signs of anemia. Asymmetric abdomen, bulging in the right quadrants, with a large painless palpable mass, dull sound on percussion, extending from the iliac fossa to the right hypochondrium. No evidence of peritoneal irritation. Colonoscopy revealed a subepithelial tumor at the level of

the appendiceal ostium, displacing it, measuring 8 cm in its largest diameter, whose histopathological evaluation revealed only nonspecific colitis. The computed tomography showed a thin-walled, vermiform appendix filled with thick contents, measuring 15 cm on its largest axis, with anterosuperior displacement of the cecum, without signs of perforation (Fig. 1). Appendiceal mucocele was diagnosed. The colorectal surgery group at the Hospital Universitário Walter Cantídio has as one of its strengths the experience in videolaparoscopy, being this modality the gold standard for the treatment of colorectal diseases. Therefore, a laparoscopic right hemicolectomy was performed in this case. Surgery was performed following exactly the same steps as a regular videolaparoscopic right colectomy, with an initial medial approach followed by lateral dissection. Tumor size did not change the operative tactic. The only additional care is the delicacy of the movements, in order not to leak the cystadenoma. The surgical piece was removed by transumbilical incision. The histopathological diagnosis was appendiceal mucinous cystadenoma, measuring 10 cm in its largest diameter, with tumor-free margin (Fig. 2). There was superficial infection of the surgical wound on the third postoperative day, treated with partial opening and drainage of the surgical wound. The patient was discharged on the eighth postoperative day. This minor intercurrent postponed the hospital discharge. However, this fact did not negate all the



**Fig. 1 – Voluminous cecal appendix revealed by laparoscopy (arrow).**



**Fig. 2 – Histology of the lesion, showing mucin covered by mucus secreting columnar epithelium.**

advantages of videolaparoscopic surgery. Seven months later, he was asymptomatic.

## Discussion

Appendiceal mucinous cystadenoma is a benign appendiceal neoplasm of simple epithelium, mucus-secreting, with several degrees of dysplasia, and accumulation of appendiceal luminal mucin, the appendiceal mucocele.<sup>1,2</sup> This term was created by Fere in 1877. However, the pathological entity was first recognized by Rokitansky in 1842 and described by Virchow in 1863.<sup>7,8</sup> In association with appendiceal epithelial hyperplasia, appendiceal mucinous cystadenoma corresponds to 31-34% of the mucoceles of the appendix, rare entities that contribute with 0.2-0.7% of the appendiceal pathologies.<sup>1</sup> Thus, appendiceal mucinous cystadenoma is not discussed individually, but as part of a larger entity, the appendiceal mucocele.

Appendiceal mucocele is more frequent in women over 50 years old.<sup>3</sup>

The clinical picture of the appendiceal mucocele is not specific. About 50% of the cases are asymptomatic, with incidental diagnosis by endoscopic, imaging or surgical findings. In symptomatic cases, abdominal pain is the most common symptom (80% of patients), as in the case of the patient in question. Further findings include palpable mass, which was found on examination of the patient; nausea, vomiting, weight loss, lower intestinal hemorrhage, peritonism or intestinal occlusive disease.<sup>1,3,4</sup>

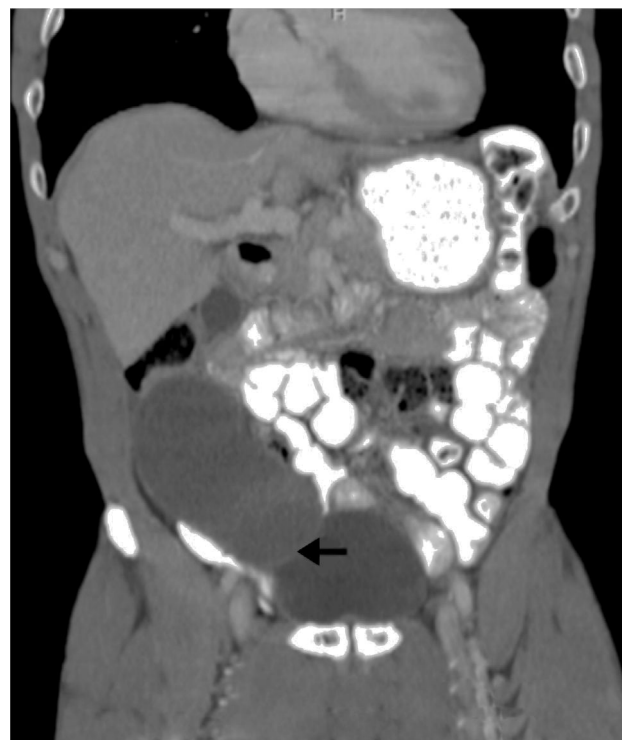Preoperative diagnosis is difficult. However, it is of great importance for the selection of an adequate surgical approach.<sup>9</sup>

The complementary exams help in the diagnostic elucidation and treatment planning. Ultrasound of the abdomen can differentiate acute appendicitis from mucocele, in addition to facilitating the identification of appendiceal mass and visualizing the ovary in women. It shows an encapsulated cystic lesion, firmly attached to the cecum, with liquid content of variable echogenicity, according to the density of the mucus. Computed tomography is the gold standard. Carried out in the investigation of the reported case, it shows the extent of the disease and may identify associated complications. It shows a cylindrical, encapsulated, thin-walled mass

communicating with the cecum,<sup>2,4,10</sup> exactly as reported (Fig. 3). It is not useful in differentiating between benign and malignant mucocele.<sup>11</sup> Colonoscopy may show a soft, erythematous elevation, containing the appendiceal ostium, and there may be a yellowish mucoid discharge known as “volcano sign”, which is pathognomonic.<sup>4,10</sup> In the case reported, only a subepithelial elevation was observed at the level of the appendiceal ostium, without discharge.

The CEA and CA 19-9 tumor markers are associated with appendiceal neoplastic processes and should be included in the diagnostic investigation.<sup>1</sup>

Due to the difficulty in distinguishing from cystadenocarcinoma, and the potential complication of rupture (about 20%) and evolution into pseudomyxoma peritonei, the recommended treatment for cystadenoma is surgical,<sup>1,3,4</sup> with



**Fig. 3 – Lesion in topography of cecal appendix, hypodense, in a sagittal CT of abdomen (arrow).**

removal of the piece without curative rupture of mucocoeles of benign etiology.<sup>12,13</sup> Adequate preoperative evaluation and careful intraoperative dissection are very important in preventing rupture and malignant transformation that can be associated with mucocoeles of malignant etiology.<sup>3</sup> It is believed that the open procedure is the most recommended because it reduces the chance of rupture and mucin extravasation.<sup>1–4</sup> However, the use of laparoscopy may allow a better evaluation of the intraoperative lesion and assist in the surgical planning. Since surgeons with experience in minimally invasive surgery are available, laparoscopic-assisted right hemicolectomy can be safely performed for mucinous cystadenoma or cystadenocarcinoma of the appendix to minimize the unnecessary complication of peritoneal mucin leakage, which may occur during the conventional or laparoscopic method.<sup>5</sup> In addition, patients benefit from a minimally invasive surgery, including a minor wound and shorter period of convalescence.<sup>5,6,12,14</sup> Furthermore, there are reports of use of a safe technique in the laparoscopic surgical treatment of appendiceal mucocoele with a single access to the peritoneal cavity.<sup>15,16</sup> As a safety recommendation for laparoscopic resections, the surgical piece should be removed in endobag.<sup>9,17–19</sup>

An algorithm for choosing the type of surgery has been created by Dhage-Ivatury and Sugarbaker.<sup>20</sup> It provides for several factors: whether a mucocoele is perforated or not; whether the base of the appendix (resection margins) is involved in the process; and if there are positive lymph nodes in the mesoappendix and ileocolic chain. As a result, patients may require different surgeries: appendectomy to right colectomy, including cytoreductive surgery, intraoperative intraperitoneal hyperthermic chemotherapy or immediate postoperative intraperitoneal hyperthermic chemotherapy. Cecectomy and right hemicolectomy are recommended for appendices in which adequate surgical margins can not be obtained (broad base and projection in the cecal lumen).<sup>6,12</sup>

The histopathology shows pure or glandular villous tissue, with epithelium showing mild, moderate or severe dysplasia, identifying itself with tubular or tubulovillous adenomas of the colon. The production of mucin is prominent and can lead to flattening of the epithelium.<sup>13</sup>

The prognosis is excellent when there is complete resection without rupture (100% survival in 5 years).<sup>2</sup> With rupture and extravasation of mucin in cavity, it can evolve to pseudomyxoma peritonei in 2% of the cases of cystadenomas,<sup>1</sup> with a 5-year survival of only 20–25%.<sup>11</sup> Although there is the aforementioned statistic, in a previous study on histopathology of the mucocoele associated with the appendiceal cystadenoma, patients in which there were rupture and extravasation of periappendiceal mucin, it did not show epithelial cells and the patient's follow up did not identify evolution into pseudomyxoma peritonei, suggesting a benign pathological condition.<sup>13</sup>

In about 20% of the cases, appendiceal mucinous cystadenoma may be associated with synchronous or metachronous colon cancer.<sup>3</sup>

## Conclusion

Appendiceal mucinous cystadenoma is a rare entity, more frequent in women over 50 years old. It is asymptomatic in

half of the cases, open surgical therapy is the most accepted approach. However, through meticulous dissection and extra care to the manipulation and removal of the piece, the laparoscopic surgery can and has been used, with a lower index of postoperative morbidity, early recovery and improvement of abdominal esthetics associated with the surgical incision.

## Conflict of interest

The authors declare no conflict of interest.

## REFERENCES

- Rymer B, Forsythe RO, Husada G. Mucocoele and mucinous tumours of the appendix: a review of the literature. *Int J Surg*. 2015;18:132–5.
- Rouchaud A, Glas L, Gayet M, Bellin M-F. Cystadénome Mucineux de l'appendice. *Diagn Interv Imaging*. 2014;95:113–6.
- Kılıç MÖ, İnan A, Bozer M. Four mucinous cystadenoma of the appendix treated by different approaches. *Turk J Surg/Ulusal Cerr Derg*. 2014;30:97–9.
- Demetrashvili Z, Chkhaidze M, Khutsishvili K, Topchishvili G, Javakhishvili T, Pipia I, et al. Mucocoele of the appendix: case report and review of literature. *Int Surg*. 2012;97:266–9.
- Ng SS, Lee JF. Mucinous cistadenoma of the appendix. *Can J Surg*. 2009;52:158–9.
- Palanivelu C, Rangarajan M, John SJ, Senthilkumar K, Annapoorni S. Laparoscopic right hemicolectomy for mucocoele due to a low-grade appendiceal mucinous neoplasm. *JLS*. 2008;12:194–7.
- Andrews EC, Feller LW, Crenwelge WE. Mucocoele of the appendix: clinical case. *Texas Med*. 1966;62:61.
- Pereira JCR, Silva Júnior CA. Mucocoele do apêndice. *Rev Col Bras Cir*. 2001;28:225–7.
- Lin C, Li X, Guo Y, Hu G, Zhang Y, Yang K, et al. Simultaneous giant mucinous cystadenoma of the appendix and intestinal schistosomiasis: 'case report and brief review'. *World J Surg Oncol*. 2014 17;12:385.
- Rampone B, Roviello F, Marrelli D, Pinto E. Giant appendiceal mucocoele: report of a case and brief review. *World J Gastroenterol*. 2005;11:4761–3.
- Wang H, Chen YQ, Wei R, Wang QB, Song B, Wang CY, et al. Appendiceal mucocoele: a diagnostic dilemma in differentiating malignant from benign lesions with CT. *Am J Roentgenol*. 2013;201:W590–5.
- Park KJ, Choi HJ, Kim SH. Laparoscopic approach to mucocoele of appendiceal mucinous cystadenoma: feasibility and short-term outcomes in 24 consecutive cases. *Surg Endosc*. 2015;29:3179–83.
- Alderdice JM, Hayes D. Mucocoeles of the appendix. Their underlying epithelia, behaviour and associated tumour. *Ulster Med J*. 1983;52:131–5.
- Yoshida Y, Sato K, Tada T, Maekawa H, Sakurada M, Orita H, et al. Two cases of mucinous cystadenoma of the appendix successfully treated by laparoscopy. *Case Rep Gastroenterol*. 2013;7:44–8.
- Ishibashi K, Okada N, Ohsawa T, Kumamoto K, Haga N, Ishida H. A simple and safe technique for performing single-port laparoscopic resection of appendiceal mucocoele. *Tech Coloproctol*. 2011;15:341–3.
- Hirano Y, Hattori M, Nishida Y, Maeda K, Douden K, Hashizume Y. Single-incision laparoscopic ileo-cecal resection for appendiceal mucocoele. *Ind J Surg*. 2013;75 Suppl. 1:250–2.

17. Liberale G, Lemaitre P, Noterman D, Moerman C, de Neubourg E, Sirtaine N, et al. How should we treat mucinous appendiceal neoplasm? By laparoscopy or palarotomy? A case report. *Acta Chir Belg.* 2010;110:203-7.
18. Rangarajan M, Palanivelu C, Kavalakat A, Parthasarathi R. Laparoscopic appendectomy for mucocele of the appendix: report of 8 cases. *Indian J Gastroenterol.* 2006;25:256-7.
19. Rabie ME, Al Shraim M, Al Skaini MS, Algahtani S, El Hakeem I, Al Oahtani AS, et al. Mucus containing cystic lesions mucocele of the appendix: the unresolved issues. *Int J Surg Oncol.* 2015;139461:2015.
20. Dhage-Ivatury S, Sugarbaker PH. Update on the surgical approach to mucocele of the appendix. *J Am Coll Surg.* 2006;202:680-4.