



Journal of Coloproctology

www.jcol.org.br



Technical Note

FILAC – Fistula – Tract Laser Closure: a sphincter-preserving procedure for the treatment of complex anal fistulas



Alexandre Lopes de Carvalho^{a,*}, Eduardo Fonseca Alves Filho^b,
Rogério Souza Medrado de Alcantara^b, Marcelo da Silva Barreto^b

^a Hospital da Bahia, Serviço de Coloproctologia, Salvador, BA, Brazil

^b Hospital Português, Serviço de Coloproctologia, Salvador, BA, Brazil

ARTICLE INFO

Article history:

Received 13 July 2016

Accepted 27 March 2017

Available online 19 April 2017

Keywords:

FILAC

Laser anal fistula

Anal fistula

Palavras-chave:

FILAC

Laser fístula anal

Fístula anal

ABSTRACT

Several surgical options are described for the treatment of anorectal fistulas, particularly in complex cases where recurrence rates and the possibility of postoperative incontinence are still high. The aim of this study is to describe the use of FILAC technique (Fistula – Tract Laser Closure) minimally invasive and preservation sphincter technique. FILAC has been described in the literature as an option in the management of anorectal fistula.

© 2017 Sociedade Brasileira de Coloproctologia. Published by Elsevier Editora Ltda. This is an open access article under the CC BY-NC-ND license (<http://creativecommons.org/licenses/by-nc-nd/4.0/>).

FILAC – Fechamento do trajeto da fístula à laser: Procedimento de preservação esfíncteriana para o tratamento das fístulas anais complexas

RESUMO

Várias opções cirúrgicas são descritas para o tratamento de fístulas anorretais, especialmente em casos complexos, onde as taxas de recorrência e a possibilidade de incontinência pós-operatória ainda são elevadas. O objetivo deste estudo é descrever o uso da técnica FILAC (Fechamento do trajeto da fístula à laser), técnica minimamente invasiva com preservação esfíncteriana. FILAC tem sido descrito na literatura como uma opção no manejo da fístula pcoleriana.

© 2017 Sociedade Brasileira de Coloproctologia. Publicado por Elsevier Editora Ltda. Este é um artigo Open Access sob uma licença CC BY-NC-ND (<http://creativecommons.org/licenses/by-nc-nd/4.0/>).

* Corresponding author.

E-mail: alexandre1c@gmail.com (A.L. Carvalho).

<http://dx.doi.org/10.1016/j.jcol.2017.03.001>

2237-9363/© 2017 Sociedade Brasileira de Coloproctologia. Published by Elsevier Editora Ltda. This is an open access article under the CC BY-NC-ND license (<http://creativecommons.org/licenses/by-nc-nd/4.0/>).

Introduction

The anorectal fistulas have been described for more than 2500 years. It is an epithelialized path that communicates the anal canal to the perianal skin. Its estimated incidence is 68,000-96,000 new cases per year in the United States.¹ The average age of onset is about 40 years and is more prevalent in men than in women in an estimated ratio of 2:1 to 7:1.² The treatment is basically surgery for the primary fistula, which has no concomitant conditions, such as inflammatory bowel disease, tuberculosis, neoplasia, etc.

Its management has been a challenge for colorectal surgeons and the possibility of recurrence and postoperative incontinence remains high in complex cases, especially in high transphincteric fistulas, suprasphincteric fistulas, recurrent cases and in women.

The most used techniques are fistulotomy and fistulectomy with similar rates of recurrence and relapse; 5 and 7%, respectively. Incontinence is commonly reported as involuntary leakage of mucus and flatus and less frequently feces.²

New methods have recently been incorporated for the treatment of fistulas (LIFT – Ligation Intersphincteric Fistula Tract and VAAFT – Video Assisted Anal Fistula Treatment) and different implants to occlude path (plugs and glue) in an attempt to become less invasive surgery and preserve sphincter.³ Although the risk of incontinence is minimal in such cases the recurrence rate is higher when compared to traditional techniques.

The diode laser has been used in various areas of medicine (Urology, Otorhinolaryngology, Gynecology, Vascular surgery, Neurosurgery) and was also incorporated in Coloproctology through FILAC (Fistula – Tract Laser Closure), sealing and closure of the fistula through Laser.

Material and methods

Surgical technique

The patient underwent spinal anesthesia and is positioned in lithotomy. Antibiotic prophylaxis with Unasyn 3 g and bowel preparation with rectal enema one day before surgery. After recognition of the external orifice, fistulae catheterization is performed with probe, cleaning with saline irrigation and miomucosal flap with resection of the internal orifice.

Introduction of the laser fiber through the external to the internal orifice, activation of laser and gradual withdrawal 5 mm fiber every 3 s, from the internal to the external orifice with simultaneous destruction and sealing of paths (Figs. 1 and 2). The fiber laser diode used is a radial emission wavelength 1470 nm (FILAC fistula probe, Biolitec, Germany). The BIOLITEC LEONARDO generator was set to 13 W continuously (Fig. 3).

At the end of the procedure, the miomucosal flap was sutured, covering the area of the internal orifice and made resection of the external orifice for proper drainage of the wound (Figs. 4 and 5).

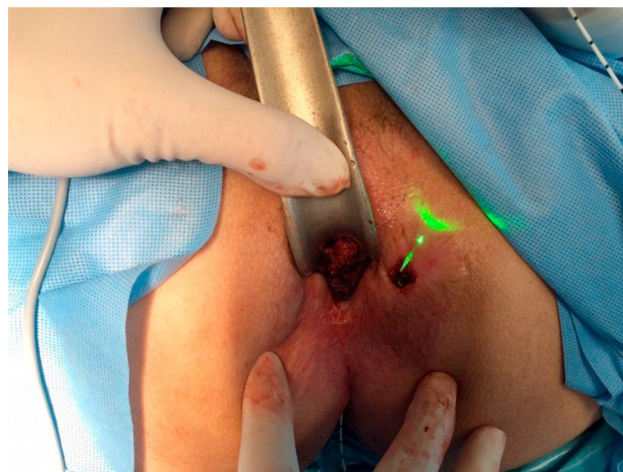


Fig. 1 – Activation of laser fiber.

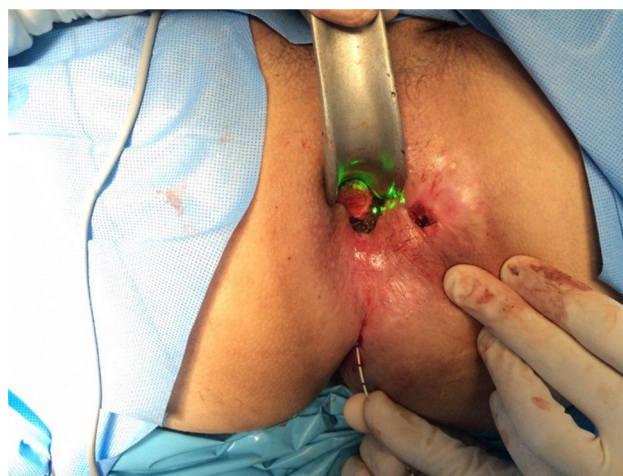

Fig. 2 – Activation of laser fiber.

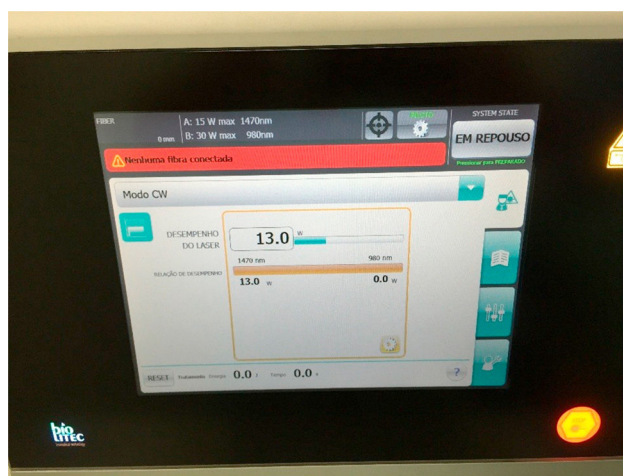


Fig. 3 – Leonardo generator.

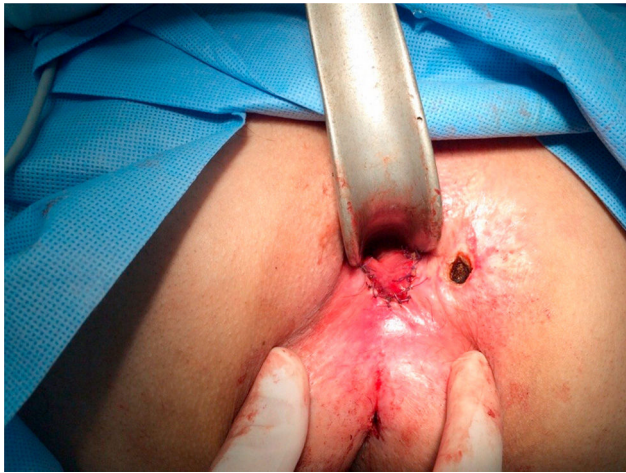

Fig. 4 – Final aspect of procedure.

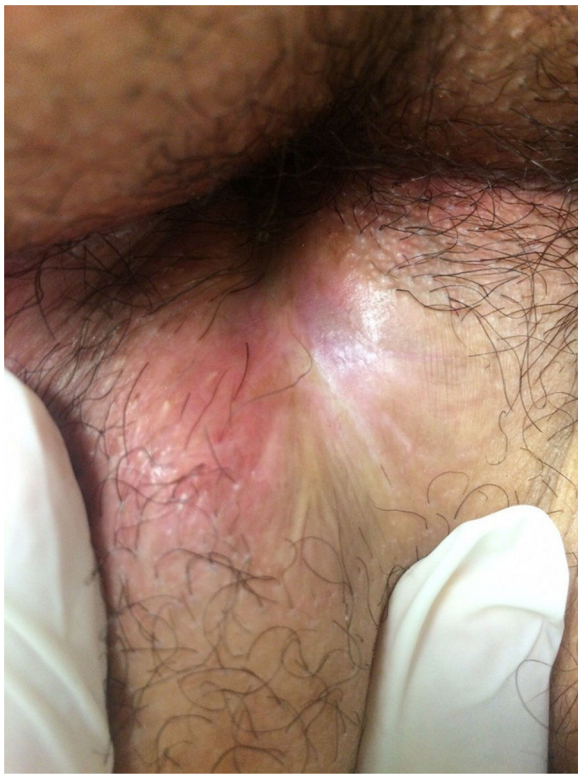

Fig. 5 – Wound healed.

Discussion

The use of FILAC for the treatment of anorectal fistula has shown encouraging. The technique is easy to learn and fast to perform, allows exploration of curved paths and any size since the fiber is very flexible and long. The destruction of the epithelialized path and sealing is carried out by laser emission radially 360°, thereby allowing the application of energy across the path homogeneous in a controlled manner.

This procedure can be combined with other techniques that close the internal orifice as miomucosal flap

advancement. The sealing of the path may be accompanied by endorectal ultrasound if necessary, with good visibility of the fiber.

FILAC success in healing anorectal fistulas in different studies in the literature is 71–82%,⁴⁻⁷ with a mean of 30 months in the study with longer observation time.⁴ Among the adverse events reported, pain, tenesmus and soiling are the most common. There was no change in continence in anorectal manometry.⁷ No serious complications were reported in the studies.

The need for prior use of setons and the optimal treatment of the internal orifice, either miomucosal advancement flap, simple stitches or leaves it open, is not well defined in the literature.

Giamundo et al. recommends the use of setons preoperatively, bearing in mind that the healing rate in the subgroup of one of his works⁷ was higher in patients who used the Seton compared to those who did not use the Seton (81% × 63%, respectively). This observation should be viewed with caution due to the small number of patients and the characteristics inherent in the study.

A major disadvantage of this method is the cost of laser fiber, which is still quite high in our country.

Conclusion

The FILAC, sphincter preservation minimally invasive surgery in the treatment of anal fistulas, looks promising although prospective and long-term follow-up studies should be conducted.

Conflicts of interest

The authors declare no conflicts of interest.

REFERENCES

1. Abcarian H. *Anal fistula: principles and management*. Springer Science & Business Media; 2013.
2. Gordon PH, Nivatvongs S, Mulholland MW. *Principles and practice of surgery for the colon, rectum, and anus*. Shock. 1999;12:328.
3. Limura E, Giordano P. Modern management of anal fistula. *World J Gastroenterol*. 2015;21:12–20.
4. Giamundo P, Esercizio L, Geraci M, Tibaldi L, Valente M. Fistula-tract Laser Closure (FiLaC™): long-term results and new operative strategies. *Tech Coloproctol*. 2015;19:449–53.
5. Wilhelm A. A new technique for sphincter-preserving anal fistula repair using a novel radial emitting laser probe. *Tech Coloproctol*. 2011;15:445–9.
6. Oztürk E, Gülcü B. Laser ablation of fistula tract: a sphincter-preserving method for treating fistula-in-ano. *Dis Colon Rectum*. 2014;57:360–4.
7. Giamundo P, Geraci M, Tibaldi L, Valente M. Closure of fistula-in-ano with laser-FiLaC™: an effective novel sphincter-saving procedure for complex disease. *Colorectal Dis*. 2014;16:110–5.