



Journal of Coloproctology

www.jcol.org.br



Technical Note

Three-dimensional virtual reconstruction as a tool for preoperative planning in the management of complex anorectal fistulas[☆]



Edilson Carvalho Sousa Júnior^{a,b}, Alexandre Tolstenko Nogueira^c,
Bruno Aragão Rocha^d, Walberto Monteiro Neiva Eulálio Filho^{e,*},
Aurus Dourado Meneses^f

^a Hospital São Marcos – Associação Piauiense de Combate ao Câncer, Departamento de Coloproctologia, Teresina, PI, Brazil

^b Universidade Federal do Piauí (UFPI), Departamento de Clínica Cirúrgica, Teresina, PI, Brazil

^c Universidade Federal do Piauí (UFPI), Departamento de Ciências da Computação, Teresina, PI, Brazil

^d Universidade de São Paulo (USP), Departamento de Radiologia, São Paulo, SP, Brazil

^e Universidade Federal do Piauí (UFPI), Teresina, PI, Brazil

^f Hospital São Marcos – Associação Piauiense de Combate ao Câncer, Departamento de Urologia, Teresina, PI, Brazil

ARTICLE INFO

Article history:

Received 25 April 2017

Accepted 28 November 2017

Available online 27 December 2017

Keywords:

Rectal fistula

Three-dimensional image

Surgical procedures of the digestive system

ABSTRACT

The making of three-dimensional virtual models is a promising technology in preoperative planning, but that is not used in the treatment of anorectal fistulas. The objective of this work is to describe the development and initial experience of the construction of a virtual three-dimensional model of the pelvic anatomy of a patient, allowing the exact identification of the relationships between the fistulous tracts of complex anorectal fistulas and the other pelvic structures. An MRI was performed on this patient, and the images were exported to the Vitrea fX Workstation[®] software. A radiologist did the analysis and segmentation of the images that were then sent to a three-dimensional image processor (Meshlab v. 1.3.3 – ISTI – CNR Research Center, Pisa University, Italy). The final 3D color image was analyzed by the surgeon and used to guide the catheterization of the fistulous pathways, the internal orifice and to assist in the identification of adjacent structures. The final three-dimensional model presented a high correlation with the intraoperative findings and facilitated the surgical planning.

© 2017 Sociedade Brasileira de Coloproctologia. Published by Elsevier Editora Ltda. This is an open access article under the CC BY-NC-ND license (<http://creativecommons.org/licenses/by-nc-nd/4.0/>).

[☆] Study conducted at Hospital São Marcos – Associação Piauiense de Combate ao Câncer, Departamento de Coloproctologia, Teresina, PI, Brazil.

* Corresponding author.

E-mail: walberto@outlook.com (W.M. Eulálio Filho).

<https://doi.org/10.1016/j.jcol.2017.11.002>

2237-9363/© 2017 Sociedade Brasileira de Coloproctologia. Published by Elsevier Editora Ltda. This is an open access article under the CC BY-NC-ND license (<http://creativecommons.org/licenses/by-nc-nd/4.0/>).

Reconstrução virtual tridimensional como ferramenta de planejamento pré-operatório de fistulas anais complexas

R E S U M O

Palavras-chave:

Fístula retal
Imagem tridimensional
Procedimentos cirúrgicos do sistema digestório

A criação de modelos virtuais tridimensionais é uma tecnologia promissora no planejamento pré-operatório, entretanto não é utilizada no tratamento de fistulas anais. O objetivo desse trabalho é descrever o desenvolvimento e a experiência inicial da construção de um modelo virtual tridimensional da anatomia pélvica de um paciente, que permite a identificação exata das relações entre os tratos fistulosos de fistulas anais complexas e as demais estruturas pélvicas. O paciente realizou uma ressonância magnética e as imagens foram exportadas para o programa Vitrea fX software Workstation[®]. Um radiologista realizou a análise e segmentação das imagens que, em seguida, foram enviadas para um processador de imagens tridimensionais (Meshlab v. 1.3.3 – ISTI – CNR research center, Pisa University, Italy[®]). A imagem 3D colorida final foi analisada pelo cirurgião e utilizada para guiar a cateterização dos trajetos fistulosos e orifício interno e para auxiliar na identificação das estruturas adjacentes. O modelo tridimensional final apresentou alta correlação com os achados intraoperatorios e facilitou o planejamento cirúrgico.

© 2017 Sociedade Brasileira de Coloproctologia. Publicado por Elsevier Editora Ltda. Este é um artigo Open Access sob uma licença CC BY-NC-ND (<http://creativecommons.org/licenses/by-nc-nd/4.0/>).

Introduction

An anal fistula is an abnormal pathway coated with granulation tissue that connects the anal canal with the perianal skin. The objectives of its treatment are the resolution of the inflammatory process, maintenance of continence, and prevention of future recurrences.¹ Currently, the main techniques used for the treatment of complex anal fistulas are simple fistulotomy, application of fibrin glue, application of an endorectal advancement flap, video-assisted surgery, and ligation of the intersphincteric tract of the fistula.²

A good knowledge of the anatomical relationships of the anorectal fistula with the adjacent pelvic structures is essential for an adequate surgical management, which makes it possible to decrease the chance of recurrence. Magnetic resonance imaging is currently the method of choice for preoperative evaluation because it can demonstrate areas of abscess and secondary extensions of the fistula.³

Imaging studies are essential in the preoperative planning process, but they may cause doubts in interpretation by the surgeon, especially in cases of complex fistulas. In recent years, the conception of three-dimensional models has been gaining space as a promising alternative in the preoperative planning of surgeries, but this is an option yet little explored in the treatment of anal fistulas.

Objective

The present study aims to describe the development and initial experience with the construction of a three-dimensional virtual model of the patient's specific pelvic anatomy, which allows the precise identification of pathways relationships of complex fistulae for preoperative planning and surgical counseling in a tertiary hospital in the northeast of Brazil.

Methods

Initially, an MRI was performed on a Magnetom Avanto 1.5 T device (Siemens Medical System; Erlangen, Germany), with our institution's usual protocol for perianal fistulas, which included T2-weighted sequences in the axial, coronal (with an angulation for the anal canal) and sagittal planes, as well as T1-weighted post-contrast sequences, STIR and diffusion sequences, with 3-mm thick slices. The images were exported to Vitrea fX Workstation[®] software (Vital Images Corporation – Toshiba Medical Images)[®]. An experienced radiologist analyzed and did the image segmentation. The aim of the segmentation was to identify the following anatomical aspects: anal canal, levator ani musculature (external anal sphincter), internal anal sphincter muscles, fistulous paths (including internal and external orifices' positioning).

After segmentation, the images were sent in a CAD-compatible format (.STL) to a 3D image processing software (Meshlab v. 1.3.3 – ISTI – CNR Research Center, Pisa University, Italy). Colors were attributed to the different anatomical structures, in order to facilitate identification. The fistulous paths were marked in purple, levator ani muscles in red, and the rectum in blue. The final three-dimensional colored model allowed the control of rotation, zoom use, and the selection of any 3D object, individually or grouped. The software was tested in the preoperative period and applied during the surgery, in the trans-operative stage, for orientation of the surgeon both in the catheterization of the fistulous paths and the internal orifice and in the identification of the adjacent structures.

Results

Man, 52 years old, with a history of pain and anorectal secretion lasting two years. In the proctological examination,

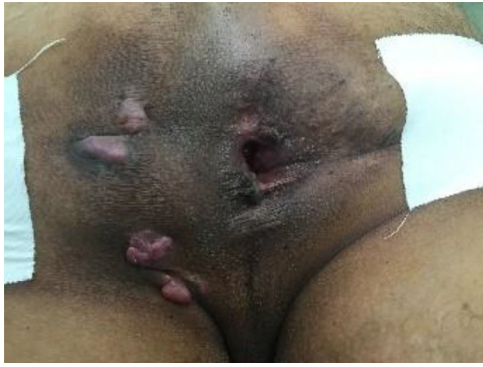

Fig. 1 – External holes in left lateroposterior and left lateroanterior quadrants.

external orifices were evident in the left lateroposterior and left lateroanterior quadrants (Fig. 1). Magnetic resonance imaging showed the presence of a complex perineal fistula, with a primary orifice from the median line in the posterior

contour, presenting a lateroanterior intersphincteric path to the left, where an abscess formation was observed; a laterally transsphincteric extension is observed, with 3 complex fistulous paths (Fig. 2). High-resolution magnetic resonance images were used to construct three-dimensional objects of the pelvic structures and fistulous paths, along with their holes (Fig. 3).

Catheterization of the fistulous paths was performed with the patient under an anesthetic block, with the opening of paths and placement of a seton into the internal orifice (Fig. 4), which was easily identified with the help of the three-dimensional platform. The surgical time was 90 minutes; the patient was discharged on the second postoperative day, with mild local pain. Currently, he is in ambulatory follow-up and to date has no signs of local fistula recurrence or of abscesses.

During the surgery, the surgeon consulted the 3D image several times for guidance on the procedure. The final three-dimensional model showed excellent quality for the viewed charts and anatomical correlation with intraoperative findings, being of great use for surgical planning, besides an important help in the trans-operative phase.

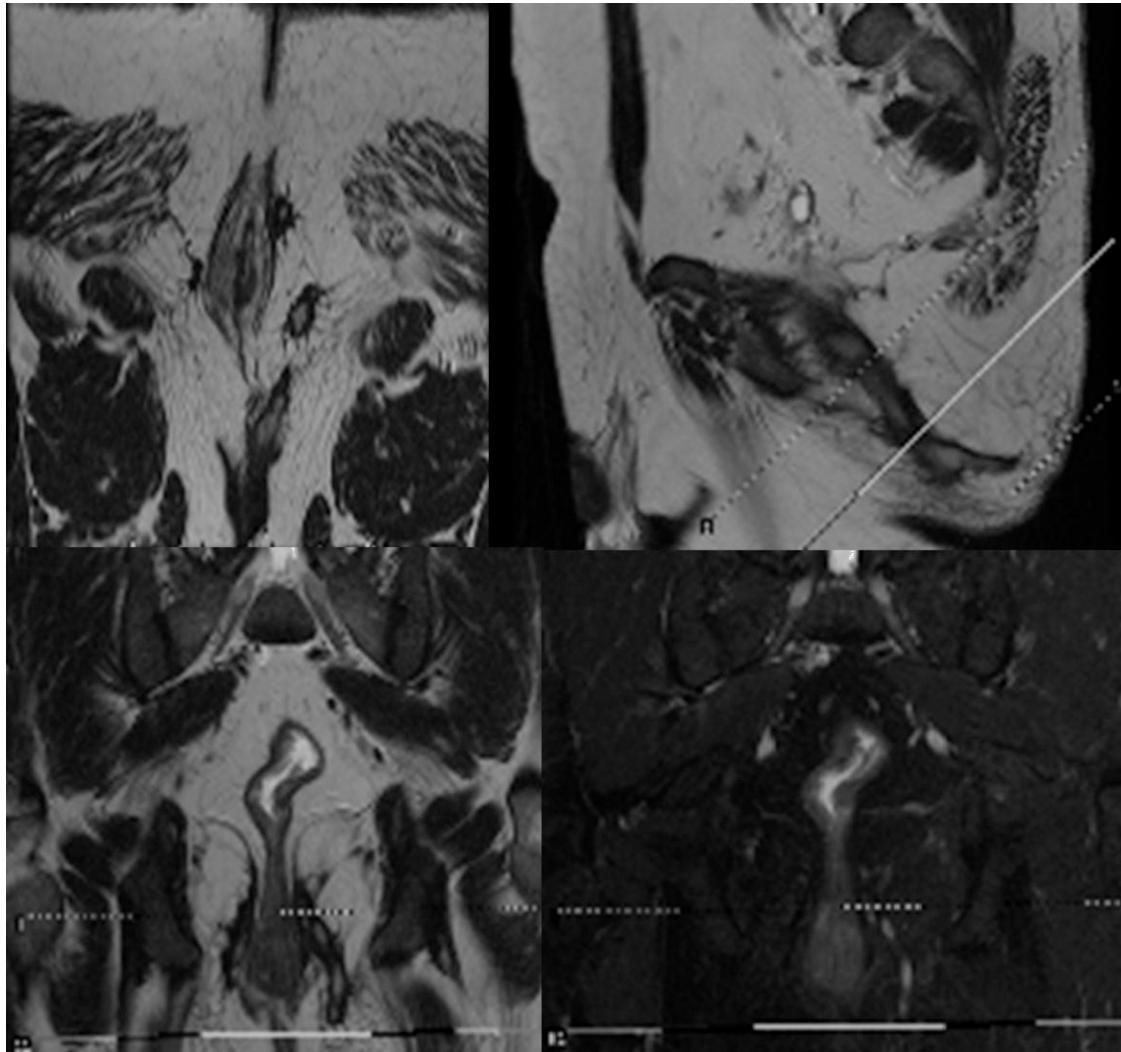


Fig. 2 – Magnetic resonance of pelvis showing 3 fistulous paths and an abscess area.

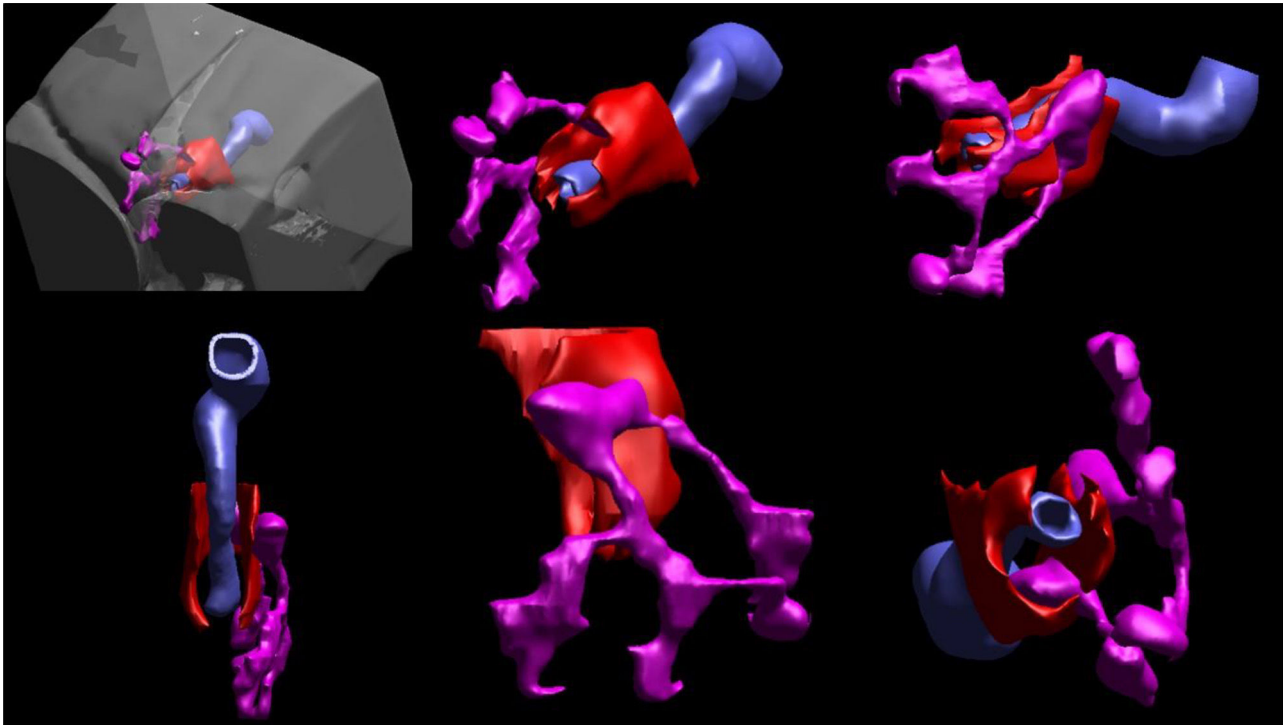


Fig. 3 - Three-dimensional final image showing fistulous paths (purple), rectum (blue) and levator ani muscles (red).

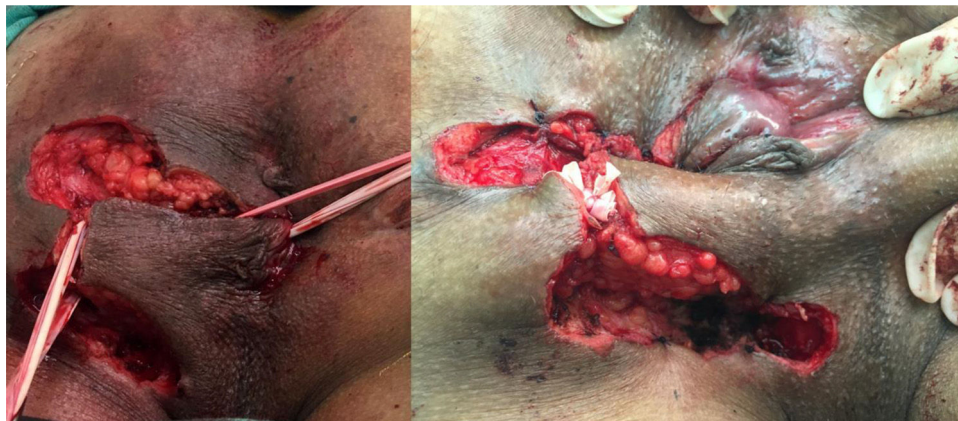


Fig. 4 - Identification of the internal orifice and placement of a sedge.

Discussion

Recurrence after therapy is the most common problem with regard to anal fistulas. To avoid recurrence after surgical treatment, detailed information on the location of all fistulous pathways and affected pelvic structures should be obtained. Imaging studies, such as magnetic resonance imaging, allow the identification of the relationships between the fistulous tracts and the other pelvic structures; in addition, they have high sensitivity and specificity for secondary fistulas, abscesses or internal orifices.⁴ While they are quite useful, conventional imaging methods have their limitations. The interpretation of relationships between fistulae and other

structures is difficult for surgeons, especially in cases of complex fistulas. Because three-dimensional reconstructions are not common in the preoperative period of perianal fistulas, the surgeon needs to create mental maps of the fistulous pathways and their relationships with other structures with the aid of 2D imaging, which hinders a correct anatomical understanding.

Three-dimensional reconstruction of complex fistulas helps the surgeon with an easy identification of secondary fistulae extensions, internal orifices, or small abscesses, which may be difficult to locate with conventional magnetic resonance imaging. In addition, this reconstruction facilitates the patient's understanding of the technical aspects of the procedure to which he will be submitted.

The use of three-dimensional imaging methods in the preoperative evaluation of patients with anal fistulas has shown positive results. A recent study of 196 patients showed that the preoperative evaluation with three-dimensional endoanal ultrasound reduces relapse after one year and decreases the occurrence of incontinence in patients with complex anal fistulas.⁵ The model described here can overcome three-dimensional endoanal ultrasound, since magnetic resonance imaging is a noninvasive technique, thus generating less discomfort for the patient. Another advantage is that the generated three-dimensional objects allow a direct and objective visualization of the full extent of the fistulous pathways, as well as their relationships with the pelvic structures.

After an extensive review of the literature, we found only one study that used the elaboration of three-dimensional models in the treatment of anal fistulas. In 2013, an English group constructed a virtual model similar to the one described in this article, with the use of magnetic resonance imaging, but with lower-quality graphics, compared to the ones obtained in the present study.⁶ The construction of this type of model has great utility in the preoperative planning in complex fistula surgeries, since it allows the surgeon to easily identify all the anatomical relationships of the fistulous paths. In addition, the described model can be easily adapted for application in various types of surgery.

The virtual model described here can also be used for the printing of three-dimensional physical structures. Several studies have demonstrated the clinical applicability of 3D printing in other types of surgery, since this technology facilitates the definition of surgical strategies in the preoperative period, improving the final results.^{7,8} Currently, this technology is little explored in Coloproctology, and there are no reports of its use in the treatment of perianal fistulas. Another advantage is that these models can be inserted into simulators and used for training. These virtual simulators allow the surgeon to apply the technique he plans to perform in a virtual model of the patient's specific anatomy. Thus, these simulators can provide a reduction in surgical time and complications, as well as being an option for the training of surgeons at the beginning of the learning curve.⁹

Conclusion

The three-dimensional reconstruction facilitates the interpretation of imaging examinations by the surgeon, improves the preoperative planning and assists in the trans-operative period, improving the results in the surgical treatment of complex anal fistulas. In addition, three-dimensional reconstruction has a potential for application in several areas.

Conflicts of interest

The authors declare no conflicts of interest.

REFERENCES

1. Dudukgian H, Abcarian H. why do we have so much trouble treating anal fistula? *World J Gastroenterol.* 2011;17:3292–6.
2. Limura E, Giordano P. Model management of anal fistula. *World J Gastroenterol.* 2015;21:12–20.
3. Liang C, Lu Y, Zhao B, Du BAY, Wang C, Jiang Imaging W. Imaging of anal fistulas: comparison of computed tomographic fistulography and magnetic resonance imaging. *Korean J Radiol.* 2014;15:712–23.
4. Vanbeckevoort D, Bielen D, Vanslebrouck R, Assche GV. Magnetic resonance imaging of perianal fistulas. *Magn Reson Imaging Clin N Am.* 2014;22:113–23.
5. Ding JH, Bi LX, Zhao K, Feng YY, Zhu J, Zhang B, et al. Impact of three-dimensional endoanal ultrasound on the outcome of anal fistula surgery: a prospective cohort study. *Colorectal Dis.* 2015;17:1104–12.
6. Day NJ, Earnshaw D, Salazar-Ferrer P, Walsh CJ. Preoperative mapping of fistula-in-ano: a new three dimensional MRI-based modelling technique. *Colorectal Dis.* 2013;15:e699–701.
7. Yao R, Xu G, Mao SS, Yang HY, Sang XT, Sun W, et al. Three-dimensional printing: review of application in medicine and hepatic surgery. *Cancer Biol Med.* 2016;13:443–51.
8. Malik HH, Darwood AR, Shaunak S, Kulatilake P, El-Hilly AA, Mulki O, et al. Three-dimensional printing in surgery: a review of current surgical applications. *J Surg Res.* 2015;199:512–22.
9. Oshiro Y, Yano H, Mitani J, Kim S, Kim J, Fukunaga K, et al. Novel 3-dimensional virtual hepatectomy simulation combined with real-time deformation. *World J Gastroenterol.* 2015;21:9982–92.