



Journal of Coloproctology

www.jcol.org.br



Technical Note

A novel four quadrant laser sphincterotomy for idiopathic severe anal stenosis



Ashwin Porwal*, Paresh Gandhi, Deepak Kulkarni

Healing Hands Clinic, Pune, India

ARTICLE INFO

Article history:

Received 9 July 2017

Accepted 3 September 2017

Available online 20 November 2017

Keywords:

Anal stenosis

Anoderm

Laser sphincterotomy

Anal stricture

Anal canal surgery

ABSTRACT

Anal stricture or stenosis, though uncommon, is disabling condition. It affects the quality of life due to pain, bleeding and difficulty in defecation, incontinence or increased frequency. It occurs when the normally pliable anoderm is replaced with fibrotic connective tissue, leading to an abnormally tight and inelastic anal canal. Mostly it occurs secondary to trauma, iatrogeny, inflammatory diseases, radiation or neoplasia. The treatment of anal stricture is generally considered to be difficult and various methods of treatment have been suggested. It is often unresponsive to conservative medical management. The surgical procedures such as dilatations and anoplasty are associated with significant complications which make it a difficult treatment challenge. Several good treatment options are available currently. Through this case, we report and explore a new medical treatment for anal strictures with four quadrant laser sphincterotomy.

© 2017 Sociedade Brasileira de Coloproctologia. Published by Elsevier Editora Ltda. This is an open access article under the CC BY-NC-ND license (<http://creativecommons.org/licenses/by-nc-nd/4.0/>).

Nova esfínterectomia a laser nos quatro quadrantes para estenose anal idiopática grave

RESUMO

A estriatura ou estenose anal, embora incomum, é problema incapacitante. Essa condição afeta a qualidade de vida por causa da dor, do sangramento e da dificuldade de defecação, de incontinência ou aumento da frequência. A estenose anal ocorre quando o anoderma, normalmente flexível, foi substituído por tecido conjuntivo fibrótico, e o resultado é um canal anal anormalmente estenosado e inelástico. Na maioria dos casos, a estenose anal ocorre secundariamente a trauma, por causa iatrogênica, por doença inflamatória, radiação ou neoplasia. Em geral, se considera que o tratamento dessa condição é tarefa difícil, tendo sido sugeridos diversos métodos de tratamento. Com frequência a estenose anal não responde ao tratamento clínico conservador. Procedimentos cirúrgicos como as dilatações

Palavras-chave:

Estenose anal

Anoderma

Esfínterectomia a laser

Estriatura anal

Cirurgia de canal anal

* Corresponding author.

E-mail: drashwinporwal@healinghandsclinic.co.in (A. Porwal).

<https://doi.org/10.1016/j.jcol.2017.09.419>

2237-9363/© 2017 Sociedade Brasileira de Coloproctologia. Published by Elsevier Editora Ltda. This is an open access article under the CC BY-NC-ND license (<http://creativecommons.org/licenses/by-nc-nd/4.0/>).

ou a anoplastia estão associados a complicações significativas, implicando difícil desafio terapêutico. Atualmente, o cirurgião conta com várias opções terapêuticas satisfatórias. No presente caso, relatamos e exploramos um novo tratamento clínico para estenoses anais, por meio da esfínterectomia a laser nos quatro quadrantes.

© 2017 Sociedade Brasileira de Coloproctologia. Publicado por Elsevier Editora Ltda. Este é um artigo Open Access sob uma licença CC BY-NC-ND (<http://creativecommons.org/licenses/by-nc-nd/4.0/>).

Introduction

Anal stenosis occurs when the normally pliable anoderm is replaced with fibrotic connective tissue, leading to an abnormally tight and inelastic anal canal. Benign anal stenosis is an uncommon, disabling and incapacitating disease. Anal stenosis occurs most commonly following any anorectal surgical procedure.¹ Stenosis produces a morphologic alteration of the anal canal and a consequent reduction of the region's functionality, leading to difficult or painful bowel movements.^{2,3} Treatment, both medical and surgical, should be modulated based on stenosis severity.^{3,4} Several research studies have been conducted on treatment of anal stenosis, but there is no universal consensus on single anoplasty procedure.³

Case report

A 55 year-old male patient, studied up to 12th standard and businessman by occupation, came with complains of incomplete evacuation of bowel since last 5 years. Symptoms aggravated over the past three years. Patient gave history of straining for stool, occasional burning in anal region, fragmented defecation and use of enema occasionally. Bowel habits were regular and 1-2/day. There was history of straining due to sense of incomplete evacuation. No history of manual evacuation of feces in past. No history of piles or fissure in past. No history of any operative procedure in the anal or perianal region. No history of mass per rectally. No history of decreased weight or appetite. No history of anemia, Diabetes or hypertension, HIV or any sexually transmitted disease or chronic use of any drug like antacid or painkiller. Patient was vegetarian with no specific food habits and there was no history of smoking and alcoholism or tobacco chewing.

On general physical and systemic examination, no systemic abnormalities were detected. On local examination, there was no evidence of external piles or fissure, no skin tag present, no evidence of swelling near anal region, no evidence of perianal infection or discharge, no evidence of prolapse. Digital rectal examination revealed evidence of stenosis, barely admitting tip of examining finger (Fig. 1). Proctoscopy was not possible because of stenosis. All routine blood investigations were within normal limits. The manometry showed ARD-38, AMD-131, APD-36 and AV-139, which was suggestive of mild muscular weakness.

Our patient was diagnosed as severe, diaphragmatic anal stenosis as per the Milson and Mazier classification.⁵ Depending upon the anal canal levels, stenosis can be classified as low stenosis (distal anal canal at least 0.5 cm below the dentate

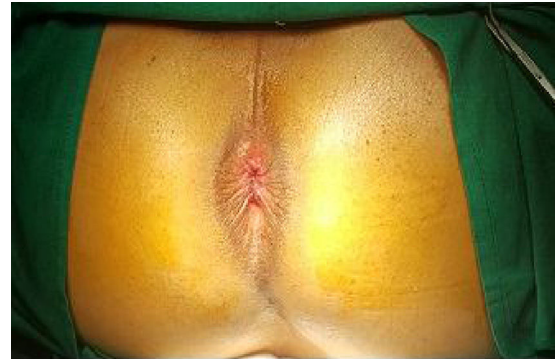

Fig. 1 – Pre-op anal stenosis.

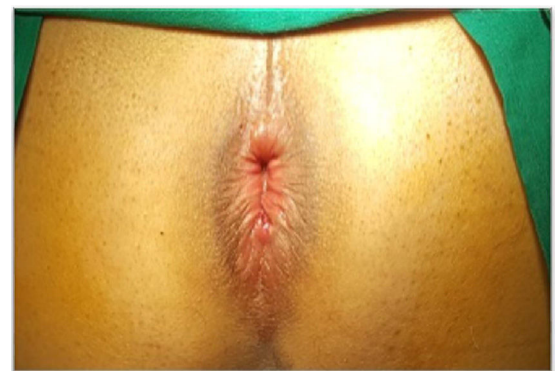


Fig. 2 – Dilated anus after four quadrant laser sphincterotomy.

line, 65% of patients), middle (0.5 cm proximal to 0.5 cm distal to the dentate line, 18.5%), high (proximal to 0.5 cm above the dentate line, 8.5%), and diffuse (all anal canal, 6.5% of cases).^{3,5} In our case it was low anal stenosis.

We planned a novel four quadrant laser sphincterotomy for this patient. Standard mechanical bowel preparation with water enemas was done before the operation to ensure cleansing of the distal rectal segment. Antibiotic prophylaxis was not used. A four quadrant laser sphincterotomy done at 2, 5, 8 and 11 O'clock position under all aseptic conditions, under saddle block, patient being in extended lithotomy position (Figs. 2 and 3). Gentle PR done with left index finger and 1470 nm Baretip fiber introduced at 2 O'clock in the direction of Internal Sphincter laterally. 150 joules of energy diverted at power of 8 W while moving the bare tip fiber from lateral to medial over internal sphincter. Same step followed at 5 O'clock, 8 O'clock and 11 O'clock. Total 600 joules of energy

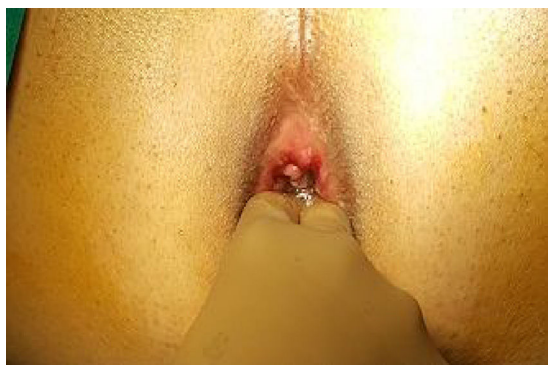

Fig. 3 – Assessment of anal dilatation post-surgery.

used at power of 8 W. Post procedure, stricture was released. It easily admitted three fingers inside (Image 3). Time taken for procedure was 20 min. Procedure was uneventful.

Patient recovered uneventfully and were discharged on stool softeners with advice for periodic dilatations during follow-up at 1 week, 3 weeks, 6 weeks, Patients was relieved of the symptoms at 6 weeks. Manometry done at 6 weeks showed keeping pressure was normal.

Discussion

Anal stenosis is loss of normal elasticity in anal canal that may lead to narrowness and rigidity with the subsequent difficulty in the dilatation required to perform the act of defecation normally. The stenotic segment may be localized to the proximal or distal anal canal. But often the irregularities are noted to be diffuse and circumferential involving the entire anal canal.⁵ An intrinsic or extrinsic pathological condition of the anorectal region leads to anal stenosis. Anal stenosis may develop in almost any condition with scarring of the anoderm.³ Almost 90 percent of anal strictures are caused by over-zealous hemorrhoidectomy.^{3,6} Inflammatory diseases of bowel may lead to anal stenosis, predominantly Crohn's disease.⁷ These kinds of stenoses are differentiated by a transmural inflammatory process leading to scarring. A disuse stenosis may occur in cases with anal fissure or due to chronic misuse of laxative.

The natural anatomical pattern of the anal canal is like upside down funnel and its diameter is lesser than the diameter of the anal verge. The internal sphincter relaxes during evacuation and cutaneous side gets dilated and allow stool pass normally. In acute anal stenosis, there is severe spasm of persistent pain which is sudden in onset. These spasms are reversible and dynamic. In our case, the anorectal passage was cylindrical. Chronic anal stenosis usually seen secondary to infections and fibrosis or surgical procedures. In chronic anal stenosis the spasms are adynamic and irreversible.^{4,7} Eventually, the anal canal gradually reduces its diameter. With improper use of laxatives regular physiologic dilatation is stopped. Gradual and irreversible fibrosis occurs in the sub-cutaneous space of the anal canal with a pathologic funnel-shaped configuration in which the diameter of the anal canal is greater than the diameter of the anal verge.³ Some-

times the anal stricture develops very slowly, it is considered as constipation rather than realizing scar tissue is blocking stool from coming out. Straining and pushing to get the stool out can cause more tearing (and as it heals, more scar tissue) along with hemorrhoids, strained rectal and anal muscles, spasm and aggravated nerves, including the pudendal nerve.⁸ In our case this could be one of the possibility. Due to straining since more than five years the stricture has been developed gradually.

Although the diagnosis of this condition is obvious and visual examination of perianal skin, anal canal along with a digital rectal examination, is generally sufficient to confirm the presence of anal stenosis, it is important to learn the cause of the stricture in order to find out appropriate therapy.

Multiple therapies with their advantages and disadvantages have been described in literature for the correction or improvement of anal stenosis or stricture.^{3,6,9-14} For planning a therapy for anal stenosis it is very important to know the severity of the disease. Moderate or severe is the usual indication for surgical treatment.

All of these flaps share the concept of an island of to treat the anal stenosis different kinds of anoplasties have been designed by using various types of flaps of nearby tissue. These anoplasties were based on the concept of an island of anoderm that is incised completely around its circumference.³ The type of flap to be used is based on the surgeon's familiarity and choice as well as the patient's anatomy and the availability of adequate perianal skin for use in the various flaps.¹ A variety of complications after anoplasty have been mentioned in studies conducted before. The more complex techniques like S-plasty, have now been discarded because of high morbidity and longer hospital stay, still easier techniques are being performed with due risk of complications.³

A study conducted by Tahamtan et al.¹⁵ recommended Y-V anoplasty with or without sphincterotomy as a treatment of anal strictures. They have also stated that selection of patients for each group would be decisive. In our case Four quadrant laser sphincterotomy was done because there was no scar of previous surgery and it was a very tight spasm. At our center, more than 500 cases of laser sphincterotomy for fissure were done with good results. With that experience in mind we thought of doing four quadrants Laser Sphincterotomy in above stricture case.

Conclusion

The predictive factors for stenosis are patient habits and previous interventions. In absence of the pre-disposing factors, possibility of idiopathic gradual anal stenosis should be kept in mind, particularly in patients who present with symptoms of ODS. Laser four quadrant sphincterotomy can be considered as a novel option to treat patients with anal stenosis, whether cause is known or unknown. This is because it has shortest operating time, fast recovery, negligible postoperative complications and immediate return to work and complete relief from symptoms.

Though further research is necessary in this regard with randomized controlled trials, we recommend Laser four quadrant Sphincterotomy for treatment of severe anal stenosis.

Conflicts of interest

The authors declare no conflicts of interest.

REFERENCES

1. Sheikh SH, Jahan I, Rahman MR, Matubber MM. V-Y anoplasty for iatrogenic anal stenosis: our initial experience in BSMMU. *Bangladesh Med J*. 2013;42:51-4.
2. Owen HA, Edwards DP, Khosraviani K, Phillips RK. The house advancement anoplasty for treatment of anal disorders. *J R Army Med Corps*. 2006;152:87-8.
3. Brisinda G, Vanella S, Cadeddu F, Marniga G, Mazzeo P, Brandara F, et al. Surgical treatment of anal stenosis. *World J Gastroenterol*. 2009;15:1921-8.
4. Liberman H, Thorson AG. How I do it – anal stenosis. *Am J Surg*. 2000;179:325-9.
5. Milson JW, Mazier WP. Classification and management of postsurgical anal stenosis. *Surg Gynecol Obstet*. 1986;163:60-4.
6. Brisinda G. How to treat haemorrhoids. Prevention is best; haemorrhoidectomy needs skilled operators. *BMJ*. 2000;321:582-3.
7. Khubchandani IT. Anal stenosis. *Surg Clin N Am*. 1994;74:1353-60.
8. What Is Anal Stenosis and Strictures. Available from: <http://www.listentoyourgut.com/symptoms/33/anal-stenosis-and-strictures.html>.
9. Maria G, Brisinda G, Civello IM. Anoplasty for the treatment of anal stenosis. *Am J Surg*. 1998;175:158-60.
10. Esfahani MN, Madani G, Madhkhan S. A novel method of anal fissure laser surgery: a pilot study. *Lasers Med Sci*. 2015;30:1711-7.
11. Nickell WB, Woodward ER. Advancement flaps for treatment of anal stricture. *Arch Surg*. 1972;104:223-4.
12. Lagares-Garcia JA, Nogueras JJ. Anal stenosis and mucosal ectropion. *Surg Clin N Am*. 2002;82:1225-31.
13. Casadesus D, Villasana LE, Diaz H, Chavez M, Sanchez IM, Martinez PP, et al. Treatment of anal stenosis: a 5-year review. *ANZ J Surg*. 2007;77:557-9.
14. Singh S, Shah I, Sharma A, Watali Y, Masoodi O, Rayees S. Anal stenosis following sclerotherapy managed by anoplasty. *JK Sci J Med Educ Res*. 2014;16:92-3.
15. Tahamtan M, Ghahramani L, Khazraei H, Tabar YT, Bananzadeh A, Hosseini SV, et al. Surgical management of anal stenosis: anoplasty with or without sphincterotomy. *J Coloproctol*. 2016;37:13-7.