

## The role of Bronchoalveolar lavage in Interstitial Lung Diseases



Dear Editor,

Interstitial Lung Diseases (ILD) are a group of diseases characterized by bilateral involvement of lung parenchyma, acutely or chronically, which have different degrees of fibrosis and tissue inflammation and which occur in immunocompetent hosts, without infection or neoplasia.<sup>1</sup>

Bronchoalveolar lavage (BAL) is a useful diagnostic tool for ILD.<sup>2-4</sup> The cellular profile obtained by BAL, in association with medical history, physical examination and imaging findings, may support or help narrowing the probable diagnosis hypothesis.<sup>1,3</sup>

We have conducted a retrospective observational study, in a pulmonology department of a university hospital, collecting demographic, clinical and laboratory data, consulting the clinical process of patients undergoing BAL on suspicion of ILD, during a period of 3 years and 7 months. The statistical analysis was performed using SPSS 20®.

The study included 188 patients, of whom, 125 had a definitive diagnosis of interstitial lung disease. The average age was 54.5 years old and 56% of patients were male.

In this study, it was our purpose to analyze both the alveolar cellular profile of the main interstitial lung diseases and the impact of the BAL in the initial diagnosis which was suggested by clinical features and high resolution computed tomography (HRCT).

Cellular analysis of BAL revealed BAL neutrophilia in patients with connective tissue associated ILD (ILD-CTD) and in patients with idiopathic pulmonary fibrosis (IPF) with a differential cellular count of 21% and 20%, respectively (Fig. 1). Neutrophilia and eosinophilia are more common in BAL of ILD that are characterized by fibrosis (as a whole, Idiopathic interstitial fibrosis), which match the results obtained.<sup>5,6</sup> Significant lymphocytosis was observed in BAL of patients with sarcoidosis, hypersensitivity pneumonitis, cryptogenic organizational pneumonitis, pneumoconiosis and non-specific interstitial pneumonia, who presented differential cellular count of 48.0%, 47.7%, 38.6%, 37.3% and 33.5%, respectively (Fig. 1).

ILDs characterized by a granulomatous pattern, such as hypersensitivity pneumonitis and sarcoidosis, are characterized by an increase in lymphocytes number, with variable neutrophilia and occasionally eosinophilia (Fig. 1).<sup>5</sup>

However, as observed in the obtained results, idiopathic interstitial pneumonias such as cryptogenic organizing pneumonia (COP) and nonspecific interstitial pneumonia (NSIP) also have lymphocytosis in BAL (Fig. 1).<sup>1,2,4</sup> In our study, patients with NSIP had mostly a cellular-form of the disease which may explain the BAL lymphocytosis profile in this group.

Lymphocytosis superior to 15% in BAL diminishes the probability of idiopathic pulmonary fibrosis (IPF) and may shift differential diagnosis towards other entities: NSIP, COP or chronic HP.<sup>6,7</sup>

In COP, usually, there is an increase in the number of lymphocytes (up to 40%), an increase of neutrophils (mainly in early stages of disease) and eosinophils (Fig. 1).<sup>7</sup>

It was established that the contribution of BAL to the final diagnosis could present, for each patient, one of the following possible results:

- Confirm the initial diagnosis - the BAL result made the definitive diagnosis or was highly suggestive of the initial diagnosis, with no further examinations needed;
- Support the initial diagnosis - the BAL result was consistent with the initial diagnosis, but other procedures were required to confirm it;
- Suggest another diagnosis - the BAL result suggested another diagnosis, leading the investigation into another way;
- Exclude the initial diagnosis - the BAL result was inconsistent with the initial diagnosis hypothesis or established, definitively, another diagnosis;
- No contribution - the BAL result had no diagnostic value to the investigation of the disease under study;

BAL confirmed the diagnosis, initially based on clinical and radiological data, in 60% of patients with pneumoconiosis, 45% of patients with hypersensitivity pneumonitis and 35% of patients with sarcoidosis. It also made it possible to exclude the diagnosis of IPF in 12% of patients.

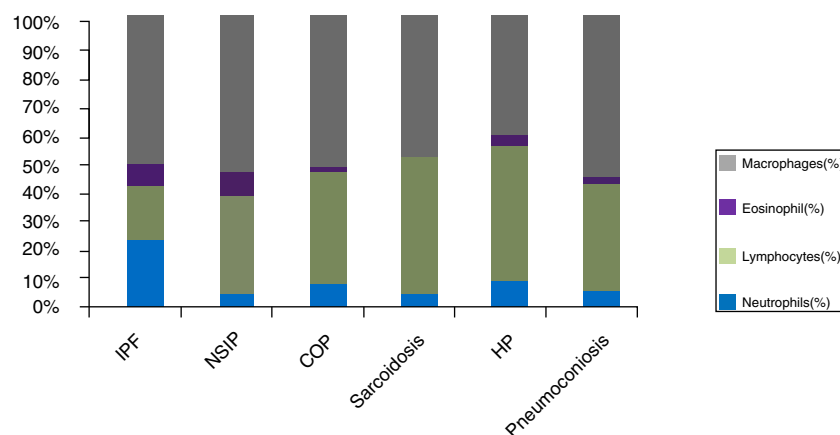
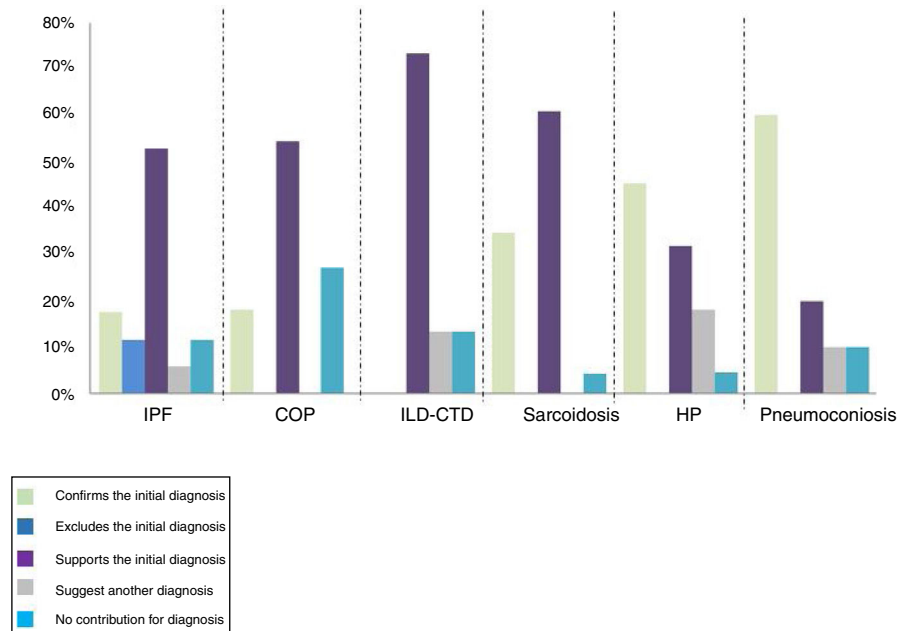


Figure 1 ILD: alveolar cellular profile.



**Figure 2** Comparison between the number of patients with initial and final diagnosis of ILD.

BAL did not contribute to the final diagnosis in 8% of the total patients (Fig. 2).

There were statistically significant differences in COP ( $z = -3.61$ ,  $p < .001$ ), in sarcoidosis ( $z = -4.6$ ,  $p < .001$ ), in PH ( $z = 5.01$ ,  $p < .001$ ), in CTD-ILD ( $z = -3.2$ ,  $p = .001$ ), in IPF ( $z = -3.4$ ,  $p = .001$ ) and in vasculitis ( $z = -2.2$ ,  $p = .025$ ), suggesting that, in these group of diseases, BAL revealed a greater contribution in the diagnosis.

BAL significant lymphocytosis (>40%) is expected in most patients with HP and, in appropriate clinical/radiological setting, may confirm the diagnosis. In our study, only in less than half of HP patients was BAL the determinant. This may be explained by a high proportion (>50%) of patients with chronic forms of the disease with extensive interstitial fibrosis and therefore with lower BAL lymphocyte count. In these patients differential diagnosis with other interstitial fibrotic diseases (like IPF) is problematic and multidisciplinary discussion is mandatory.

We conclude that BAL in our setting, played an important role in the diagnostic evaluation of different ILD, in carefully selected patients and under a multidisciplinary approach.

## Conflict of interests

The authors have no conflicts of interest to declare.

## References

1. Meyer KC, Raghu G, Baughman RP, Brown KK, Costabel U, du Bois RM, et al. An official American Thoracic Society clinical

practice guideline: the clinical utility of bronchoalveolar lavage cellular analysis in interstitial lung disease. *American journal of respiratory and critical care medicine*. 2012;185:1004–14, <http://dx.doi.org/10.1164/rccm.201202-0320ST>.

2. Capelozzi VL, Faludi EP, Balthazar AB, Fernezlían Sde M, Filho JV, Parra ER. Bronchoalveolar lavage improves diagnostic accuracy in patients with diffuse lung disease. *Diagnostic cytopathology*. 2013;41:1–8, <http://dx.doi.org/10.1002/dc.21743>. Epub 2011 Jun 14.
3. Wuyts WA, Doooms C, Verleden GM. The clinical utility of bronchoalveolar lavage cellular analysis in interstitial lung disease. *American journal of respiratory and critical care medicine*. 2013;187:777.
4. Meyer KC, Raghu G. Bronchoalveolar lavage for the evaluation of interstitial lung disease: is it clinically useful? *The European respiratory journal*. 2011;38:761–9, <http://dx.doi.org/10.1183/09031936.00069509>.
5. Wells AU. The clinical utility of bronchoalveolar lavage in diffuse parenchymal lung disease. *European respiratory review: an official journal of the European Respiratory Society*. 2010;19:237–41, <http://dx.doi.org/10.1183/09059180.00005510>.
6. Pesci A, Ricchiuti E, Ruggiero R, De Micheli A. Bronchoalveolar lavage in idiopathic pulmonary fibrosis: what does it tell us? *Respiratory medicine*. 2010;104 Suppl 1:S70–3, <http://dx.doi.org/10.1016/j.rmed.2010.03.019>.
7. American Thoracic Society/European Respiratory Society International Multidisciplinary Consensus Classification of the Idiopathic Interstitial Pneumonias. This joint statement of the American Thoracic Society (ATS), and the European Respiratory Society (ERS) was adopted by the ATS board of directors, June 2001 and by the ERS Executive Committee, June 2001. *American journal of respiratory and critical care medicine*. 2002;165:277–304, <http://dx.doi.org/10.1164/ajrccm.165.2.ats01>.

M. Costa e Silva<sup>a</sup>, R. Rolo<sup>b</sup>

<sup>a</sup> Serviço de Pneumologia, Centro Hospitalar de Gaia/Espinho, Vila Nova de Gaia, Portugal

<sup>b</sup> Serviço de Pneumologia, Hospital de Braga, Braga, Portugal

1 June 2017 5 September 2017 15 October 2017

<https://doi.org/10.1016/j.rppnen.2017.10.003>  
2173-5115/

© 2017 Sociedade Portuguesa de Pneumologia. Published by Elsevier España, S.L.U. This is an open access article under the CC BY-NC-ND license (<http://creativecommons.org/licenses/by-nc-nd/4.0/>).

## The role of endobronchial ultrasound-guided transbronchial needle aspiration in the diagnosis of lymphoproliferative disorders



Dear Editor,

Endobronchial ultrasound-guided transbronchial needle aspiration (EBUS-TBNA) is a minimally invasive bronchoscopic technique included in the initial diagnostic workup of mediastinal and hilar lymphadenopathy and masses of unknown etiology.<sup>1,2</sup>

The value of EBUS-TBNA in the diagnosis of lymphoproliferative disorders (LPD) is not well established.<sup>1-8</sup> LPD diagnosis requires lymph node sampling for pathologic and flow cytometry analysis. Are the samples obtained by EBUS-TBNA good enough to provide the diagnosis of LPD?

The usefulness of EBUS-TBNA in the diagnosis of LPD in patients with lymph nodes or mediastinal masses and clinical suspicion of LPD was evaluated.

One hundred and eighty nine patients underwent EBUS-TBNA to investigate the etiology of MLN between 2009 and 2012. The suspicion of LPD was based on past history of lymphoma or clinical manifestations and associated with unexplained lymph nodes. EBUS-TBNA biopsies were performed under general anesthesia. The ecoendoscope used was the Olympus-BF-TYPE-UC-180F, with a convex transducer (7.5MHz) and integrated Doppler mode. A dedicated

22-gauge needle (NA-2015X-4022-Olympus) was used to perform TBNA. The ultrasound processor was Olympus-EU-ME1. At least 3 or 4 punctures were made in each target station without rapid on-site cytology. Immunohistochemistry and flow cytometry were requested on all samples. The sample was considered adequate if lymphocytes, antracosis or a specific diagnosis was identified. A true positive diagnosis was made if there was a positive biopsy consistent with lymphoma by EBUS-TBNA or on subsequent follow-up by another method within 6 months. A true negative diagnosis was considered with a negative biopsy and stability or regression of the lymph nodes over a period of at least 6 months.

6.9% (13) patients had clinical suspicion of LPD. 61.5% were male, with mean age of  $58.4 \pm 15.9$  years. Nine patients had enlarged mediastinal lymph nodes and four mediastinal masses.

The EBUS-TBNA results were: three LPD, two granulomatous disease, four reactive lymph nodes and four inadequate samples. Among patients with non-diagnostic results (8), 37.5% (3) had LPD: one patient repeated EBUS-TBNA, one underwent a mediastinoscopy and one patient was diagnosed with LPD by peripheral lymph node biopsy. The diagnosis of reactive lymph node was confirmed in three patients after clinical and radiological monitoring (Table 1).

The diagnosis of LPD was established in six patients. The sensitivity, negative predictive value and diagnostic accuracy of EBUS-TBNA in the diagnosis of LPD were 50, 70 and 76.9%, respectively.

In the literature, the yield of EBUS-TBNA in patients with lymphoma is not well defined with variable results;

**Table 1** Endobronchial ultrasound needle aspiration results and method of final diagnosis in 13 patients with mediastinal lymph node with suspicion of lymphoma.

Patient no.	EBUS-TBNA diagnosis	Other procedure	Definitive diagnosis
# 1	Hodgkin lymphoma	-	Hodgkin lymphoma
# 2	B-cell lymphoma	-	Non-Hodgkin lymphoma
# 3	Hodgkin lymphoma	-	Hodgkin lymphoma
# 4	Reactive lymph node	Peripheral lymph node biopsy	Non-Hodgkin lymphoma
# 5	Inadequate sample	Mediastinoscopy	Hodgkin lymphoma
# 6	Reactive lymph node	Repeat EBUS-TBNA	Non-Hodgkin lymphoma
# 7	Inadequate sample	Repeat EBUS-TBNA	Reactive lymph node
# 8	Inadequate sample	Repeat EBUS-TBNA	Reactive lymph node
# 9	Granulomatous disease	-	Tuberculosis
# 10	Granulomatous disease	-	Sarcoidosis
# 11	Inadequate sample	Clinical/Radiological monitoring - resolution	Reactive lymph node
# 12	Reactive lymph node	Clinical/Radiological monitoring - resolution	Reactive lymph node
# 13	Reactive lymph node	Clinical/Radiological monitoring - resolution	Reactive lymph node