



Reprodução & Climatério

<http://www.sbrh.org.br/revista>



Case report

Hysteroscopic uterine perforation with complete uterine septum resection

Ahmed Samy El-Agwany

Department of Obstetrics and Gynecology, Faculty of Medicine, Alexandria University, Alexandria, Egypt

ARTICLE INFO

Article history:

Received 31 December 2015

Accepted 9 March 2016

Available online xxx

Keywords:

Ultrasound

Laparoscopy

Perforation

Hysteroscopy

Septate uterus

ABSTRACT

Septate uterus is caused by incomplete resorption of the Mullerian duct during embryogenesis. Here, we report a case of septate uterus that was initially diagnosed by hysterosalpingography and ultrasound scan that was successively treated by hysteroscopic resection but it was complicated with uterine perforation and was confirmed by laparoscopy. Operative hysteroscopic procedures are risky than diagnostic ones. Half the complications were entry-related. The other half of complications were related to surgeons' experience and type of procedure.

© 2016 Sociedade Brasileira de Reprodução Humana. Published by Elsevier Editora Ltda.

This is an open access article under the CC BY-NC-ND license

(<http://creativecommons.org/licenses/by-nc-nd/4.0/>).

Perfuração uterina histeroscópica com ressecção completa de septo uterino

RESUMO

O útero septado é causado pela reabsorção incompleta do duto de Muller durante a embriogênese. Nesse artigo, relatamos um caso de útero septado que, inicialmente, tinha sido diagnosticado por histerossalpingografia e ultrassonografia e que foi sucessivamente tratado por ressecção histeroscópica; mas esse caso foi complicado por perfuração uterina confirmada por laparoscopia. Os procedimentos histeroscópicos operatórios representam maiores riscos, em comparação com os procedimentos diagnósticos com essa técnica. Metade das complicações tinha ligação com a introdução. A outra metade das complicações estava relacionada à experiência dos cirurgiões e ao tipo de procedimento.

© 2016 Sociedade Brasileira de Reprodução Humana. Publicado por Elsevier Editora Ltda.

Este é um artigo Open Access sob a licença de CC BY-NC-ND

(<http://creativecommons.org/licenses/by-nc-nd/4.0/>).

Palavras-chave:

Ultrassom

Laparoscopia

Perfuração

Histeroscopia

Útero septado

E-mail addresses: ahmedsamyagwany@gmail.com, ahmed.elagwany@alexmed.edu.eg

<http://dx.doi.org/10.1016/j.recli.2016.03.001>

1413-2087/© 2016 Sociedade Brasileira de Reprodução Humana. Published by Elsevier Editora Ltda. This is an open access article under the CC BY-NC-ND license (<http://creativecommons.org/licenses/by-nc-nd/4.0/>).

Introduction

Uterine anomalies can lead to infertility among women. The prevalence of uterine anomalies is about 0.5%.¹ Acien, in a review study, found a mean incidence for septate uterus 22% (complete septate 9%, partial septate 13%) among other types of mullarian defects.² Septate uterus is the most common uterine malformation^{3,4} and is characterized by a muscular or fibrous wall, called the septum. Subtypes are partial septum (sub-septate uterus) involves the endometrial canal but not the cervix, septum is considered “complete” if it extends to either the internal or external cervical os and septum extends into the vagina is septate uterus and vagina. It is diagnosed by medical image techniques, i.e. hysterosalpingography (HSG), ultrasound or magnetic resonance imaging (MRI). With operative hysteroscopy increasing as a surgical alternative for various gynecologic problems, there is heightened awareness of potential complications associated with it as fluid overload, caused by excessive absorption of distention medium and surgical complications from intrauterine manipulation of instruments as uterine perforation.⁵

Case report

A 25 year old lady, G0P0, was admitted to Shatby maternity university hospital. She was infertile for 3 years. Her menstrual history was normal. There was no family history of any abnormalities related to uterus. She had done HSG that revealed complete uterine septum (Fig. 1). Ultrasound was performed showing septate uterus with no adnexal masses. Hysteroscopy was performed revealing complete septum extending to the internal cervical os (Fig. 2) that was resected (Fig. 3) by 90 degree needle electrode till both tubal ostia were visible at same plane but uneventfully uterine perforation (Fig. 4) occurred, so laparoscopy was done to cauterize the perforation

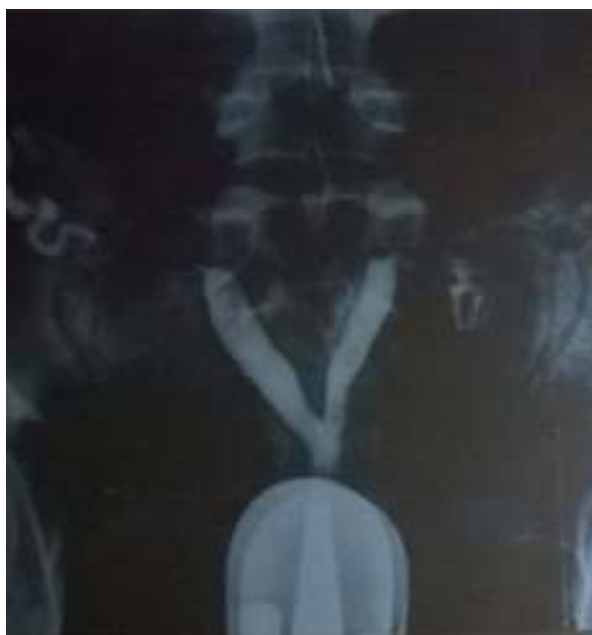

Fig. 1 – HSG showing complete uterine septum.

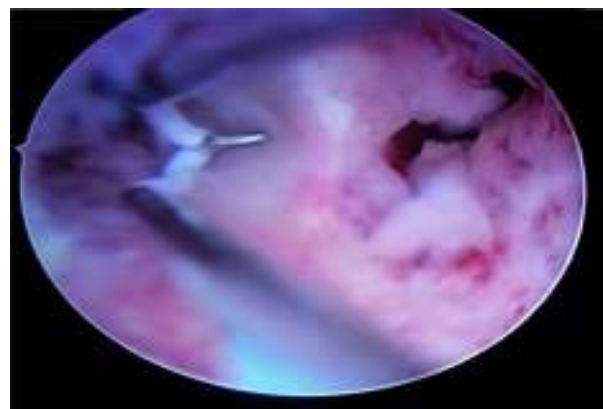


Fig. 2 – Hysteroscopic view with both cavities seen.

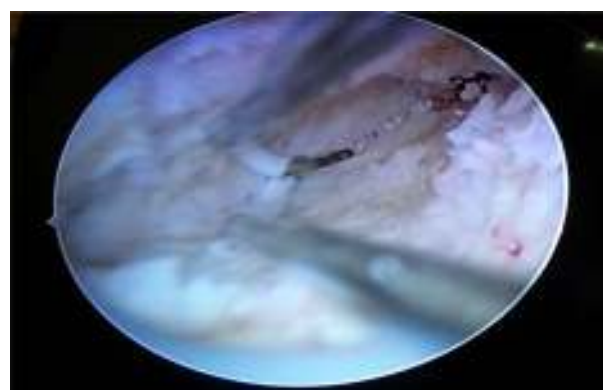


Fig. 3 – Resection of the uterine septum.

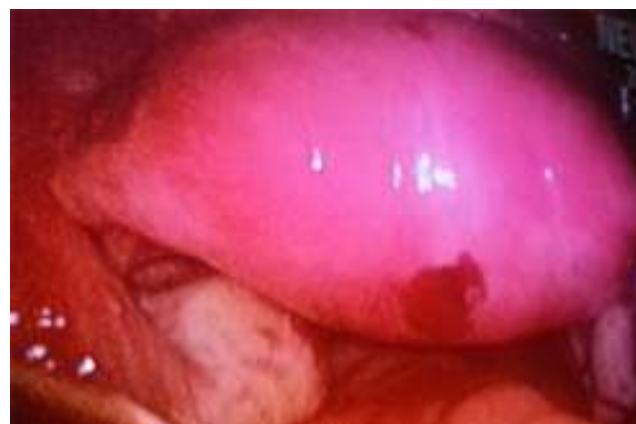

Fig. 4 – Uterine perforation on laparoscopy.

area and inspect the bowel with other organs for diathermy lesions. The postoperative period was smooth and the patient was discharged after 2 days. She was instructed to deliver by elective cesarean section.

Discussion

Uterine anomalies, as uterine septum, may cause repetitive abortions. A symptomatic uterine septum is best treated with hysteroscopy even in virgins with abnormal uterine bleeding.

The uterine septum may be of different lengths and widths involving only the corporeal portion of the uterus or extending into the cervix and rarely the vagina.⁵

Hysteroscopic treatment provides a less invasive approach to divide the uterine septum. The treatment offers minimal discomfort to the patient as well as minimal morbidity, as it can be performed on an outpatient basis. Because the uterine wall is not divided, a subsequent cesarean section is required only for obstetrical indications except if perforation is encountered. The healing with reepithelialization of the uterine cavity takes only 4–5 weeks, and patients are allowed to conceive sooner than with abdominal metroplasty. Hospitalization is not required so expenses are markedly reduced. Three hysteroscopy methods can be used to divide the uterine septum. The mechanical method using rigid scissors, the resectoscope as in our case, and the fiberoptic laser. The most commonly used method for treatment of the uterine septum is with a monopolar hook using the resectoscope. The fibrotic consistency of the septum permits this division without significant bleeding and the procedure is performed systematically dividing the septum in the middle from base to top, having as landmarks both uterotubal junctions and the translucency of the hysteroscopic light seen by the assistant utilizing a laparoscope with dimmed or no light. Systematic, delicate, shallow cuts should be performed in order to observe at all times the symmetry of the uterine cavity. The use of bipolar cutting devices permits to distention of the uterine cavity with saline solutions. Bipolar vaporizing electrodes permit the use of electrolyte containing fluids.⁶ Another method of hysteroscopic division of septum is to use semi rigid hysteroscopic scissors through the working channel of the diagnostic hysteroscope. When using the monopolar hook of the resectoscope only fluids devoid of electrolytes can be used to avoid conduction.⁷ Finally, fiberoptic lasers can be used also to divide the septum, as Nd:YAG, KTP or argon lasers. Fluids with electrolyte media can be used as lasers do not produce conductive energy.⁸

Unfortunately, accurate data concerning complication rate are hard to obtain, but over the years the complication rate has been decreasing. This has been demonstrated by improvements in equipment and experience of the surgeons. In two multicentric interviews of the American Association of Gynaecologic Laparoscopists performed by Hulka, the severe complication rate decreased from 1% to 0.2% in 3 years.⁹ The patients should be aware of the risks and provided with an informed consent. Uterine perforation most commonly occurs during septal resection, myomectomy surgery and adhesiolysis. However it can occur even in a simple diagnostic hysteroscopy. With appropriate care, this sort of perforation should not happen, because the cervix, internal os, and cavity should be negotiated under direct vision. The most dangerous perforations are those with lasers and electro-surgical devices. The incidence of injury can be reduced by not activating the energy device during thrusting forward movement. If a

perforation does happen with laser or electro-surgical electrode, then laparoscopy or laparotomy is required to ensure no injury has been inflicted to bladder, bowel, or ureter. The operator knows that perforation has occurred as it becomes difficult to maintain the distention. Simultaneous laparoscopy while performing operative hysteroscopy acts as a safeguard against risk of uterine perforation. If perforation is suspected due to a non-energy instrument, strict observation of the women postoperatively is mandatory. Rarely, vessel injury can occur when uterus is perforated, unexplained falling blood pressure along with inability to maintain distention should alert the operator. Women who have uterine perforation during operative hysteroscopy are at increased risk of uterine rupture during pregnancy. If any patient feels ill after 10–20 h with constant blood pressure, a bowel lesion may be suspected and an immediate laparoscopy must follow.⁹

In conclusion, the diagnosis of septate uterus as a congenital anomaly can be achieved easily with HSG, US and MRI. It can be corrected by hysteroscopic surgery and thereby decreases the rate of abortion for women greatly with low incidence of uterine perforation according to skill of the operator and extent of lesion.

Conflicts of interest

The author declares no conflicts of interest.

REFERENCES

1. Nahum GG. Uterine anomalies. How common are they, and what is their distribution among subtypes? *J Reprod Med.* 1998;43:877–87.
2. Acién P. Incidence of Müllerian defects in fertile and infertile women. *Hum Reprod.* 1997;12:1372–6.
3. Favez JA. Comparison between abdominal and hysteroscopic metroplasty. *Obstet Gynecol.* 1986;68:399–403.
4. Raga F, Bauset C, Remohi J, Bonilla-Musoles F, Simón C, Pellicer A. Reproductive impact of congenital Müllerian anomalies. *Hum Reprod.* 1997;12:2277–81.
5. Valle RF. Clinical management of uterine factors in infertile patients. In: Speroff L, editor. *Seminars in reproductive endocrinology*, vol. 3, no. 2. New York, NY: Thieme-Stratton, Inc. Georg Thieme Verlag; 1985. p. 149–67.
6. March CM, Isreal R. Hysteroscopic management of recurrent abortion caused by septated uterus. *Am J Obstet Gynecol.* 1987;156:834–42.
7. DeCherney AH, Russell JB, Graebe RA, Polan ML. Resectoscopic management of mullerian fusion defects. *Fertil Steril.* 1986;45:726–8.
8. Choe JK, Baggish MS. Hysteroscopic treatment of septated uterus with neodymium-YAG laser. *Fertil Steril.* 1992;57:81–4.
9. Hulka JF, Peterson HB, Phillips JM, Surrey MW. Operative hysteroscopy. American Association of Gynaecologic Laparoscopists 1991 membership survey. *J Reprod Med.* 1993;38:572–3.