



Sociedad Española
de Reumatología -
Colegio Mexicano
de Reumatología

Reumatología Clínica

www.reumatologiaclinica.org



Case Report

Raynaud's Phenomenon in Children[☆]

Elena Ortega Vicente,^{*} Mercedes Garrido Redondo

Medical specialist, Pediatrics, CS Tórtola, Valladolid, Spain



ARTICLE INFO

Article history:

Received 9 June 2015

Accepted 18 August 2015

Available online 14 October 2016

Keywords:

Raynaud's phenomenon

Pediatrics

Paleness

Blush

Cyanosis

Capillaroscopy

ABSTRACT

Raynaud's phenomenon is caused by spasm of the small arteries and arterioles of the fingers. It is triggered by various stimuli including exposure to cold or a stressful event. It may be symmetrical or wrap one end. The appearance of this entity in children is rare.

We report the case of a 4 year old male consultation health center by episodes of coldness, pallor and pain in both feet.

© 2015 Elsevier España, S.L.U. and Sociedad Española de Reumatología y Colegio Mexicano de Reumatología. All rights reserved.

Palabras clave:

Fenómeno de Raynaud

Pediatría

Palidez

Rubor

Cianosis

Capilaroscopia

Fenómeno de Raynaud en pediatría

RESUMEN

El fenómeno de Raynaud está causado por vasoespasmo de las pequeñas arterias y arteriolas de los dedos. Se desencadena por diversos estímulos, entre ellos la exposición al frío o un evento estresante. Puede ser simétrico o envolver una sola extremidad. La aparición de esta entidad en niños es muy infrecuente.

Presentamos el caso de un varón de 4 años que consulta en su centro de salud por episodios de frialdad, palidez y dolor en ambos pies.

© 2015 Elsevier España, S.L.U. y Sociedad Española de Reumatología y Colegio Mexicano de Reumatología. Todos los derechos reservados.

Introduction

Raynaud's phenomenon was first described in an adult in 1862. It is classically defined as a series of changes in the color of the fingers and/or toes which occur in three distinct phases: first a phase of pallor (white), followed by a cyanotic phase (blue) and, finally, hyperemia (red).

Not all the patients experience these three phases; in most cases, there is a single phase in which the color of the skin of the fingers or toes changes to a typically bluish color known as acrocyanosis, a circumstance that makes diagnosis more difficult. In contrast to Raynaud's phenomenon, acrocyanosis is a relatively common

finding in infants and small children, and consists of bilateral, symmetrical discoloration of the hands and feet; it is a benign and self-limiting process that does not require treatment. Only in rare cases is acrocyanosis in children caused by Raynaud's phenomenon and, when this occurs, it needs immediate medical attention in order to prevent complications.

Case Report

We present the case of a boy aged 4 years and 10 months who was brought to his health center after having had episodes of cold, pallor and pain in both feet.

The family history included a 43-year-old father who had undergone removal of a benign gallbladder polyp, a healthy 42-year-old mother, 4 healthy older siblings, and paternal grandparents diagnosed with type 2 diabetes mellitus. The patient had been born in a vaginal delivery, after a normal, monitored pregnancy. His ponderal index at birth was in the 75th–90th percentile. He had no

[☆] Please cite this article as: Ortega Vicente E, Garrido Redondo M. Fenómeno de Raynaud en pediatría. Reumatol Clin. 2016;12:342–344.

^{*} Corresponding author.

E-mail address: elenaovicente@gmail.com (E. Ortega Vicente).

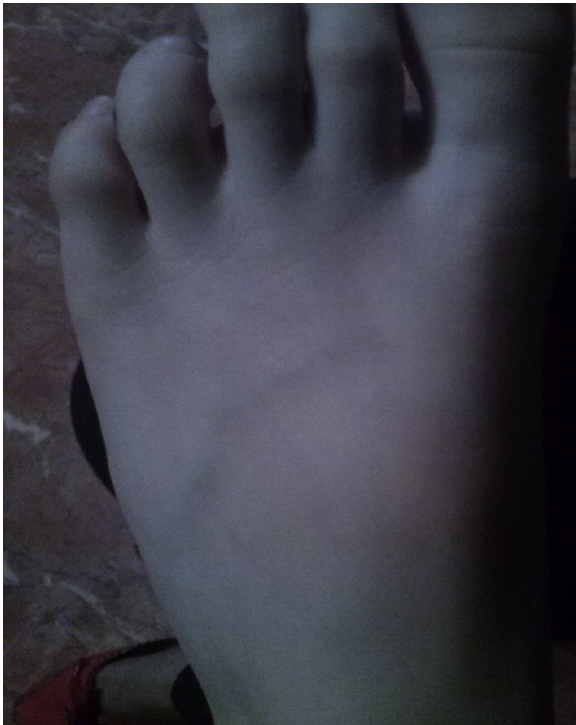

Fig. 1. Skin pallor during an episode.

known allergies. At the age of 2 months, he had been hospitalized for acute otitis media. He was up to date with the immunization schedule of his Spanish autonomous community.

The patient had been brought to his health center after having experienced several episodes of pallor and a sensation of cold, followed by flushing, in both feet up to his ankles, which was accompanied by intense pain lasting approximately 30 min. The episodes were not related to abrupt changes in temperature, and the signs disappeared progressively with massage and local warming (Figs. 1 and 2).

Physical examination during that visit revealed no evidence of discoloration, nor were any anomalies found on palpation of symmetrical distal pulses.

As these clinical signs led us to suspect Raynaud's phenomenon, we referred the patient to pediatric rheumatology, where blood tests, including liver and kidney function, and microbiological and autoantibody studies were found to be normal.

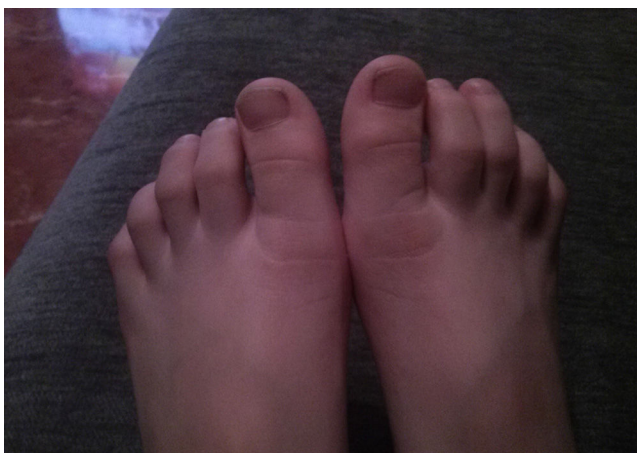


Fig. 2. Phase of erythema in both feet.

In the vascular surgery unit, he underwent a Doppler ultrasound study of digital forward flow, which was normal. On qualitative capillaroscopy, there was no evidence of dilation, tortuosity or branching, and capillary function was normal; quantitative assessment of capillaries by capillaroscopy was also normal.

Given that the results of all the studies were normal, the patient was discharged from the hospital. At the present time, the episodes are more sporadic. They continue to subside with massage and local warming, and have no impact on the child's daily activities.

Discussion

The diagnosis in the case described in this article was Raynaud's phenomenon, based on the clinical course, the results of supplemental tests and the exclusion of other causes.

Raynaud's phenomenon is caused by vasospasm of the small arteries and arterioles of the fingers and toes. It is triggered by a number of stimuli, including exposure to cold or emotional stress. It can be symmetrical or involve an extremity on only one side. It is attributed mainly to hyperactivity of the sympathetic nervous system, together with an imbalance between vasodilator and vasoconstrictor substances. A number of studies have reported that the cutaneous nerve endings of patients diagnosed with Raynaud's phenomenon show an inadequate release of a potent vasodilator, the calcitonin-gene related peptide. This primary disorder may become more pronounced when associated with other factors, such as cold or emotional stress, which would trigger a cascade of compounds involved in vasoconstriction, such as catecholamines, endothelin-1, and 5-hydroxytryptamine. These mediators could be the ultimate cause of the endothelial damage seen in more severe cases.

Some studies have suggested that high blood levels of homocysteine may be associated with Raynaud's phenomenon because of its role, as an atherosclerotic factor, in reducing vasodilation.

Raynaud's phenomenon appears to have a strong familial component, which has led to the undertaking of genetic studies that have not yet been concluded. It is classified as:

- Secondary Raynaud's phenomenon: Normally, there is a well-defined primary disease, such as a connective tissue disease (systemic lupus erythematosus, polyarteritis nodosa or scleroderma), repeated trauma (work involving vibratory tools), drugs (interferon α , bleomycin), infections, metabolic diseases (cryoglobulinemia, atherosclerosis), exposure to chemical agents (tobacco, plastics), CREST (calcinosis, Raynaud's phenomenon, esophageal dysmotility, sclerodactyly and telangiectasia), etc. It is associated with a high morbidity rate, and can even produce gangrene in the fingers or toes. It requires chronic treatment and the results of ancillary tests usually show alterations, including autoantibody positivity and anomalies observed in capillaroscopy, which reveals giant capillaries with irregular architecture and, in some cases, an avascular area.
- Primary Raynaud's phenomenon (previously referred to as Raynaud's disease): It presents in the absence of other diseases and the course is usually benign. The findings on capillaroscopy are normal and tests for antinuclear antibodies (ANA) are negative, features that differentiate it from secondary Raynaud's phenomenon.

Raynaud's phenomenon is extremely rare in children; the first report of this disease in children was in 1967, almost exactly 100 years after the initial description, in 1862. In general, according to published series, girls are more predisposed to develop Raynaud's phenomenon and the onset occurs during the changes observed around menarche, due to the influence of hormones.

The largest cohort studied, published in 2003, involving 123 children with Raynaud's phenomenon, demonstrated that there is marked heterogeneity in terms of patient age, disease presentation and symptoms; for example, exposure to cold was the major trigger in the majority of the cases (roughly 70%) but, in 10%, no trigger was identified.¹ Primary Raynaud's phenomenon had a bimodal presentation, affecting young children and adolescents, and a considerable number of children, the majority under 2 years of age, were initially diagnosed as having acrocyanosis. The clues that should lead us to suspect Raynaud's phenomenon, rather than acrocyanosis, include the presence of atypical features, like a duration of more than 72 h and/or unilateral cyanosis.^{2,3}

Management of this disease is generally supportive and is based on an accurate diagnosis. Mild forms can be controlled by hygienic measures, such as the avoidance of exposure to cold or stressful situations, with no need for drug therapy. Moderate to severe cases require vasodilator therapy, such as systemic or topical calcium channel blockers. In very severe cases, intravenous infusion of prostacyclin, endothelin-1 receptor antagonists, inhibitors of phosphodiesterase-5, antiplatelet agents and antithrombotic therapy are being used with variable results. Surgery is reserved for extreme cases in which there is no response to the different drug therapies, and consists of digital sympathectomy.

In recent years, new treatments are being investigated, including selective alpha-2c adrenergic receptor blockers, protein kinase inhibitors and calcitonin gene-related peptide.^{4,5}

In patients with secondary Raynaud's phenomenon, specific treatment of the underlying disease is critical for controlling the episodes.

Our patient appears to have primary Raynaud's phenomenon in its mildest form, as indicated by the clinical findings and the results of the tests performed. As we mentioned above, the treatment is supportive and consists in avoiding exposure to intense cold and situations of major stress. We think it is important to point out these cases, as this disease is rare in children and difficult to

diagnose because the duration of the episodes is usually limited and, most of them are not evaluated by a physician. Thus, we wish to stress how important it is that the family take photographs during an episode, and we encourage professionals to consider Raynaud's phenomenon when dealing with similar cases.

Ethical Disclosures

Protection of human and animal subjects. The authors declare that no experiments were performed on humans or animals for this study.

Confidentiality of data. The authors declare that they have followed the protocols of their work center on the publication of patient data.

Right to privacy and informed consent. The authors declare that no patient data appear in this article.

Conflicts of Interest

The authors declare they have no conflicts of interest.

References

1. Nigrovic PA, Fuhlbrigge RC, Sundel RP. Raynaud's phenomenon in children: a retrospective review of 123 patients. *Pediatrics*. 2003;111:715.
2. Summers A. From white to blue to red: Raynaud's phenomenon. *Emergency Nurse*. 2005;13:18–20.
3. Sharathkumar AA, Castillo-Caro P. Primary Raynaud's phenomenon in an infant: a case report and review of literatura. *Pediatr Rheum*. 2011;9:16.
4. Sekiyama J, Camargo C, Andrade LE, Kayser C. Comparison of wide field nailfold capillaroscopy and videocapillaroscopy in de assessment of the microcirculation in patients with Raynaud's Phenomenon. *Arthritis Rheum*. 2011;63:1457.
5. Piotta DGP, Hilario MOE, Carvalho NS, Len CA, Andrade LE, Terreri MT. Prospective nailfold capillaroscopy evaluation of Raynaud's phenomenon in children and adolescents. *Acta Reumatol Port*. 2013;38:114–21.