

(TNF) antibody, and lacks the Fc fragment. Therefore, CZP crosses the placenta by passive diffusion more than by active transport utilizing FcRn, and, thus, the placental transfer of CZP must be minimal.⁷ Likewise, although it cannot be explained by the FcRn system, observations on the levels of etanercept in umbilical cord have demonstrated that the rate of placental transfer is very low.⁸ Mahadevan et al.,⁹ showed that concentrations of infliximab and adalimumab, but not CZP, are greater in umbilical cord than in maternal serum; mean levels of infliximab and adalimumab in cord reach concentrations between 150% and 160% greater than the concentrations in maternal serum.⁹

There are other circumstances in which placental transfer of antibodies after weeks 20–22 can be detrimental to the fetus/neonate. Typically, in cases of rheumatoid arthritis and systemic lupus erythematosus, the passage of anti-Ro/SSA and/or anti-La/SSB autoantibodies of IgG isotype can cause an eruption due to exposure to the sun or the development of congenital heart block, which affects roughly 2% of fetuses/neonates of patients who have these autoantibodies.⁶

With the lack of data on the safety of mAb, the performance of clinical trials in pregnant patients is ruled out for ethical considerations, and the decision to use them would depend in each case on the clinical situation, as well as that of the potential benefits and risks for the mother, fetus or newborn. Long-term observational studies would enable us to confirm the efficacy and safety of category B mAb during pregnancy, to determine whether gestational exposure to mAb involves a long-term risk for the immune system being developed in the newborn, or should this vary depending on the trimester for exposure. It is important to consider that the administration of vaccines with alive or attenuated virus or bacteria, an indication that is present in certain vaccine calendars for newborns, for example, with bacillus Calmette-Guérin (BCG), with which, infection can have a fatal outcome.¹⁰ For these reasons, it is recommendable that they be postponed until the sixth month of life.

Conflicts of Interest

LV: Abbvie, Roche Farma, Bristol-Myers Squibb, Pfizer, UCB, MSD and GSK; JGOB: nothing to declare; DHF: nothing to declare;

FJLL: Abbvie, Roche Farma, Bristol-Myers Squibb, Pfizer, UCB and MSD.

References

- Hazes JM, Coulie PG, Geenen V, Vermeire S, Carbonnel F, Louis E, et al. Rheumatoid arthritis and pregnancy: evolution of disease activity and pathophysiological considerations for drug use. *Rheumatology (Oxford)*. 2011;11:1955–68.
- Wylie AM. PART 71 – designation of Class A, Class B, Class C, Class D, and agency action. *Federal Register*. 2008;73:18–55.
- Hyrich KL, Symmons DP, Watson KD, Silman AJ. Pregnancy outcome in women who were exposed to anti-tumor necrosis factor agents: results from a national population register. *Arthritis Rheum*. 2006;54:2701–2.
- Katz JA, Antoni C, Keenan GF, Smith DE, Jacobs SJ, Lichtenstein GR. Outcome of pregnancy in women receiving infliximab for the treatment of Crohn's disease and rheumatoid arthritis. *Am J Gastroenterol*. 2004;99:2385–92.
- Simister NE. Placental transport of immunoglobulin G. *Vaccine*. 2003;21:3365–9.
- Palmeira P, Quinello C, Silveira-Lessa AL, Zago CA, Carneiro-Sampaio M. IgG placental transfer in healthy and pathological pregnancies. *Clin Dev Immunol*. 2012;2012, <http://dx.doi.org/10.1155/2012/985646>. Epub 2011 Oct 1.
- Chaparro M, Gisbert JP. Transplacental transfer of immunosuppressants and biologics used for the treatment of inflammatory bowel disease. *Curr Pharm Biotechnol*. 2011;12:765–73.
- Berthelsen BG, Fjeldsoe-Nielsen H, Nielsen CT, Hellmuth E. Etanercept concentrations in maternal serum, umbilical cord serum, breast milk and child serum during breastfeeding. *Rheumatology (Oxford)*. 2010;49:2225–7.
- Mahadevan U, Wolf DC, Dubinsky M, Cortot A, Lee SD, Siegel CA, et al. Placental transfer of anti-tumor necrosis factor agents in pregnant patients with inflammatory bowel disease. *Clin Gastroenterol Hepatol*. 2013;11:286–324.
- Cheent K, Nolan J, Shariq S, Kiho L, Pal A, Arnold J. Case report: fatal case of disseminated BCG infection in an infant born to a mother taking infliximab for Crohn's disease. *J Crohns Colitis*. 2010;4:603–5.

Lara Valor^{a,b,*} Juan Gabriel Ovalles-Bonilla^{a,b}
Diana Hernández-Flórez^{a,b} Francisco Javier López-Longo^{a,b}

^a *Servicio de Reumatología, Hospital General Universitario Gregorio Marañón, Madrid, Spain*

^b *Instituto de Investigación Biomédica del Hospital Gregorio Marañón, Madrid, Spain*

* Corresponding author.

E-mail address: lvalor.hgugm@salud.madrid.org (L. Valor).

Polymyositis in a Patient With Ulcerative Colitis[☆]



Polimiositis en un paciente con colitis ulcerosa

Dear Editor,

Ulcerative colitis (UC) is an inflammatory disease that affects the colorectal mucosa in a diffuse form, continuously and superficially.¹ Polymyositis (PM) belongs to the spectrum of idiopathic inflammatory myopathies, and is differentiated from dermatomyositis (DM) because of the absence of the characteristic skin rash.² Muscle involvement in the form of PM has rarely been described in UC. We report the case of a patient who was initially diagnosed as having UC, and developed PM over the course of his disease. We also review cases published to date. Our patient was a 46-year-old man, an ex-smoker, who presented with persistent bloody diarrhea with no other associated symptoms, and was diag-

nosed with UC. At the age of 58 years, he presented with an episode of pain and swollen hands, and was too weak to climb stairs. Laboratory tests detected increases in creatine kinase (CK) (1578 U/L) and lactate dehydrogenase (LDH) (506 U/L), although all other inflammatory parameters were normal. The rest of the biochemical study, including complete blood count, showed normal values. The immunological study demonstrated the presence of antinuclear antibodies, at a titer of 1/160, and negative tests for anti-extractable nuclear antigens (ENA), anti-DNA antibodies, antineutrophil cytoplasmic antibodies (ANCA), anti-centromere antibodies, anti-Scl-70 and antibodies specific for myositis (Jo-1, PL7, PL12, OJ, EJ, SRP, Pm-Scl, Mi2 and Ku). A muscle biopsy of quadriceps was performed (Fig. 1), and evidenced variability in the size of the muscle fibers, with some necrotic fibers, regenerative basophilic fibers and frequent mononuclear inflammatory cell infiltrates, mostly lymphocytic and located in the endomysium. The expression of the major histocompatibility complex class I antigens was positive in the muscle fibers, all of which was compatible with the diagnosis of PM. Treatment was begun with a tapering dose of prednisone starting at 20 mg/day, to be followed by methotrexate (maximum dose 25 mg/week), and normalization of the CK and LDH levels was achieved after 16 months of treatment.

[☆] Please cite this article as: González García A, Sifuentes-Giraldo WA, Diz Fariña S, Pian H. Polimiositis en un paciente con colitis ulcerosa. *Reumatol Clin*. 2016;12:360–362.

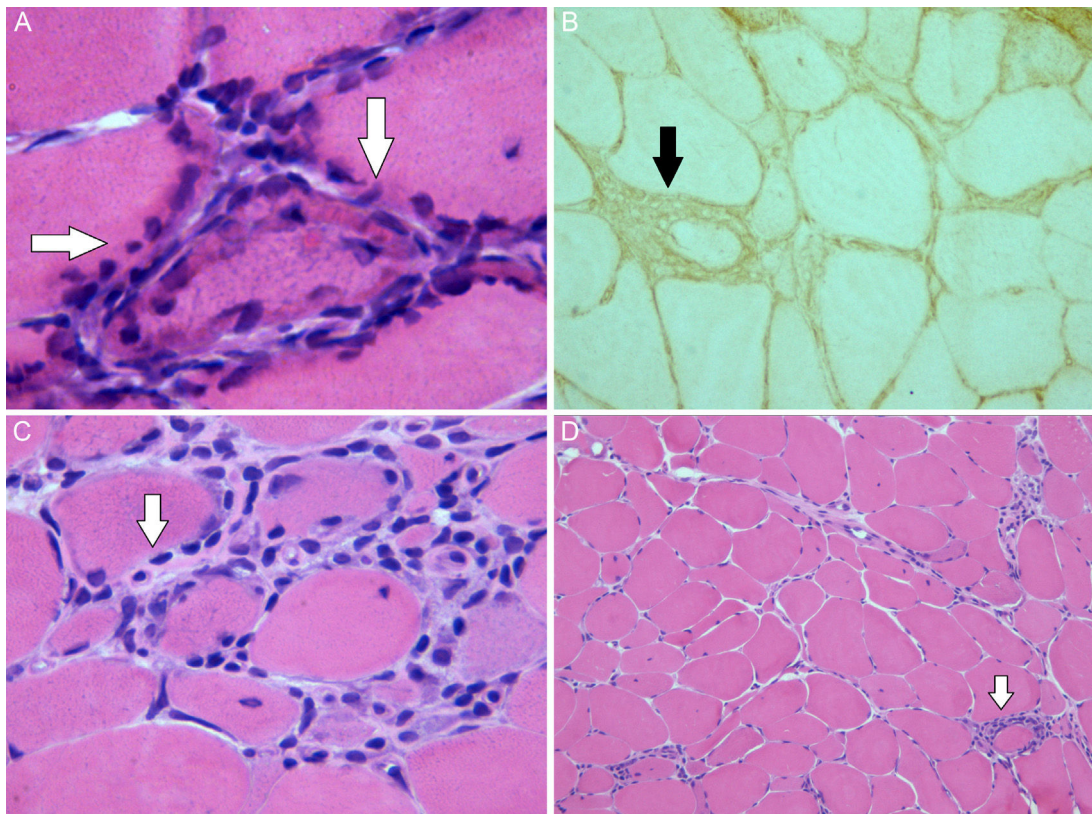


Fig. 1. Image of the muscle biopsy: (A) There are muscle fibers with regenerative peripheral basophilic areas (hematoxylin–eosin stain $\times 63$). (B) Muscle expression of the class I antigens of the human leukocyte antigen (HLA) system. (C) There is an endomysial lymphocyte cell infiltrate located in the (hematoxylin–eosin stain $\times 40$). (D) Variability of the size of the muscle fibers and perimysial (hematoxylin–eosin stain $\times 10$).

Table 1
Characteristics of the Patients With Polymyositis Associated With Ulcerous Colitis.

Authors [Ref]	Sex	Age (years)	Associated defects	AAB	Time between the diagnosis of UC and the development of PM	Muscle groups affected	Extramuscular manifestations	Treatment	Outcome
Hernández et al. ³	M	11	HLA-B27 (–) Sacroiliitis	No	Simultaneous	Regions proximal to extremities and neck flexors	No	Oral prednisone 1.5 mg/kg/day	Improvement of muscle manifestations
Evrard et al. ⁴	M	33	Not associated chronic liver disease	No	4 years earlier	Lower extremities	Fever	Oral sulfasalazine 1.5 g/day Betamethasone enemas	Improvement of bowel and muscle manifestations
Kaneoka et al. ⁵	W	57	Not associated liver cirrhosis	ANA 1/160 RF (+)	11 years earlier	Torso and regions proximal to extremities and neck flexors	No	Oral prednisolone 40 mg/day	UC quiescent, PM with moderate activity. Death due to liver failure
Chugh et al. ⁶	W	78	Esophagitis and erosive gastritis	No	15 years earlier	Torso and regions proximal to extremities and neck flexors	Polyarthralgia	Oral prednisolone 40 mg/day Oral 5-aminosalicylic acid 400 mg/8 h Prednisolone enemas	UC in remission, improvement of muscle manifestations
Voigt et al. ⁷	W	33	–	ANA 1:2.560 Anti-DNA (+)	4 years earlier	Regions proximal to extremities	No	IV prednisolone 200 mg/day for 7 days, followed by oral prednisone 60 mg/day	UC quiescent, PM in remission

AAB, autoantibodies; ANA, antinuclear antibodies; CK, creatine kinase; IV, intravenous; M, man; PM, polymyositis; Ref, reference; RF, rheumatoid factor; UC, ulcerative colitis; W, woman.

Muscle involvement in inflammatory bowel disease is uncommon; in fact, only 7 cases associating PM and UC have been published to date^{3–9} (Table 1). Only in the patient we describe was the diagnosis reached because of the increase in muscle enzymes. The response to glucocorticoid treatment was so good, in general, except in an individual who was refractory to several immunosuppressive agents and whose disease entered remission with mycophenolate mofetil.⁹ It has been suggested that the basis for the development of PM in UC results from the common immune-mediated mechanism, in which bowel inflammation and the damage to the mucosa would lead to a release of antigens, stimulating the production of antibodies that would damage the muscle. In conclusion, the development of PM in UC should be taken into account, especially when these patients describe symptoms such as myalgia, muscle weakness or present an increase in muscle enzymes. Although there are few cases reported in the literature, it may be underdiagnosed given that the symptoms may be few and not very specific, and can be attributed to other causes.

Conflict of Interest

The authors declare they have no conflict of interest directly or indirectly related to the contents of this manuscript.

References

1. Ford AC, Moayyedi P, Hanauer SB. Ulcerative colitis. *BMJ*. 2013;346:f432.
2. Bohan A, Peter JB. Polymyositis and dermatomyositis (first of two parts). *N Engl J Med*. 1975;292:344–7.

3. Hernández MA, Díez Tejedor E, Barbado J, Morales C. Polymyositis and ulcerative colitis. A new form of association? *Neurología*. 1986;1:134–5 [Article in Spanish].
4. Evrard P, Lefebvre C, Brucher JM, Coche E. Myositis associated with ulcero-hemorrhagic rectocolitis. Apropos of a case. *Acta Gastroenterol Belg*. 1987;50:675–9.
5. Kaneoka H, Iyadomi I, Hiida M, Yamamoto K, Kisu T, Tokunaga O, et al. An overlapping case of ulcerative colitis and polymyositis. *J Rheumatol*. 1990;17:274–6.
6. Chugh S, Dilawari JB, Sawhney IM, Dang N, Radotra BD, Chawla YK. Polymyositis associated with ulcerative colitis. *Gut*. 1993;34:567–9.
7. Voigt E, Griga T, Tromm A, Henschel MG, Vorgerd M, May B. Polymyositis of the skeletal muscles as an extraintestinal complication in quiescent ulcerative colitis. *Int J Colorectal Dis*. 1999;14:304–7.
8. Paoluzi OA, Crispino P, Rivera M, Iacopini F, Palladini D, Consolazione A, et al. Skeletal muscle disorders associated with inflammatory bowel diseases: occurrence of myositis in a patient with ulcerative colitis and Hashimoto's thyroiditis – case report and review of the literature. *Int J Colorectal Dis*. 2006;21:473–7.
9. Schneider C, Gold R, Schafers M, Toyka KV. Mycophenolate mofetil in the therapy of polymyositis associated with a polyautoimmune syndrome. *Muscle Nerve*. 2002;25:286–8.

Andrés González García,^{a,*} Walter Alberto Sifuentes-Giraldo,^b Sergio Diz Fariña,^a Héctor Pian^c

^a Servicio de Medicina Interna, Hospital Universitario Ramón y Cajal, Madrid, Spain

^b Servicio de Reumatología, Hospital Universitario Ramón y Cajal, Madrid, Spain

^c Servicio de Anatomía Patológica, Hospital Universitario Ramón y Cajal, Madrid, Spain

* Corresponding author.

E-mail address: andres.gonzalez.garcia@hotmail.com (A. González García).

Spondylodiscitis Without Endocarditis Caused by *Streptococcus mitis*[☆]



Espondilodiscitis sin endocarditis causada por *Streptococcus mitis*

To the Editor,

Spondylodiscitis is an infection of an intervertebral disc and the vertebrae. Its incidence is on the rise in recent years. The causative microorganism in most adult patients is *Staphylococcus aureus*. To date, *Streptococcus* species have had little relevance as causative agents of vertebral osteomyelitis. However, the number of cases caused by these microorganisms has increased in recent years.¹ We report the case of a patient with spondylodiscitis caused by *Streptococcus mitis*.

The patient was a 49-year-old man, an ex-smoker, with nothing else remarkable in his clinical history. He presented with a 4-week history of low back pain with inflammatory features and pain that radiated down his left leg. He did not have associated fever or metabolic syndrome. There was no evidence of skin lesions, either, and he did not consume farmhouse dairy products. He had not undergone any dental procedures in the preceding 2 years. Notable findings in the results of laboratory tests were the absence of leukocytosis in the complete blood count and a normal differential leucocyte count, but elevation of acute-phase reactants was detected (erythrocyte sedimentation rate [ESR], 80 mm; C-reactive protein [CRP], 42 mg/L). Serological tests for human immunode-

ficiency virus and *Brucella* were negative, as was the tuberculin skin test. A radiograph of the lumbar spine revealed a slight irregularity in the vertebral endplate below L5. Magnetic resonance imaging of the lumbosacral spine disclosed signs compatible with spondylodiscitis involving L5–S1. Blood cultures were negative. A transthoracic echocardiogram showed no evidence of endocarditis. Finally, a biopsy and fine-needle aspiration cytology were performed, both under computed tomography (CT) guidance. Bacterial culture yielded colonies of *S. mitis* that were sensitive to all the different classes of antibiotics except penicillin. Four hours after the vertebral biopsy, a blood sample was again obtained for culture, in which *S. mitis* was also isolated. Treatment consisted of intravenous ceftriaxone for 3 weeks, followed by another 3 weeks with oral levofloxacin. The patient responded well to the treatment, with resolution of the clinical signs and normalization of the acute-phase reactants.

To date, 7 cases of spondylodiscitis caused by *S. mitis* have been reported in the English-language literature^{1–3} (PubMed: Spondylodiscitis and *S. mitis* 1969–2015). *S. mitis*, which belongs to the group of viridans streptococcal species, forms part of the commensal flora of the mouth and nasal sinuses and is a rare cause of spondylodiscitis. Spondylodiscitis is uncommon in adults. The predisposing factors are diabetes mellitus, malnutrition, intravenous drug use, immunodeficiency, neoplasms, prolonged glucocorticoid therapy, chronic kidney disease and cirrhosis. It usually presents with inflammatory back pain, which can be accompanied by fever and clinical signs of a systemic disorder.² In contrast to spondylodiscitis caused by *S. aureus* and by streptococci from a group other than viridans, that attributed to viridans streptococci has a more subacute course, with less systemic involvement. For this reason, the diagnostic delay is usually longer. The majority of the patients with infection caused by this microorganism present with infective endocarditis, as well. Thus, performance of echocar-

[☆] Please cite this article as: Prior-Español Á, Mateo L, Martínez-Morillo M, Riveros-Frutos A. Espondilodiscitis sin endocarditis causada por *Streptococcus mitis*. *Reumatol Clin*. 2016;12:362–363.