

Sonia Martín Guillén,^a Antonio Álvarez de Cienfuegos,^b
Roberto Hurtado García^{c,*}

^b Sección de Reumatología, Servicio de Medicina Interna, Hospital Vega Baja de Orihuela (Alicante), Spain
^c Servicio de Medicina Interna, Hospital Vega Baja de Orihuela (Alicante), Spain

^a Servicio de Medicina Interna, Hospital Vega Baja de Orihuela (Alicante), España, Residente de Medicina de Familia y Atención Comunitaria, Spain

* Corresponding author.
E-mail address: robeltx2@gmail.com (R. Hurtado García).

Treatment With Monoclonal Antibodies and Pregnancy in Women With Systemic Inflammatory Diseases: A Special Situation[☆]



Una situación especial: tratamiento con anticuerpos monoclonales y embarazo en mujeres con enfermedades inflamatorias sistémicas

Dear Editor:

Pregnancy is a situation of semi-allogenic immunological tolerance with regard to the fetus. The mechanisms of tolerance are described as uterine changes induced by the syncytiotrophoblast over: cytokines, T and natural killer (NK) lymphocytic subpopulations and complement, as well as the presence of human leukocyte antigen (HLA)-C class II, HLA-E and HLA-G. Moreover, systemic immunological changes are also produced: thymic involution through progesterone, decreased NK activity and a change toward an anti-inflammatory profile of cytokines (T helper cells [Th2]).¹

Monoclonal antibodies (mAb) have revolutionized the treatment of autoimmune and inflammatory diseases, so frequent among women of childbearing age. Therefore, their utilization before or during pregnancy, is sometimes proposed, as a question of clinical practice. The mAb used, at the present time, are not apt for utilization during pregnancy² and there are no controlled studies

in pregnant women. According to the United States Food and Drug Administration (FDA), these mAb are classified as category B (infliximab), as are their biosimilars, adalimumab, etanercept, golimumab and certolizumab pegol [CZP]), and as C (rituximab, tocilizumab and abatacept). There have been no significant differences in the rate of abortions among patients exposed to infliximab and naïve patients.^{3,4}

To understand the process of placental transfer of mAb would help us to evaluate the risk of beginning or maintaining their administration during pregnancy. Nutrients are transferred to the fetus through a maternal layer of syncytiotrophoblasts and another of endothelium (fetal capillaries) by simple diffusion or using transport proteins. Toxins are returned by the fetus to the maternal circulation to be eliminated. Composed of low molecular weight (<500 Da), like O₂ and amino acids, they diffuse passively through the placenta, but those with a high molecular weight require transport proteins to cross it. Immunoglobulin G (IgG) has a molecular weight of 160 kDa and crosses the placenta through the neonatal Fc receptor (FcRn) present in the syncytiotrophoblast cells.^{5,6}

The structure of most of the mAb utilized contains a constant region of IgG1 (Fc) and, during the first 20–22 weeks of pregnancy, there is a minimal active transfer because of the absence of FcRn. Transport across the placenta increases significantly toward the third trimester of the pregnancy (Fig. 1). Certolizumab pegol contains a PEGylated Fab fragment of the anti-tumor necrosis factor

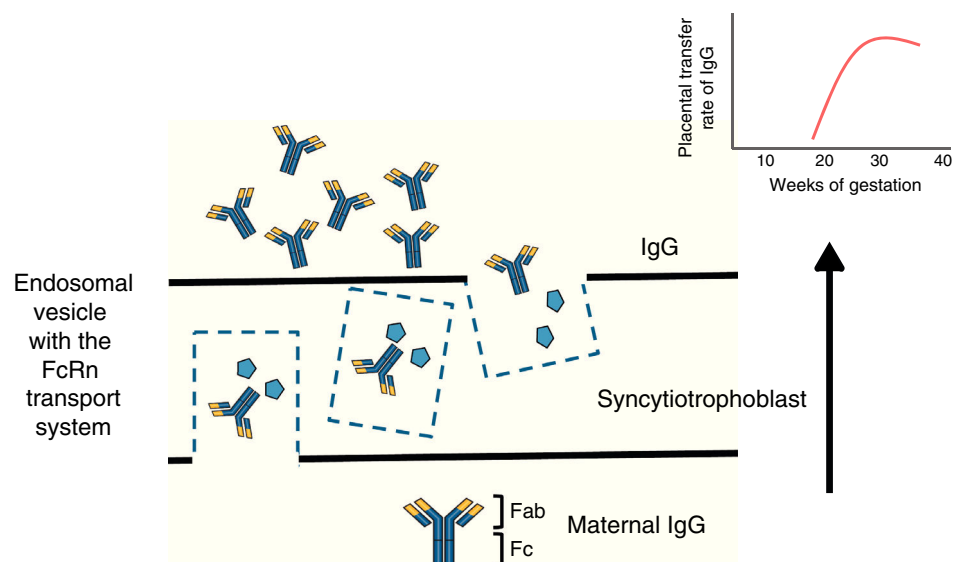


Fig. 1. Immunoglobulin G crosses the placental barrier through the FcRn transport system, present in the syncytiotrophoblast cells. Fab, variable region; Fc, constant region of the immunoglobulin; FcRn, neonatal Fc receptor; IgG, immunoglobulin G.

[☆] Please cite this article as: Valor L, Ovalles-Bonilla JG, Hernández-Flórez D, López-Longo FJ. Una situación especial: tratamiento con anticuerpos monoclonales y embarazo en mujeres con enfermedades inflamatorias sistémicas. Reumatol Clin. 2016;12:359–360.

(TNF) antibody, and lacks the Fc fragment. Therefore, CZP crosses the placenta by passive diffusion more than by active transport utilizing FcRn, and, thus, the placental transfer of CZP must be minimal.⁷ Likewise, although it cannot be explained by the FcRn system, observations on the levels of etanercept in umbilical cord have demonstrated that the rate of placental transfer is very low.⁸ Mahadevan et al.,⁹ showed that concentrations of infliximab and adalimumab, but not CZP, are greater in umbilical cord than in maternal serum; mean levels of infliximab and adalimumab in cord reach concentrations between 150% and 160% greater than the concentrations in maternal serum.⁹

There are other circumstances in which placental transfer of antibodies after weeks 20–22 can be detrimental to the fetus/neonate. Typically, in cases of rheumatoid arthritis and systemic lupus erythematosus, the passage of anti-Ro/SSA and/or anti-La/SSB autoantibodies of IgG isotype can cause an eruption due to exposure to the sun or the development of congenital heart block, which affects roughly 2% of fetuses/neonates of patients who have these autoantibodies.⁶

With the lack of data on the safety of mAb, the performance of clinical trials in pregnant patients is ruled out for ethical considerations, and the decision to use them would depend in each case on the clinical situation, as well as that of the potential benefits and risks for the mother, fetus or newborn. Long-term observational studies would enable us to confirm the efficacy and safety of category B mAb during pregnancy, to determine whether gestational exposure to mAb involves a long-term risk for the immune system being developed in the newborn, or should this vary depending on the trimester for exposure. It is important to consider that the administration of vaccines with alive or attenuated virus or bacteria, an indication that is present in certain vaccine calendars for newborns, for example, with bacillus Calmette-Guérin (BCG), with which, infection can have a fatal outcome.¹⁰ For these reasons, it is recommendable that they be postponed until the sixth month of life.

Conflicts of Interest

LV: Abbvie, Roche Farma, Bristol-Myers Squibb, Pfizer, UCB, MSD and GSK; JGOB: nothing to declare; DHF: nothing to declare;

FJLL: Abbvie, Roche Farma, Bristol-Myers Squibb, Pfizer, UCB and MSD.

References

- Hazes JM, Coulie PG, Geenen V, Vermeire S, Carbonnel F, Louis E, et al. Rheumatoid arthritis and pregnancy: evolution of disease activity and pathophysiological considerations for drug use. *Rheumatology (Oxford)*. 2011;11:1955–68.
- Wylie AM. PART 71 – designation of Class A, Class B, Class C, Class D, and agency action. *Federal Register*. 2008;73:18–55.
- Hyrich KL, Symmons DP, Watson KD, Silman AJ. Pregnancy outcome in women who were exposed to anti-tumor necrosis factor agents: results from a national population register. *Arthritis Rheum*. 2006;54:2701–2.
- Katz JA, Antoni C, Keenan GF, Smith DE, Jacobs SJ, Lichtenstein GR. Outcome of pregnancy in women receiving infliximab for the treatment of Crohn's disease and rheumatoid arthritis. *Am J Gastroenterol*. 2004;99:2385–92.
- Simister NE. Placental transport of immunoglobulin G. *Vaccine*. 2003;21:3365–9.
- Palmeira P, Quinello C, Silveira-Lessa AL, Zago CA, Carneiro-Sampaio M. IgG placental transfer in healthy and pathological pregnancies. *Clin Dev Immunol*. 2012;2012, <http://dx.doi.org/10.1155/2012/985646>. Epub 2011 Oct 1.
- Chaparro M, Gisbert JP. Transplacental transfer of immunosuppressants and biologics used for the treatment of inflammatory bowel disease. *Curr Pharm Biotechnol*. 2011;12:765–73.
- Berthelsen BG, Fjeldsoe-Nielsen H, Nielsen CT, Hellmuth E. Etanercept concentrations in maternal serum, umbilical cord serum, breast milk and child serum during breastfeeding. *Rheumatology (Oxford)*. 2010;49:2225–7.
- Mahadevan U, Wolf DC, Dubinsky M, Cortot A, Lee SD, Siegel CA, et al. Placental transfer of anti-tumor necrosis factor agents in pregnant patients with inflammatory bowel disease. *Clin Gastroenterol Hepatol*. 2013;11:286–324.
- Cheent K, Nolan J, Shariq S, Kiho L, Pal A, Arnold J. Case report: fatal case of disseminated BCG infection in an infant born to a mother taking infliximab for Crohn's disease. *J Crohns Colitis*. 2010;4:603–5.

Lara Valor^{a,b,*} Juan Gabriel Ovalles-Bonilla^{a,b}
Diana Hernández-Flórez^{a,b} Francisco Javier López-Longo^{a,b}

^a Servicio de Reumatología, Hospital General Universitario Gregorio Marañón, Madrid, Spain

^b Instituto de Investigación Biomédica del Hospital Gregorio Marañón, Madrid, Spain

* Corresponding author.

E-mail address: lvalor.hgugm@salud.madrid.org (L. Valor).

Polymyositis in a Patient With Ulcerative Colitis[☆]



Polimiositis en un paciente con colitis ulcerosa

Dear Editor,

Ulcerative colitis (UC) is an inflammatory disease that affects the colorectal mucosa in a diffuse form, continuously and superficially.¹ Polymyositis (PM) belongs to the spectrum of idiopathic inflammatory myopathies, and is differentiated from dermatomyositis (DM) because of the absence of the characteristic skin rash.² Muscle involvement in the form of PM has rarely been described in UC. We report the case of a patient who was initially diagnosed as having UC, and developed PM over the course of his disease. We also review cases published to date. Our patient was a 46-year-old man, an ex-smoker, who presented with persistent bloody diarrhea with no other associated symptoms, and was diag-

nosed with UC. At the age of 58 years, he presented with an episode of pain and swollen hands, and was too weak to climb stairs. Laboratory tests detected increases in creatine kinase (CK) (1578 U/L) and lactate dehydrogenase (LDH) (506 U/L), although all other inflammatory parameters were normal. The rest of the biochemical study, including complete blood count, showed normal values. The immunological study demonstrated the presence of antinuclear antibodies, at a titer of 1/160, and negative tests for anti-extractable nuclear antigens (ENA), anti-DNA antibodies, antineutrophil cytoplasmic antibodies (ANCA), anti-centromere antibodies, anti-Scl-70 and antibodies specific for myositis (Jo-1, PL7, PL12, OJ, EJ, SRP, Pm-Scl, Mi2 and Ku). A muscle biopsy of quadriceps was performed (Fig. 1), and evidenced variability in the size of the muscle fibers, with some necrotic fibers, regenerative basophilic fibers and frequent mononuclear inflammatory cell infiltrates, mostly lymphocytic and located in the endomysium. The expression of the major histocompatibility complex class I antigens was positive in the muscle fibers, all of which was compatible with the diagnosis of PM. Treatment was begun with a tapering dose of prednisone starting at 20 mg/day, to be followed by methotrexate (maximum dose 25 mg/week), and normalization of the CK and LDH levels was achieved after 16 months of treatment.

[☆] Please cite this article as: González García A, Sifuentes-Giraldo WA, Diz Fariña S, Pian H. Polimiositis en un paciente con colitis ulcerosa. *Reumatol Clin*. 2016;12:360–362.