



CASE REPORT

Maxillary sinus hemangioma: usefulness of embolization according to classification[☆]



Hemangioma de seio maxilar: utilidade da embolização de acordo com a classificação

Hisashi Hasegawa^a, Hiroumi Matsuzaki^{a,*}, Tohru Furusaka^a, Takeshi Oshima^a, Shinobu Masuda^b, Toshiyuki Unno^c, Osamu Abe^c

^a Nihon University School of Medicine, Department of Otorhinolaryngology, Head and Neck Surgery, Tokyo, Japan

^b Nihon University School of Medicine, Department of Pathology, Tokyo, Japan

^c Nihon University School of Medicine, Department of Radiology, Tokyo, Japan

Received 19 June 2015; accepted 12 September 2015

Available online 17 December 2015

Introduction

Hemangioma in the nose and nasal sinuses is rare,¹ particularly in the maxillary sinus.² Differentiation of hemangioma from malignant tumors is important, because both may be accompanied by bone destruction. With regard to giant hemangioma, this type has a rich blood supply, and surgical treatment requires particular care due to the high risk of massive bleeding and obstructed field of view. Although maxillary sinus hemangioma has been sporadically reported, few reports have described cases of this type diagnosed according to the 1996 classification of the International Society for the Study of Vascular Anomalies (ISSVA) and treated with arterial embolization.

Here, we report three cases of massive sinonasal hemangioma that were resected after arterial embolization.

[☆] Please cite this article as: Hasegawa H, Matsuzaki H, Furusaka T, Oshima T, Masuda S, Unno T, et al. Maxillary sinus hemangioma: usefulness of embolization according to classification. Braz J Otorhinolaryngol. 2017;83:490–3.

* Corresponding author.

E-mail: matuzaki.hiroumi@nihon-u.ac.jp (H. Matsuzaki).

Peer Review under the responsibility of Associação Brasileira de Otorrinolaringologia e Cirurgia Cérvico-Facial.

Case report

An overview of the three cases is shown in [Table 1](#).

Case 1

A 43-year-old man presented with recurrent right nasal bleeding and nasal obstruction for six months. Mucosal swelling was observed from the maxillary sinus to the nasal septum in the right inferior and middle nasal meatuses. Sinus computed tomography (CT) revealed a soft tissue density shadow, with a contrast-enhanced interior in a scattered and gradually increasing pattern ([Fig. 1](#)). No calcification was observed. Gadolinium contrast magnetic resonance imaging (MRI) showed that the inside of the mass was markedly contrast-enhanced, suggesting a vascular tumor. Sphenopalatine arteriography showed tumor staining with a collection of thin, meandering arteries extending from the posterior superior alveolar artery and descending palatine artery. The tumor, which was contrast-enhanced during the arterial phase, was a slow-flow vascular lesion, from which the contrast medium was partially washed out in the late phase, and was diagnosed as venous malformation

<http://dx.doi.org/10.1016/j.bjorl.2015.09.002>

1808-8694/© 2015 Associação Brasileira de Otorrinolaringologia e Cirurgia Cérvico-Facial. Published by Elsevier Editora Ltda. This is an open access article under the CC BY-NC-ND license (<http://creativecommons.org/licenses/by-nc-nd/4.0/>).

Table 1 An overview of the three cases.

Case	1	2	3
Age gender	41 y.o. male	43 y.o. female	74 y.o. male
Preoperated biopsy	Hematoma	Necrotic polypoid	Nasal mucosa
Origin	Lateral wall	Upper wall	Unknown
Artery	Posterior superior alveolar descending palatine	Infraorbital dorsal nasal	Sphenopalatine deep temporal
Embolic device	Micro coil and gelatin sponge	Micro coil and gelatin sponge	Micro coil and gelatin sponge
Technique	ESS and Watsuji–Denker operation	ESS and Watsuji–Denker operation	ESS and Watsuji–Denker operation
ISSVA classification	Low flow venous malformation	Low flow venous malformation	Low flow venous malformation
Bleeding (g)	60	30	100
Diagnosis	Sinusoidal hemangioma	Cavernous hemangioma	Cavernous hemangioma

according to the ISSVA classification. Both arteries were embolized. Three days later, the patient underwent combined surgery with an endoscopic procedure and the Watsuji–Denker operation. Intraoperative blood loss was

30 mL. Sinusoidal hemangioma, a variant of cavernous hemangioma, was diagnosed by histopathology (Fig. 2A). In 24 months of follow-up conducted every three months, however, we have yet to recognize recurrence.

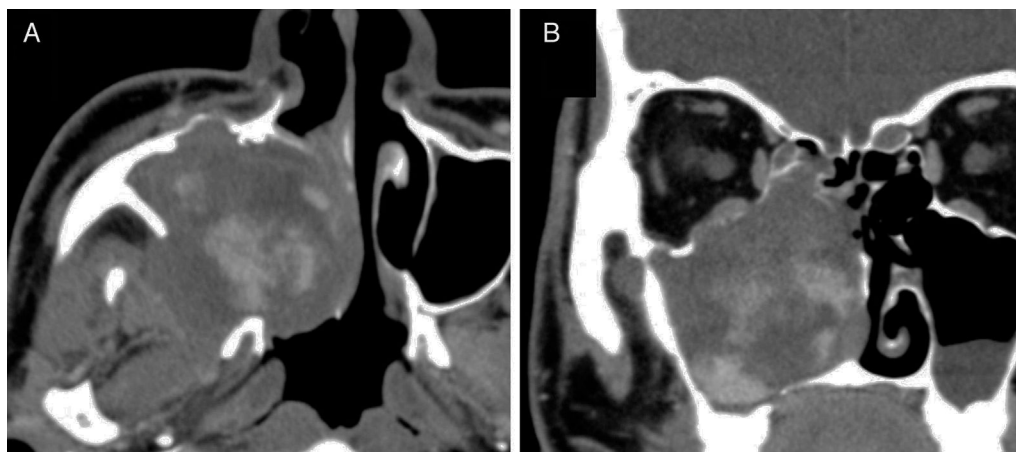

Figure 1 Enhanced CT in Case 1. Axial (A) and coronal (B) images. A strong, spreading, and gradually increasing contrast effect is seen during the arterial phase.

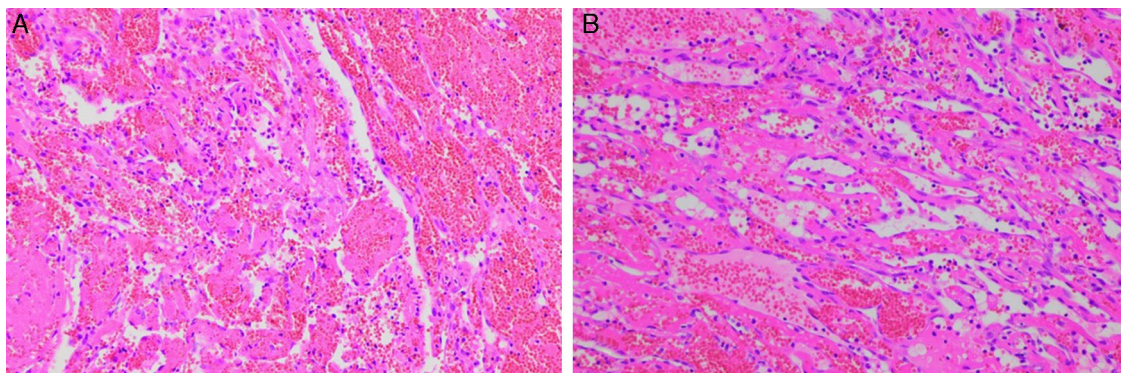


Figure 2 Pathological findings in Case 1 (A) and Case 3 (B). (A) The submitted material consisted of abundant coagulation with intermingling fibrous capsule and aggregation of vessel structures. The vessels are thin and delicate, with an anastomosing structure. (B) The submitted materials contained thick fibrous capsule and vessel structures. Morphological features of the vessel structure are consistent with cavernous hemangioma.

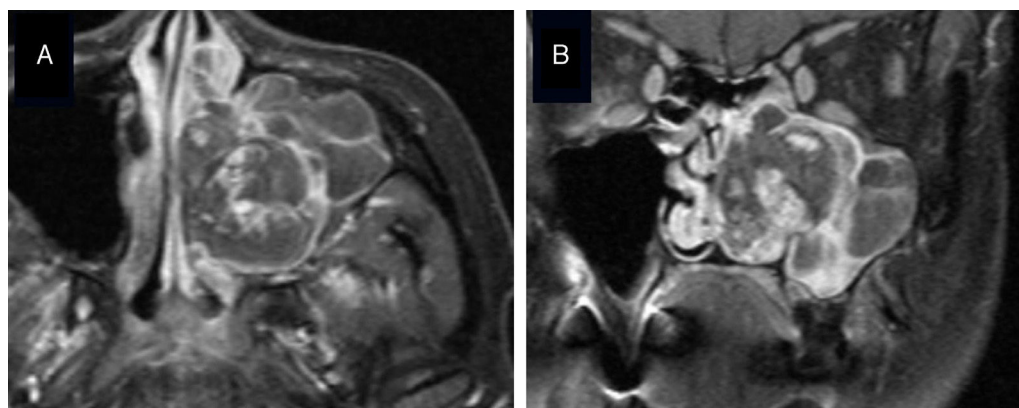


Figure 3 Gadolinium-enhanced MRI of Case 2. Axial (A) and coronal (B) images. A heterogeneously enhanced vascular tumor was suspected.

Case 2

A 41-year-old woman presented with recurrent left nasal bleeding and nasal obstruction for a month. Her left common nasal meatus was filled with edematous mucosa. Sinus CT revealed a soft tissue density shadow occupying the left maxillary sinus, ethmoid sinus, frontal sinus, and nasal cavity, with a bone defect on the medial wall of the left maxillary sinus. In addition, CT showed a soft tissue density shadow including blood retention that filled the left maxillary sinus. The medial wall of the maxillary sinus showed destruction and was increasingly contrast-enhanced. A 30 mm heterogeneously enhanced vascular tumor was suspected, based on gadolinium-enhanced MRI (Fig. 3). Facial arteriography showed tumor staining from the infraorbital artery on the upper wall of the left maxillary sinus, and the artery was embolized. In addition, the dorsal nasal artery was embolized. The tumor was a slow-flow vascular lesion, and venous malformation was diagnosed according to the ISSVA classification. Four days later, the patient underwent combined surgery with an endoscopic procedure and the Watsuji–Denker operation, and the entire lesion was extracted. Intraoperative blood loss was 30 mL. The postoperative pathological diagnosis was cavernous hemangioma. In 18 months of follow-up conducted every three months, however, we have yet to recognize recurrence.

Case 3

A 74-year-old man presented with right nasal bleeding and nasal obstruction. Two years before, the patient had experienced right nasal bleeding lasting a few hours. Myelodysplastic syndrome was diagnosed. An edematous polyp occupying the right common nasal meatus was observed. Sinus CT showed a soft tissue density shadow occupying the right maxillary sinus, ethmoid sinus, and frontal sinus to the left nasal cavity, with bone destruction on the medial wall of the right maxillary sinus. Contrast CT showed a lobulated tumorous lesion that was gradually contrast-enhanced from the maxillary sinus to the common nasal meatus, as well as microvascular development in the

tumor. Gadolinium-enhanced MRI showed a heterogeneously enhanced lesion, raising suspicion of a vascular tumor. Tissue biopsy showed only nasal mucosa. External carotid arteriography showed tumor staining in the area corresponding to the entire right maxillary sinus. Sphenopalatine arteriography showed that the infraorbital artery, descending palatine artery, and a number of small medial/lateral posterior nasal branches were involved as feeders. The main trunk of the sphenopalatine artery and branches of the deep temporal artery were embolized (Fig. 4). The tumor was a slow-flow vascular lesion diagnosed as venous malformation according to the ISSVA classification. Four days later, the patient underwent combined surgery with an endoscopic procedure and the Watsuji–Denker operation, and the entire lesion was extracted. Intraoperative blood loss was 100 mL. The postoperative pathological diagnosis was cavernous hemangioma (Fig. 2 B). In 18 months of follow-up conducted every three months, however, we have yet to recognize recurrence.

Discussion

In a report of 281 cases of hemangioma, 55 percent occurred on the face and extracranial head, and 5 percent occurred on the neck,³ with these lesions only rarely occurring in the nose or nasal sinuses.¹ Of those which do occur in the nose and nasal sinuses, about 80 percent occur on the nasal septum, in Kiesselbach's area in particular, and 15 percent on the lateral wall of the nasal cavity. Hemangioma occurring in the sinus cavity is even rarer. Cavernous hemangioma occurs far less frequently than capillary hemangioma, usually developing on turbinate bone and rarely on the bony tissue of the maxillary sinus wall.⁴

Sinusoidal hemangioma,^{5,6} diagnosed on histopathology in Case 1, is a markedly rare histological type (Fig. 4) which is relatively unknown among pathologists. Because only a few cases of sinusoidal hemangioma have been reported since the initial description by Calonje and Fletcher in 1991, a clear recognition of the clinicopathological characteristics of this type will avoid diagnostic pitfalls. Patient follow-up has revealed no tendency toward either local recurrence or metastasis⁵; however, Ciurea et al. reported three reoperations for recurrence.⁷ In our cases, the

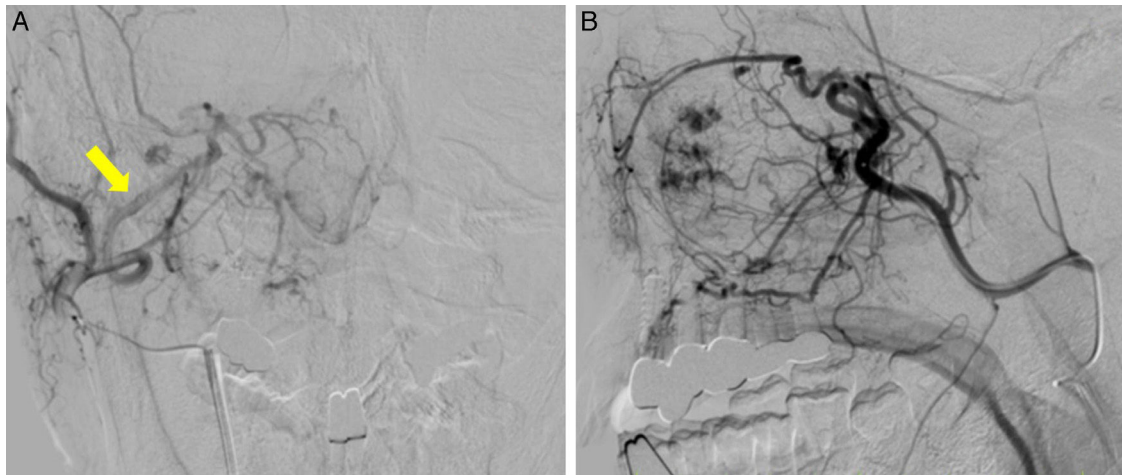


Figure 4 External carotid arteriography of Case 3. Frontal (A) and profile (B) views, showing tumor staining in the area corresponding to the entire right maxillary sinus. Sphenopalatine artery (arrow).

preoperative CT showed bone destruction. Given the rarity of sinusoidal hemangioma and the possibility that other vascular neoplastic lesions might also be present, a high risk of local recurrence and metastasis lesions with similar CT and MRI findings, such as hemangiopericytoma and hemangiosarcoma in these cases, cannot be denied.

Hemangioma is commonly diagnosed radiographically, according to the classification adopted at the 1996 ISSVA meeting. In the ISSVA classification, conventionally diagnosed hemangiomas are divided into vascular tumors and vascular malformations.⁸ Vascular malformations, conventionally classified as cavernous hemangiomas, do not regress spontaneously and sometimes require treatment when they gradually increase in size. They may be further subdivided into slow- and fast-flow lesions; fast-flow lesions can be treated with semipermanent and reliable embolization, such as via micro coils. Knowing the flow speed helps to determine the embolization method and is a useful reference for intravascular treatment.

We considered that our surgical method was effective on the basis of two criteria: the low rate of perioperative hemorrhage and the reported successful postoperative management. We were able to limit intraoperative bleeding to 60 mL, 30 mL, and 100 mL for Cases 1–3, respectively. Further, postoperative bleeding was sufficiently controlled by the placement of gauze tampons. In a previous report, a patient who did not undergo arterial embolization required two emergency room visits for the treatment of postoperative bleeding.⁹ Another study reported that massive sinonasal hemangioma was able to be resected endoscopically, albeit with effort, including preoperative arterial embolization and an increase in surgical access to the tumor via the construction of a control hole at the canine fossa.¹⁰ For our three patients, in contrast, we chose the combination of an endoscopic procedure and the Watsuji–Denker operation with preoperative arterial embolization, which facilitated our investigation and care of the postoperative lesion.

Conclusion

These three cases were diagnosed as slow-flow venous malformations, in accordance with the ISSVA classification. Angiography and arterial embolization both aided accurate diagnosis of the primary site and the control of bleeding. These very rare cases are amenable to relatively routine treatment following careful assessment and a planned approach.

Conflicts of interest

The authors declare no conflicts of interest.

References

1. Fu YS, Perzin KH. Non-epithelial tumors of the nasal cavity, paranasal sinuses, and nasopharynx: a clinicopathologic study. 3. Cartilaginous tumors (chondroma, chondrosarcoma). *Cancer*. 1974;34:453–63.
2. Batsakis JG, Rice DH. The pathology of head and neck tumors: vasoformative tumors, part 9A. *Head Neck Surg*. 1981;3:231–9.
3. Macomber W, Wang M. The hemangioma. *GP*. 1953;8:41–9.
4. Hellquist HB. Pathology of the nose and paranasal sinuses. Butterworths Editions; 1990.
5. Calonje E, Fletcher CD. Sinusoidal hemangioma. A distinctive benign vascular neoplasm within the group of cavernous hemangiomas. *Am J Surg Pathol*. 1991;15:1130–5.
6. Jammal H, Barakat F, Hadi U. Maxillary sinus cavernous hemangioma: a rare entity. *Acta Otolaryngol*. 2004;124:331–3.
7. Ciurea M, Ciurea R, Popa D, Parvanescu H, Marinescu D, Vrabete M. Sinusoidal hemangioma of the arm: case report and review of literature. *Rom J Morphol Embryol*. 2011;52:915–8.
8. Enjolras O, Wassef M, Chapot R. Color atlas of vascular tumors and vascular malformations. Cambridge University Press; 2007.
9. Vargas MC, Castillo M. Sinonasal cavernous haemangioma: a case report. *Dentomaxillofac Radiol*. 2012;41:340–1.
10. Song CE, Cho JH, Kim SY, Kim SW, Kim BG, Kang JM. Endoscopic resection of haemangiomas in the sinonasal cavity. *J Laryngol Otol*. 2009;123:868–72.