



Revista Brasileira de Hematologia e Hemoterapia Brazilian Journal of Hematology and Hemotherapy

www.rbhh.org



Images in Clinical Hematology

Bleomycin induced hyperpigmentation of skin

Kundan Mishra*, Aditya Jandial, Gaurav Prakash

Postgraduate Institute of Medical Education and Research (PGIMER), Chandigarh, India

ARTICLE INFO

Article history:

Received 29 June 2017

Accepted 21 August 2017

Available online xxx

A 64-year-old gentleman, a known case of Hodgkin's lymphoma on ABVD chemotherapy regimen (Doxorubicin, Bleomycin, Vinblastine, Dacarbazine), presented with blackish discoloration of skin for two weeks. He had received three cycles of chemotherapy over 12 weeks, including 54 mg/m² of intra-venous bleomycin. His B symptoms had completely disappeared after chemotherapy and there were no new symptoms. Clinical examination showed diffuse dark brown hyper-pigmentation of skin involving whole body with the changes being more conspicuous in areas exposed to the sun such as the limbs and face (Figure 1A–D). He was counseled about the likely effect of the drug on the skin. It was agreed to complete the planned six cycles of therapy. Two months after chemotherapy the pigmentation had markedly reduced (Figure 1E–H).

Bleomycin is known to cause lung and skin toxicity due to relative absence of hydrolase in skin tissue resulting in decreased metabolism and delayed clearance.¹ Pulmonary complications are common but skin changes are rare and include hyper-pigmentation, plaques, hyperkeratotic lesions, erythema multiforme, alopecia, stomatitis and nail changes.² The exact mechanism of skin changes caused by bleomycin is not known. The treatment involves management of underlying disorders or withdrawal of the offending drug.³

Conflicts of interest

The authors declare no conflicts of interest.

* Corresponding author at: Department of Internal Medicine, Postgraduate Institute of Medical Education and Research, Chandigarh 160012, India.

E-mail address: mishrak20@gmail.com (K. Mishra).

<https://doi.org/10.1016/j.bjhh.2017.08.005>

1516-8484/© 2017 Associação Brasileira de Hematologia, Hemoterapia e Terapia Celular. Published by Elsevier Editora Ltda. This is an open access article under the CC BY-NC-ND license (<http://creativecommons.org/licenses/by-nc-nd/4.0/>).

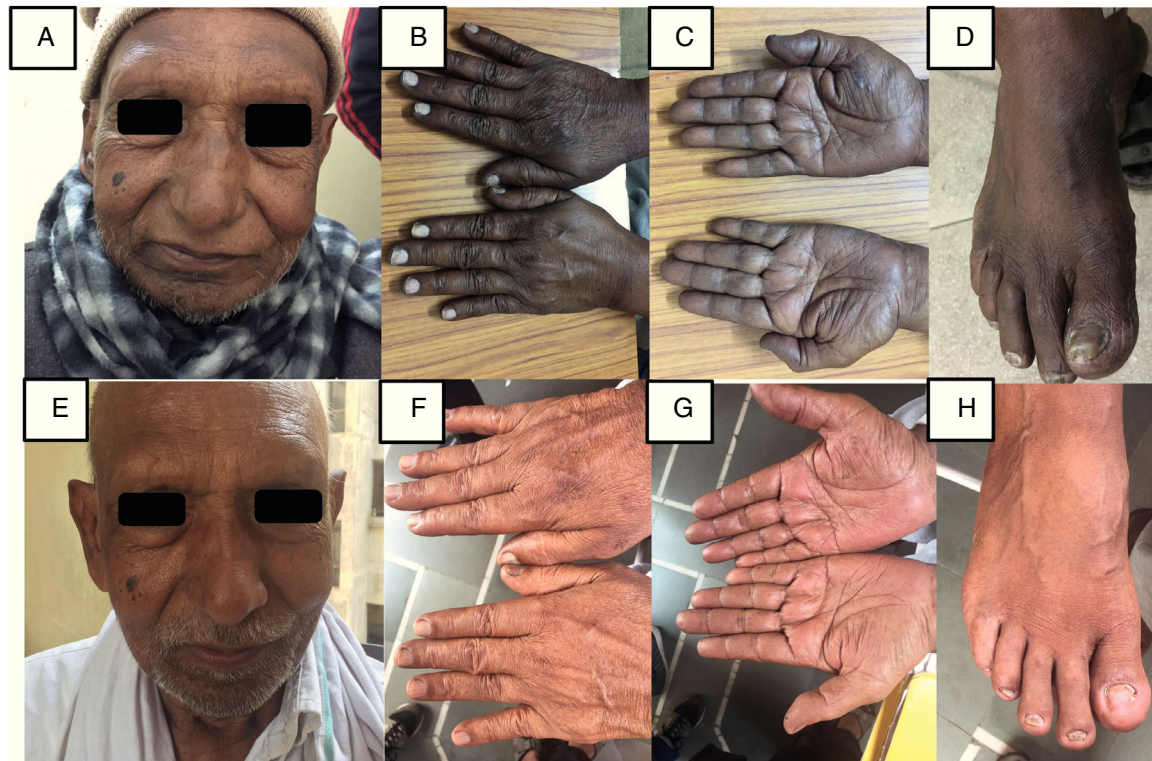


Figure 1 – A–D: Clinical photograph of the patient showing hyperpigmentation of skin involving face, hand and foot. E–H: Repeat clinical photograph of the patient showing near complete resolution of the hyperpigmentation of affected areas.

REFERENCES

1. Gupta LK, Tanwar RK, Khare AK, Jain SK. Bleomycin induced flagellate pigmentation. *Indian J Dermatol Venereol Leprol.* 2002;68(3):158–9.
2. Verma SP, Subbiah A, Kolar Vishwanath V, Dutta TK. Bleomycin-induced skin toxicity: is it always flagellate erythema? *BMJ Case Rep.* 2016;2016, pii:bcr2014204575.
3. Chen YB, Rahemtullah A, Breeden E, Hochberg EP. Bleomycin-induced flagellate erythema. *J Clin Oncol.* 2007;25(7):898–900.