

2. Criado PR, Avancini J, Santi CG, Medrado AT, Rodrigues CE, de Carvalho JF. Drug reaction with eosinophilia and systemic symptoms (DRESS): a complex interaction of drugs, viruses and the immune system. *Isr Med Assoc J.* 2012;14:577–82.
 3. Rodríguez R, Jover V, Orozco I, Domenech J. DRESS syndrome in a 19-year-old patient following the administration of first-line antituberculosis drugs. *J Investig Allergol Clin Immunol.* 2012;22:380–1.
 4. Palmero D, Castagnino J, Musella RM, Mosca C, González Montaner P, de Casado GC. Difficult clinical management of anti-tuberculosis DRESS syndrome. *Int J Tuberc Lung Dis.* 2013;17:76–8.
 5. Cacoub P, Musette P, Descamps V, Meyer O, Speirs C, Finzi L, et al. The DRESS syndrome: a literature review. *Am J Med.* 2011;124:588–97.
 6. Kardaun SH, Sidoroff A, Valeyrie-Allanore L, Halevy S, Davidovici BB, Mockenhaupt M, et al. Variability in the clinical pattern of cutaneous side-effects of drugs with systemic symptoms: does a DRESS syndrome really exist? *Br J Dermatol.* 2007;156:609–11.
 7. Shiohara T, Iijima M, Ikezawa Z, Hashimoto K. The diagnosis of a DRESS syndrome has been sufficiently established on the basis of typical clinical features and viral reactivations. *Br J Dermatol.* 2007;156:1083–4.
 8. Bourgeois GP, Cafardi JA, Groysman V, Hughey LC. A review of DRESS-associated myocarditis. *J Am Acad Dermatol.* 2012;66:e229–36.
 9. Howell C, Douglas K, Cho G, El-Ghariani K, Taylor P, Potok D, et al., British Society for Haematology Working Group. Guideline on the clinical use of apheresis procedures for the treatment of patients and collection of cellular therapy products. British Committee for Standards in Haematology. *Transfus Med.* 2015;25:57–78.
 10. Indicaciones urgentes de la aféresis terapéutica. Recomendaciones del Grupo Español de Aféresis. Sociedad Española de Hematología y Hemoterapia. Available at: <http://www.sehh.es/images/stories/recursos/2013/documentos/guias/Grupo-GEA-Aferesis-Urgente-1.pdf> [accessed 08.01.16].
- I. Martínez de Lagrán^{a,*}, P. Marcos^a, M. Batlle^b, E. Alonso^c, A. Plana^d, T. Tomasa^a
- ^a *Medicina Intensiva, Hospital Germans Trias i Pujol, Badalona, Barcelona, Spain*
^b *Hematología Clínica, Instituto Catalán Oncológico, Hospital Germans Trias i Pujol, Badalona, Barcelona, Spain*
^c *Banco de Sangre y Tejidos, Hospital Germans Trias i Pujol, Badalona, Barcelona, Spain*
^d *Dermatología, Hospital Germans Trias i Pujol, Badalona, Barcelona, Spain*
- *Corresponding author.
 E-mail address: itziaarmz@hotmail.com
 (I. Martínez de Lagrán).
 2173-5727/
 © 2017 Published by Elsevier España, S.L.U.

Cooperative sedation: An option for the management of agitation in moderate traumatic brain injury[☆]



Sedación cooperativa: opción para el manejo de la agitación en el traumatismo craneoencefálico moderado

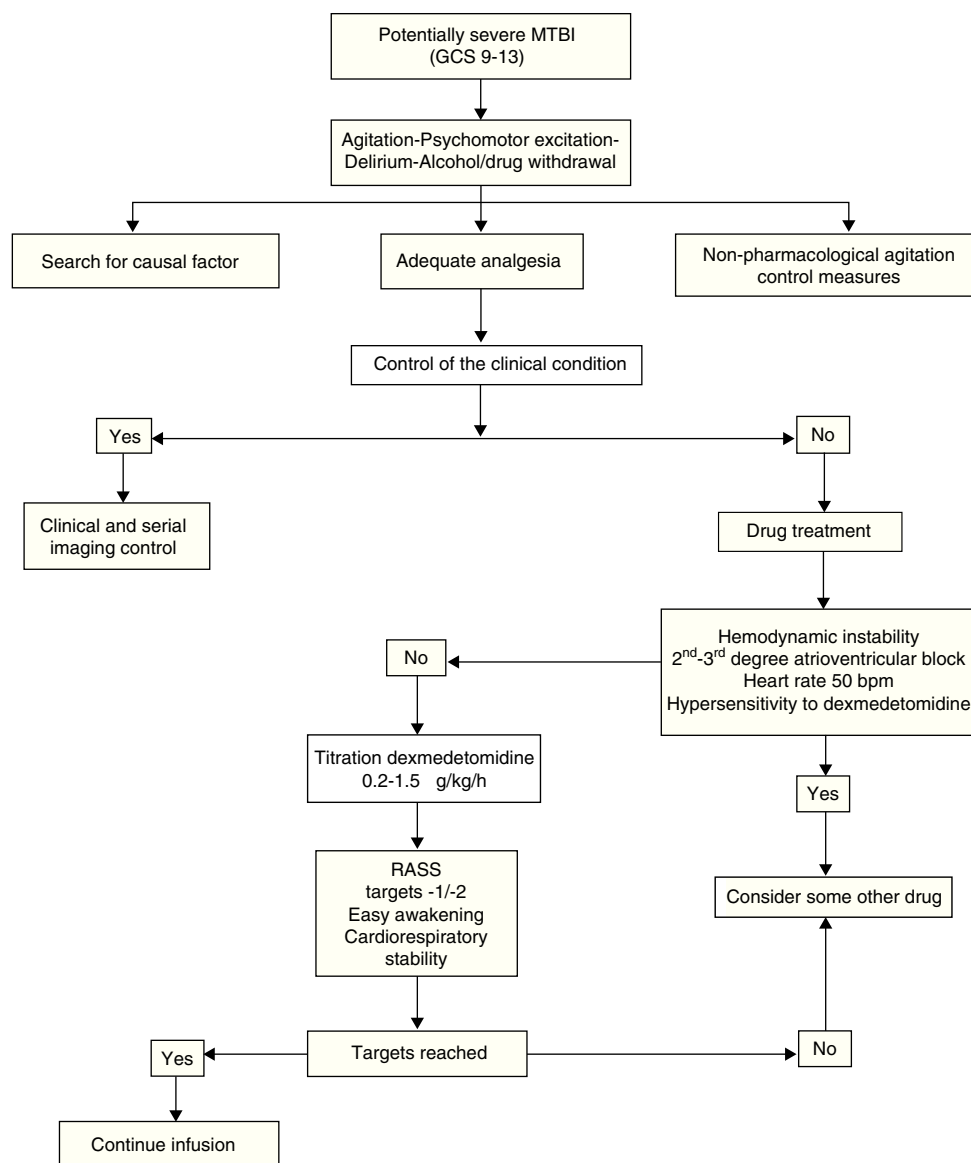
Dear Sir,

Moderate traumatic brain injury (MTBI) represents 20% of all brain injuries, and includes patients with a Glasgow coma score of 9–13. The associated mortality rate is 15%, and close to 50% of all patients suffer sequelae.^{1,2} Moderate traumatic brain injury is very heterogeneous in terms of its severity and clinical course.^{1,2} It affects young adults as well as elderly people, and one-third suffer intracranial injuries.^{1,2} In such cases pain and agitation are more common as a result of neurological damage, trauma in other body regions, and the consumption of alcohol or drugs of abuse.^{1,2} Agitation can moreover magnify brain damage through different mechanisms: increased metabolism and oxygen consumption, increased intracranial

pressure (ICP), lowered cerebral perfusion pressure (CPP), increased cardiovascular stress, and altered ventilation and oxygenation.³ Likewise, agitation complicates physical examination and diagnostic and therapeutic interventions.³ Adequate sedoanalgesia is essential in this respect, since both over- and under-sedation can contribute to secondary brain damage.⁴

In contrast to severe traumatic brain injury (STBI), where different clinical guides have established recommendations referred to sedoanalgesia,⁵ no such recommendations have been made in the case of MTBI. In this case, the recommendations established for STBI are commonly used. These recommendations usually comprise high-dose midazolam, remifentanyl and propofol – i.e., drugs that alter patient level of consciousness, complicate neurological exploration and lead to the indication of invasive mechanical ventilation.^{4,5} Dexmedetomidine (DEX), a sedating and analgesic agent that acts by stimulating the α_2 -adrenergic receptors within the locus coeruleus and spinal cord, makes it possible to administer what is known as “cooperative or conscious sedation” – defined as sedation in which the patient is calm and comfortable, and is able to respond adequately and immediately to tactile and verbal stimuli. This makes it possible to assess the neurological condition, with preservation of the defensive reflexes of the airway and spontaneous ventilation, and systemic hemodynamic stability.^{6,7} Dexmedetomidine can cause arterial hypotension and bradycardia secondary to sympathicolysis; these effects can be avoided by suppressing the loading dose, titrating the drug dosage, and maintaining strict normovolemia.^{6,7} The drug does not alter ICP or cerebral oxygenation, and exerts neuroprotective effects.^{6–10}

[☆] Please cite this article as: Godoy DA, Tolosa K, Lubillo-Montenegro S, Murillo-Cabezas F. Sedación cooperativa: opción para el manejo de la agitación en el traumatismo craneoencefálico moderado. *Med Intensiva.* 2017;41:193–196.



MTBI: moderate traumatic brain injury; GCS: Glasgow coma score; RASS: Richmond Agitation-Sedation Scale

Figure 1 Protocol for the use of dexmedetomidine.

We present the preliminary results of a cooperative sedoanalgesia protocol (Fig. 1) based on the use of DEX in patients with MTBI, no associated lesions, and with a pathological Marshall computed tomography classification score admitted to the Intensive Care Unit of San Juan Bautista Hospital (Catamarca, Argentina) during the period November 2014 – May 2015. Informed consent was obtained, together with approval from the local ethics committee.

The protocol is based on assessment of the causal factor (trauma, factor, urinary retention), basic measures (verbal management, bladder catheter, adequate environment), analgesia and pharmacological treatment of agitation. Pain control is monitored on the basis of clinical parameters, and starts with nonsteroidal antiinflammatory drugs (diclofenac, ketorolac) administered via the intravenous (i.v.) route. In the event of contraindication of these

drugs (gastritis, gastroduodenal ulcer, renal dysfunction, coagulation disorders), allergy, or active bleeding, or if the maximum doses have been reached without achieving pain control, we administer opioids. The drug of choice in this regard is intravenous morphine (2–4 mg/2–4 h). In the presence of hemodynamic instability, we use intermittent fentanyl at the recommended doses.⁴ Table 1 shows the main clinical data of the patients included in the study.

We do not administer a DEX loading dose, since it may cause arterial hypotension, which is deleterious in such patients.^{5–7} Dexmedetomidine exerts its effects within 15–30 min, with peak plasma concentrations being reached after one hour. For this reason, we initially combine other drugs to help control agitation.⁷ In our series, we used low-dose midazolam (2 mg i.v.) and chlorpromazine (25 mg via

Table 1 Demographic and clinical data of the study population.

Case	Age	Sex	Trauma mechanism	GCS	CT (Marshall)	COANA	Surgery	RASS B/A	MBP (mmHg) B/A	HR (bpm) B/A	RF (rpm) B/A	PaO ₂ /FiO ₂ B/A	ICP B/A	Maximum dose DEX (μg/kg/h)	Days DEX
1	34	F	Motorcycle	12	II	DF	No	3/−1	91/89	75/68	19/16	482/477	−	0.7 (1.8) ^a	3
2 ^b	19	M	Motorcycle	9	SOL NE	MOR	Yes	4/−2	90/84	87/71	18/16	432/428	−	0.3	5
3	80	M	Fall	11	II	DF	No	3/−2	129/104	107/72	22/16	417/416	−	0.5	5
4 ^b	56	M	Fall	9	SOL NE	MOR	Yes	4/−2	145/107	121/86	24/17	454/452	3/7	0.2	6
5	46	M	Motorcycle	10	II	MOR	No	3/−1	88/84	107/89	22/17	381/378	−	0.3	4
6	47	F	Fall	9	III	MOR	No	3/0	92/88	112/82	18/18	418/419	−	0.5	4
7 ^b	21	M	Motorcycle	9	III	MOR	Yes	4/0	87/84	92/83	26/20	401/404	9/11	0.4	3

B: before; COANA: coadjuvant analgesia; A: after 24 h of infusion; DEX: dexmedetomidine; DF: diclofenac; F: female; HR: heart rate; RF: respiratory frequency; GCS: Glasgow coma score; h: hour; SOL NE: space-occupying lesion not evacuated at time of evaluation; M: male; MOR: morphine; ICP: intracranial pressure; RASS: Richmond Agitation-Sedation Scale; MBP: mean blood pressure; CT: initial Marshall computed tomography classification score upon admission; μg: micrograms.

^a 1.8-fold maximum dose reached by mistake; breach in protocol. Transient arterial hypotension corrected by dose adjustment and infusion of 1000 ml saline.

^b Patients 2 and 4 underwent surgery due to the following reasons: patient 2 developed late epidural hematoma; patient 4 presented subdural hematoma initially managed on a conservative basis. In turn, patient 7 initially presented type III diffuse axonal injury (cistern obliteration), together with bifrontal contusions <25 ml, which subsequently required decompressive craniectomy due to refractory endocranial hypertension.

Table 2 Evolution of the scores on the Richmond Agitation-Sedation Scale (RASS).

Patient	Before DEX	Start	1 h	2 h	6 h	12 h	24 h	36 h	48 h	Without DEX
P1	3	3	1	0	0	0	−1	−2	−2	0
P2	4	4	1	1	0	0	−2	−2	−2	0
P3	3	3	1	0	0	−1	−2	−2	−2	0
P4	4	3	1	0	0	−1	−2	−2	−2	0
P5	4	4	0	0	0	0	−1	0	1	1
P6	3	3	1	1	1	−1	0	0	1	1
P7	3	3	1	0	0	−2	−2	−1	0	0

DEX: dexmedetomidine; h: hour.

the intramuscular route) in three and four patients, respectively.

Sixty minutes after starting DEX, all the patients showed a decrease of two or more points on the Richmond Agitation-Sedation Scale (RASS), while 71% of the patients reached adequate sedation and analgesia levels after 120 min (RASS 0). Under these conditions the patients were calm and cooperative, under spontaneous ventilation, and serial neurological assessment could be carried out even in the postoperative period. The time course of the RASS scores is shown in Table 2. In order to avoid confounding effects, we used no other sedating agents and did not introduce drug combinations during the infusion of DEX—particularly involving drugs capable of interfering with neurological evaluation and/or which might depress patient ventilation. Coadjuvant analgesics were used in all cases at conventional doses (Table 1). On the other hand, we observed no adverse hemodynamic or respiratory effects, except in one case where DEX was used at doses far beyond the recommended ranges (breach in protocol). This iatrogenic complication required dose correction and the infusion of saline solution, followed by rapid resolution (Table 1).

Vasopressor and inotropic drugs were not required. Likewise, in those cases where ICP was monitored after surgery, DEX did not alter the pressure values, and indeed may have contributed to pressure stabilization, since the ICP and CPP values remained within normal limits throughout the postoperative period. Dexmedetomidine was used for an average of 4.2 days. Once the patient clinical condition had stabilized, infusion of the drug was suspended on a gradual basis in all cases (20% of the dose every 6 h), with oral risperidone (1.5–6 mg/day) and clonazepam (1–4 mg/day) having been started 24 h before—coadjutant analgesia being maintained in all patients. We recorded no rebound effects with DEX (hypertension, tachycardia) in this protocol.

To the best of our knowledge, this is the first description of the use of DEX in patients with MTBI and a pathological Marshall computed tomography classification score. Although the small sample size is admittedly a limiting factor, the preliminary data obtained indicate that DEX is effective and safe, affording adequate analgesia (with coadjutant analgesics) and sedation during a period of 3–6 days, without problems on suspending the drug in a gradual and controlled manner. Therefore, although larger series are needed to confirm our results, we feel that DEX may be an option to be taken into account in the integral management of patients of this kind.

Conflicts of interest

The authors declare that they have no conflicts of interest.

References

1. Timmonds SD, Winestone JS. Moderate brain injury. In: Jallo J, Lotus C, editors. *Neurotrauma and critical care*. NY, USA: Thieme Medical Pub; 2009. p. 208–19 [chapter 10].
2. Andriessen TM, Horn J, Franschman G, van der Naalt J, Haitsma I, Jacobs B, et al. Epidemiology, severity classification, and outcome of moderate and severe traumatic brain injury: a prospective multicenter study. *J Neurotrauma*. 2011;28:2019–31.
3. Cohen IL, Gallagher TJ, Pohlman AS, Dasta JF, Abraham E, Papadokos PJ. Management of the agitated intensive care unit patient. *Crit Care Med*. 2002;30:597–123.
4. Celis-Rodríguez E, Birchenall C, de la Cal MA, Castorena Arellano G, Hernández A, Ceraso D, et al. Clinical practice guidelines for evidence-based management of sedoanalgesia in critically ill adult patients. *Med Intensiva*. 2013;37:519–74 [Article in English, Spanish].
5. Brain Trauma Foundation; American Association of Neurological Surgeons; Congress of Neurological Surgeons. Guidelines for the management of severe traumatic brain injury. *J Neurotrauma*. 2007;24 Suppl. 1:S1–106.
6. Goodwin H, Lewin JJ, Mirsky MA. Cooperative sedation: optimizing comfort while maximizing systemic and neurologic function. *Crit Care*. 2012;16:217.
7. Romera Ortega MA, Chamorro Jambrina C, Lipperheide Vallhonrat I, Fernández Simón I. Indicaciones de la dexmedetomidina en las tendencias actuales de sedoanalgesia en el paciente crítico. *Med Intensiva*. 2014;38:41–8.
8. Tang JE, Chen PL, Tang EJ, May TA, Stiver S. Dexmedetomidine controls agitation and facilitates reliable, serial neurological examinations in a non-intubated patients with traumatic brain injury. *Neurocrit Care*. 2011;15:175–81.
9. James ML, Olson DM, Graffagnino C. A pilot study of cerebral and haemodynamic physiological changes during sedation with dexmedetomidine or propofol in patients with acute brain injury. *Anaesth Intensive Care*. 2012;40:949–57.
10. Grof TM, Bledsoe KA. Evaluating the use of dexmedetomidine in neurocritical care patients. *Neurocrit Care*. 2010;12:356–61.

D.A. Godoy^{a,b,*}, K. Tolosa^b, S. Lubillo-Montenegro^c,
F. Murillo-Cabezas^d

^a *Unidad de Cuidados Neurointensivos, Sanatorio Pasteur, San Fernando del Valle de Catamarca, Catamarca, Argentina*

^b *Unidad de Terapia Intensiva, Hospital San Juan Bautista, Catamarca, Argentina*

^c *Unidad de Medicina Intensiva, Hospital Universitario Nuestra Señora de la Candelaria, Santa Cruz de Tenerife, Canary Islands, Spain*

^d *Unidad Clínica de Cuidados Críticos y Urgencias, Hospital Universitario Virgen del Rocío, Sevilla, Spain*

* Corresponding author.

E-mail address: dagodoytorres@yahoo.com.ar (D.A. Godoy).
2173-5727/

© 2017 Published by Elsevier España, S.L.U.