



IMAGES IN INTENSIVE MEDICINE

Intracoronary thrombus in a patient with recurrent vasospasm: Findings of optical coherence tomography[☆]



Trombo intracoronario en paciente con vasoespasmo recurrente: hallazgos de la tomografía de coherencia óptica

T. Bastante^a, A. García-Cabello^b, F. Alfonso^{a,*}

^a Servicio de Cardiología, Hospital Universitario de La Princesa, Madrid, Spain

^b Servicio de Cardiología, Hospital Universitario del Henares, Coslada, Madrid, Spain

A 45-year-old male with non-ST segment elevation coronary syndrome. Coronariography showed mild stenosis with smooth margins in the proximal anterior descending artery (Fig. 1A, arrow). Vasospasm testing proved clinically, electrically and angiographically positive (Fig. 1B: absence of flow—arrows). Optical coherence tomography (OCT) in turn revealed an underlying atheroma plaque of fibrolipidic characteristics, with no evidence of rupture (Fig. 1C). A curious thin laminar thrombus of platelet characteristics was identified, lining the endothelium (arrows). Vasospasm proved recurrent, leading to invasive re-evaluation; the OCT study one month later showed the laminar thrombus in the spastic zone to have become incorporated into the wall, forming a continuum with the arterial intimal layer (Fig. 1D; * guide artifact).

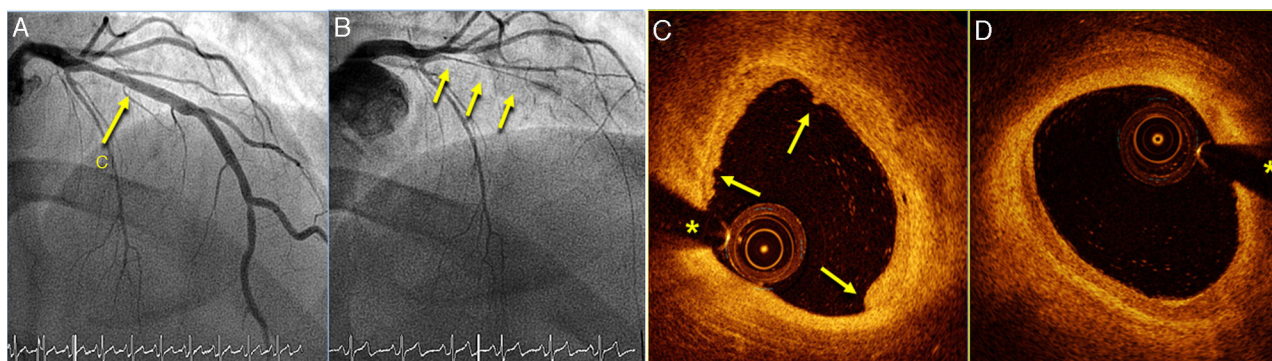


Figure 1

[☆] Please cite this article as: Bastante T, García-Cabello A, Alfonso F. Trombo intracoronario en paciente con vasoespasmo recurrente: hallazgos de la tomografía de coherencia óptica. Med Intensiva. 2017;41:508.

* Corresponding author.

E-mail address: falf@hotmail.com (F. Alfonso).