



IMAGE IN INTENSIVE MEDICINE

Retropneumoperitoneum due to fulminant spondylodiscitis[☆]



Retroneumoperitoneo por espondilodiscitis fulminante

I. López-García*, Y. Corcia-Palomo, M. Porrás-López

Servicio de Medicina Intensiva, Hospital Universitario Virgen del Rocío, Sevilla, Spain

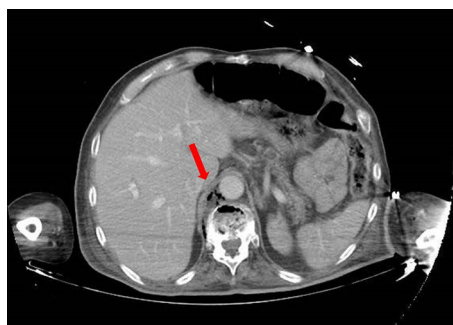


Fig. 1 Axial CT scan of the abdomen.

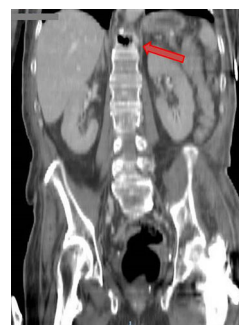

Fig. 2 Sagittal CT scan of the abdomen.

Sixty-two year-old-patient with clinical manifestations of asthenia, low-grade fever, and lower back pain of one month's duration who is hospitalized due to arterial hypotension and oligoanuria. The blood tests show severe metabolic acidosis and acute renal failure. The CT scan of the abdomen shows multiple air bubbles located in the upper retroperitoneum that seemed to come from the disc spaces at D10–D11 levels (Figs. 1 and 2). The patient's progression is fatal with the result of death. The retropneumoperitoneum is a rare radiologic finding with nonspecific, dormant clinical symptomatology. Spondylodiscitis is also a rare type of infection that affects the vertebral body and the intervertebral disc spaces. An early diagnosis is essential to be able to administer the right treatment and improve the prognosis of this disease.

Acknowledgements

Thanks are due to the Department of Intensive Care Medicine of Hospital Virgen del Rocío.

[☆] Please cite this article as: López-García I, Corcia-Palomo Y, Porrás-López M. Retroneumoperitoneo por espondilodiscitis fulminante. *Med Intensiva*. 2018;42:e2.

* Corresponding author.

E-mail address: isabellopez_80@hotmail.com (I. López-García).