

## CARDIOLOGY IMAGES

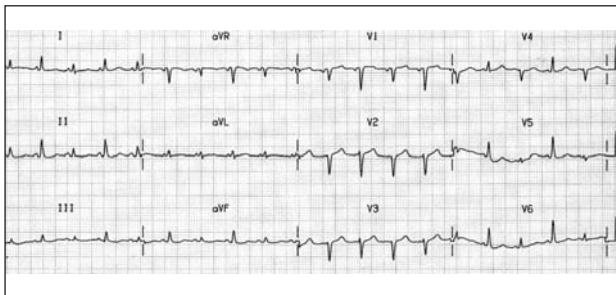


Fig. 1A.

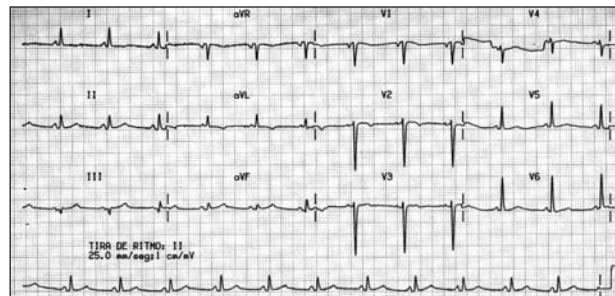


Fig. 1C.

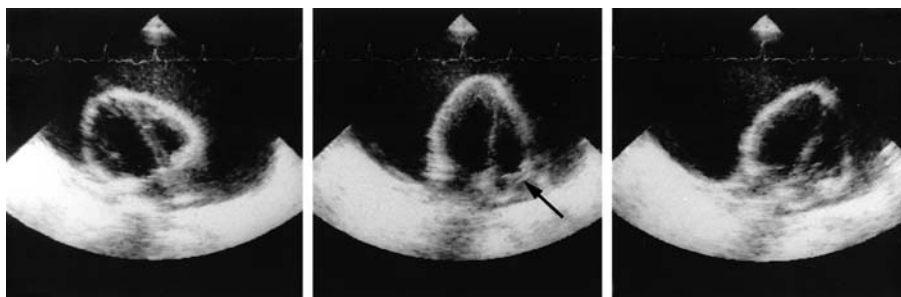


Fig. 1B.

## Swinging Heart

A 36-year-old man was studied because of a one-month history of dyspnea. Physical exam showed an irregular pulse, elevated blood pressure, hepatomegaly, and edema of the lower limbs. Chest radiography showed an irregular opaque nodule in the inferior left lobule and an enlarged cardiac silhouette. Electrocardiogram showed electrical alternance (Figure 1A). Electrical alternance may occur in cardiac blockage, constrictive pericarditis, tension pneumothorax, following myocardial infarct, and with severe myocardial dysfunction. Electrocardiography (Figure 1B) showed a large pericardial hemorrhage and collapse of the free wall of the right atrium (arrow), along with an oscillating heart. Consequently, the patient was diagnosed as having cardiac tamponade. Pericardiocentesis drainage was performed, and 1800 mL of pericardial fluid was drained. The abnormal movement of the heart in the pericardial sack resolved after the pericardial liquid

was drained, the electrocardiograph tracing normalized, the electrical alternance resolved, and the QRS amplitude increased (Figure 1C). Cytological examination yielded cells suggestive of adenocarcinoma. Bronchoscopic exam revealed a pulmonary adenocarcinoma. The patient died 3 months later. When pericardial hemorrhage is abundant, there may be excessive movement of the heart within the pericardial sack (Figure 1B); this phenomenon is called «oscillating heart.» Due to the excessive movement, the heart does not regain its original position before the next electric depolarization, so that the QRS complex axis varies, appearing as electrical alternation on electrocardiogram.

Francisco Marín Ortuño, Clara Oliver Navarrete  
and Juan Luján Martínez  
Servicio de Cardiología. Hospital General Universitario  
de Alicante. Alicante. Spain.