

Image in cardiology

## Hybrid Treatment for Acute Aortic Arch Dissection

### Tratamiento híbrido de la disección aguda del arco aórtico

Alfonso Cañas,\* Luis L. Almodóvar, and Emilio Monguió

Servicio de Cirugía Cardíaca, Complejo Hospitalario de Toledo, Toledo, Spain

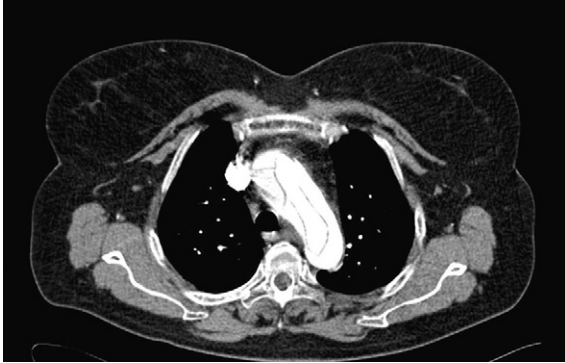

Figure 1.

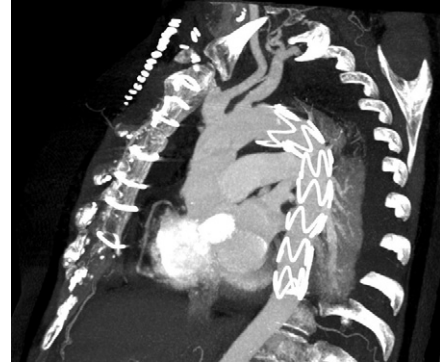


Figure 2.

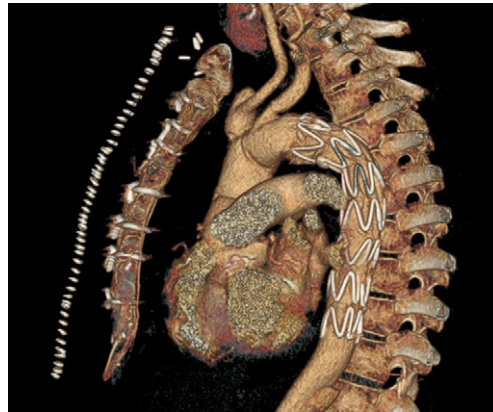


Figure 3.

Acute aortic syndrome affecting the aortic arch remains a treatment challenge, particularly in cases of acute dissection with an intimal tear in this location. Development of hybrid prostheses for complete treatment of the ascending aorta and aortic arch, combined with endovascular treatment of the descending aorta in a single procedure, has greatly increased the possibility of therapeutic success in this condition.

We present the case of a 66-year-old woman with interscapular pain of 5 hours' evolution associated with hypertension refractory to treatment. Chest computed tomography (CT) showed an aortic dissection affecting the ascending aorta distal to the sinus of Valsalva, the aortic arch, and the descending aorta to the proximal abdominal area (Fig. 1). Intraoperative transesophageal echocardiography disclosed severe aortic insufficiency with degenerative signs, preserved contractility, and a flap in the ascending aorta.

During surgery, a longitudinal intimal tear was seen in the aortic arch. With the patient under on-pump circulation and 25 °C hypothermia, systemic circulation was arrested and selective cerebral perfusion established. Aortic valve replacement with supracoronary implantation of a hybrid Evita Open Plus® prosthesis (Jotec GmbH; Hechingen, Germany) was then performed using an elephant trunk technique. The hybrid prosthesis consists of a Dacron graft to replace the ascending aorta and aortic arch with anastomoses of the supraaortic vessels, and a self-expanding nitinol endoprosthesis to treat the false lumen in the descending portion. The postoperative period was uneventful and the patient was discharged 13 days following the event. The final outcome is seen in the CT follow-up study (Figs. 2 and 3).

\* Corresponding author:  
E-mail address: [alfonso\\_c2@telefonica.net](mailto:alfonso_c2@telefonica.net) (A. Cañas).  
Available online 14 June 2011