

Image in cardiology

# Left Main Coronary Artery Atresia in an Asymptomatic Elderly Adult



## Agenesia de tronco común izquierdo en anciano asintomático

Belén Rubio Alonso,<sup>a,\*</sup> Alfonso Jurado Román,<sup>a</sup> and Sergio Alonso Charterina<sup>b</sup>

<sup>a</sup> Servicio de Cardiología, Hospital Universitario 12 de Octubre, Madrid, Spain

<sup>b</sup> Servicio de Radiodiagnóstico, Hospital Universitario 12 de Octubre, Madrid, Spain

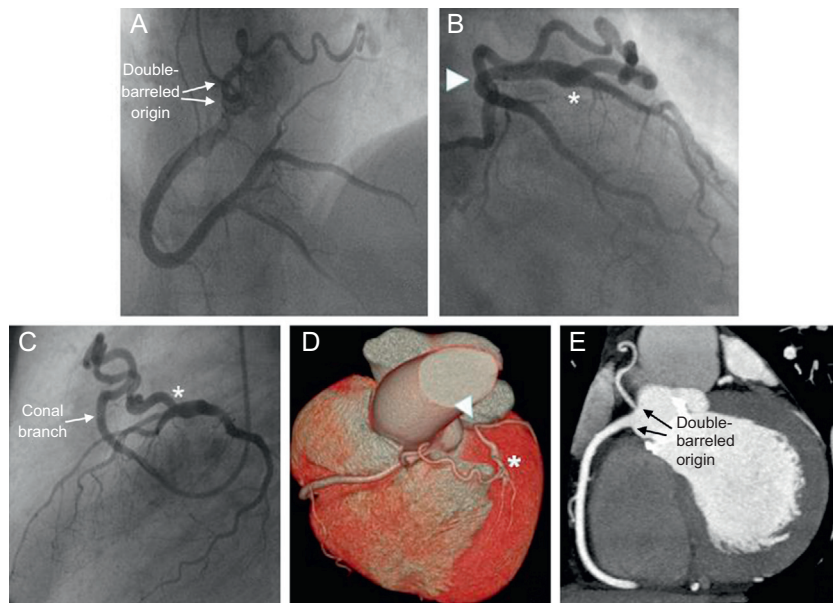


Figure.

Coronary artery anomalies are uncommon, with an incidence ranging between 0.2% and 1.4%. Among those least frequently observed is left main coronary artery atresia.

We report the case of a 72-year-old man, with asymptomatic severe aortic stenosis and moderate ventricular dysfunction. He underwent preoperative coronary angiography in which it was not possible to examine the left main coronary artery. Right coronary artery was dominant and the conal branch had an independent origin (Figure A and video 1 of the supplementary material). Blood was delivered to the left coronary tree by way of collateral circulation arising from the conal branch, which was anastomosed to the segment proximal to the anterior descending artery (Figures B and C, asterisks; video 2 of the supplementary material). The anterior descending and circumflex arteries were connected at their origin in the base of a blind pouch (Figure B, arrow head). There was no evidence of significant coronary artery calcification or stenosis.

High-resolution computed tomography was carried out to ensure complete evaluation of the anatomy. Three-dimensional reconstruction revealed left main coronary artery atresia and absence of the left coronary ostium in the left sinus of Valsalva (Figure D, arrow head), and confirmed the normal position of the anterior descending and circumflex arteries. The double-barreled origin of the right coronary artery and the conal branch and their anastomosis to the anterior descending artery were also clearly visualized (Figures E; Figure D, asterisk).

Left main coronary artery atresia was confirmed during valve replacement surgery and, 1 year later, the patient remained asymptomatic and with normal ventricular function.

### SUPPLEMENTARY MATERIAL



Supplementary material associated with this article can be found in the online version available at [doi:10.1016/j.rec.2014.06.023](https://doi.org/10.1016/j.rec.2014.06.023).

\* Corresponding author:  
E-mail address: [belenrubio84@hotmail.com](mailto:belenrubio84@hotmail.com) (B. Rubio Alonso).  
Available online 15 November 2014