

ECG Contest

Response to ECG, August 2015

Respuesta al ECG de agosto de 2015

Ramón Bover Freire

Servicio de Cardiología, Hospital Clínico San Carlos, Madrid, Spain



First degree atrioventricular block, second degree Mobitz I and subsequently with 2:1 conduction. Transoesophageal echocardiogram: prolapsed bicuspid aortic valve causing severe aortic regurgitation; pseudoaneurysm in the right coronary sinus (*), affecting the mitral-aortic intervalvular fibrosa. Subacute aortic endocarditis with secondary atrioventricular conduction disorder (Figure).

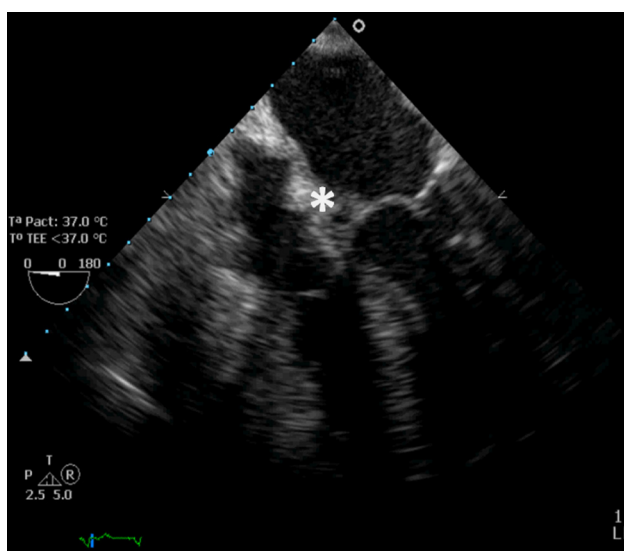


Figure.

SEE RELATED ARTICLE:

<http://dx.doi.org/10.1016/j.rec.2014.10.024>

E-mail address: ramonbover@secardiologia.es

<http://dx.doi.org/10.1016/j.rec.2014.10.025>

1885-5857/© 2014 Sociedad Española de Cardiología. Published by Elsevier España, S.L.U. All rights reserved.