

Image in cardiology

Optical Coherence Tomography During Vasospasm Testing



Tomografía de coherencia óptica durante test de vasospasmo

Teresa Bastante, Javier Cuesta, and Fernando Alfonso*

Servicio de Cardiología, Hospital Universitario de La Princesa, Madrid, Spain

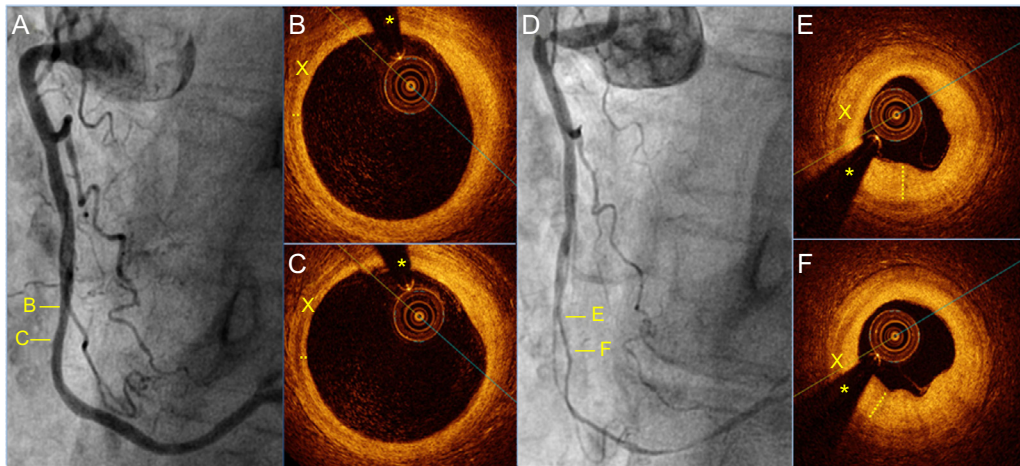


Figure.

A 72-year-old woman with stable angina was referred for coronary angiography. The patient had been treated for several years with low doses of aspirin and diltiazem for suspected coronary vasospasm, with poor symptom control in the last months. Coronary angiography did not detect significant lesions (Figure A). Evaluation of the right coronary artery by optical coherence tomography (OCT) ruled out significant artery wall disease (Figures B and C). A coronary vasospasm test with intracoronary ergonovine was strongly positive (Figure D). Optical coherence tomography during induced vasospasm revealed a significant increase in artery media thickness (X) relative to the baseline study (the asterisk marks a guide wire artifact). The intima layer appeared enlarged, “closed off”, and with the typical appearance of “humps” on its internal surface (discontinuous line) (Figures E and F). All of this is attributable to the extrinsic compression of the media layer causing severe stenosis of the vessel lumen. The decision was taken to increase the dose of diltiazem and to introduce treatment with nitrates, resulting in complete control of symptoms. In patients with coronary spasm, OCT can rule out the existence of underlying coronary atherosclerotic disease not detected by coronary angiography. This technique can sometimes visualize intraluminal thrombi and signs of plaque erosion. Optical coherence tomography during the ergonovine test can reveal the pathophysiological mechanisms of coronary vasospasm in exquisite detail; however, systematic and prospective studies will be needed to establish the true clinical usefulness of this technique for patients with this fascinating condition.

* Corresponding author:
E-mail address: falf@hotmail.com (F. Alfonso).
Available online 4 April 2016