

Image in cardiology

New Catheter, Wide Angle Imaging, 3D Intracardiac Echocardiography



Nuevo catéter, ángulo largo, de ecocardiografía intracardiaca 3D

José Ribeiro,* Pedro Braga, and Vasco Gama

Cardiology Department, Centro Hospitalar Gaia/Espinho, Vila Nova de Gaia, Portugal

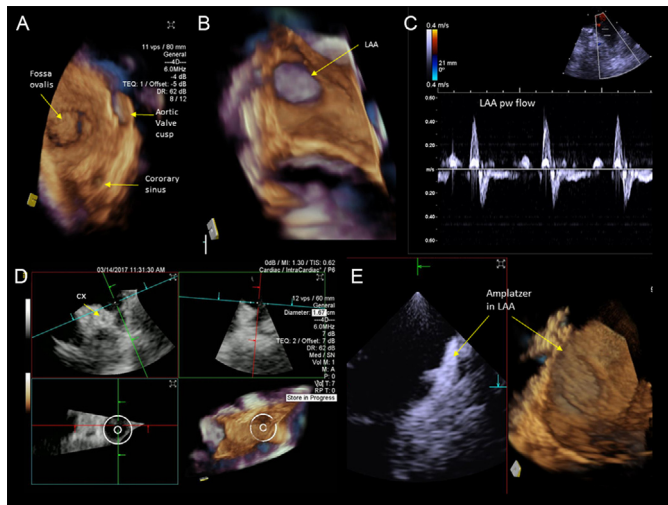


Figure 1.

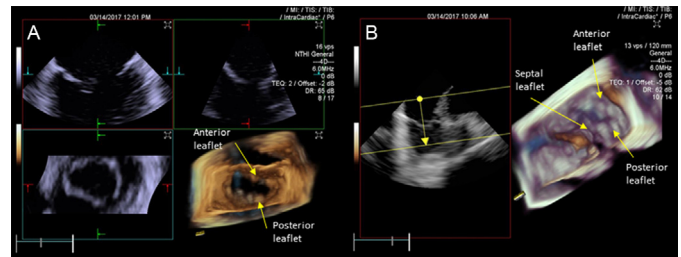


Figure 2.

During the last few years, the continuous development of intracardiac echocardiography (ICE) has allowed it to play an important role in guiding several interventions in structural heart disease, without the need for general anesthesia. However, the currently available 3-dimensional ICE catheter has a short elevation angle (maximum 90° x 24°), which limits its ability to view complete cardiac structures or devices.

We report the first European clinical use of volume ICE with an enlarged opening angle to guide left atrial appendage (LAA) closure. Interfaced with the ACUSON SC200 ultrasound system (Siemens Healthineers, Erlangen, Germany), the ACUSON AcuNav Volume ICE technology is a 12.5-Fr catheter, capable of obtaining a volume of 90° x 50° with a volume frame rate of 16 volumes per second.

Figure 1A was acquired with the catheter placed in the right atrium and shows the interatrial septum and its relationship with the aortic valve and coronary sinus and can be used to guide the interatrial puncture. Figure 1B was acquired from the left atrium and shows the entire LAA opening. Figure 1C depicts the LAA pulsed-wave flow recording. The LAA multiplanar reconstruction with the circle measurement tool can be viewed in Figure 1D, which also shows the circumflex artery (Cx). Figure 1E was acquired at the end of the procedure and shows the Amplatzer device correctly implanted in LAA in 2-dimensional and 3-dimensional views (Video 1 of the supplementary material). Finally, Figures 2A and 2B show all the leaflets of mitral and tricuspid valves (Video 2 of the supplementary material).

SUPPLEMENTARY MATERIAL



Supplementary material associated with this article can be found in the online version available at <http://dx.doi.org/10.1016/j.rec.2017.07.001>.

* Corresponding author:
E-mail address: cardiogaia@gmail.com (J. Ribeiro).
Available online 1 August 2017